

(11). Post-PE rebound of Ab titers to initial level was observed within 7 days. Though some redistribution of IgG (predominant in secondary immune responses) from extravascular spaces may partially account for recovery (12), Ab resynthesis was shown to occur following depletion by PE (1, 13). In this study, the presence of the spleen was clearly not required to develop post-PE resynthesis of immune anti-SRBC Ab. This lack of effect could be explained by PFC results, which showed similar concentrations of anti-SRBC Ab-producing cells in the spleen and in the mesenteric lymph nodes 14 days after SRBC immunization. However, the route for antigen administration is probably relevant for interpreting these data, since i.p. and not i.v. SRBC administration was performed, the latter leading to almost exclusive trapping of the particulate antigen by the spleen. Nevertheless, according to this model and despite its limitations, the apparently beneficial effect of Sx in ABO-incompatible kidney transplantation may not be simply explained by inhibition of post-PE Ab rebound, with the further restriction that immune (as in this model) or preformed (largely predominant in ABO-incompatible transplantation) Ab are probably produced by different lymphocyte populations, and Sx may not have similar consequences for post-PE Ab resynthesis in these instances. Whether a synergistic effect of Sx and immunosuppressive drugs is involved in these instances needs additional investigations.

In summary, post-PE resynthesis of immune anti-SRBC Ab was determined by hemagglutination assay in splenectomized and sham-operated rats. The data presented here did not show any significant effect of Sx on the kinetics of Ab rebound. Persistent Ab resynthesis occurring in splenectomized rats may be due to the intervention of Ab-producing cells in extrasplenic sites, as shown by PFC data.

RAYMOND REDING^{2,3}

DAVID J. G. WHITE²

HUGH FF. S. DAVIES²

DOMINIQUE LATINNE⁴

BÉATRICE DELEPAUT⁴

LUC LAMBOTTE⁵

ROY CALNE²

² University of Cambridge.

³ Address correspondence to: Dr. R. Reding, Dept. of Surgery, St-Luc University Clinics (UCL), 10 av. Hippocrate, B-1200 Brussels, Belgium.

⁴ Department of Immunohaematology, University of Louvain Medical School.

⁵ Department of Experimental Surgery, University of Louvain Medical School.

Department of Surgery
University of Cambridge
Addenbrooke's Hospital
Cambridge, England

Departments of Immunohaematology and Experimental
Surgery
University of Louvain Medical School
St-Luc University Clinics
Brussels, Belgium

REFERENCES

1. Taube DH, Welsh KI, Kennedy LA, et al. Successful removal and prevention of resynthesis of anti-HLA antibody. *Transplantation* 1984; 37: 254.
2. Alexandre GPJ, Squifflet JP, De Bruyere M, et al. Splenectomy as a prerequisite for successful human ABO-incompatible renal transplantation. *Transplant Proc* 1985; 17: 138.
3. Reding R, Squifflet JP, Pirson Y, et al. Living related and unrelated donor kidney transplantation: comparison between ABO-compatible and incompatible grafts. *Transplant Proc* 1987; 19: 1511.
4. Oldfield S, Jenkins S, Yeoman H, Gray D, MacLennan ICM. Class and subclass anti-pneumococcal antibody responses in splenectomized patients. *Clin Exp Immunol* 1985; 61: 664.
5. Schumaker NJ. Serum immunoglobulin and transferrin levels after childhood splenectomy. *Arch Dis Child* 1970; 45: 114.
6. Reding R, White DJG, Davies HffS, Calne RY. Plasma exchange in the unheparinized, unanaesthetized rat. *Laboratory Animals* 1988; 22: 293.
7. Jerne NK, Nordin AA. Plaque formation in agar by single antibody-producing cells. *Science* 1963; 140: 405.
8. Rowley DA. The effect of splenectomy on the formation of circulating antibody in the adult male albino rat. *J Pathol* 1950; 64: 289.
9. Church JA, Mahour GH, Lipsey AI. Antibody responses after splenectomy and splenic autoimplantation in rats. *J Surg Res* 1981; 31: 434.
10. Sullivan JL, Ochs HD, Schiffman G, et al. Immune response after splenectomy. *Lancet* 1978; 1: 178.
11. Reding R, White DJG, Davies HffS, Wright LJ, Calne RY. Rebound of xeno-antibodies after plasma exchange in the rat: quantitative and qualitative analysis. *Eur Surg Res* 1988; 20(Suppl 1): 73.
12. Waldmann TA, Stober W. Metabolism of immunoglobulins. *Prog Allergy* 1969; 13: 1.
13. Sturgill BC, Worzniak MJ. Stimulation of proliferation of 19S antibody-forming cells in the spleens of immunized guinea-pigs after exchange transfusion. *Nature* 1970; 228: 1304.

Received 14 June 1988.

Accepted 15 December 1988.

KAPOSI'S SARCOMA IN A TRANSPLANTED KIDNEY

Kaposi's sarcoma is a rare malignancy of mixed vascular and fibroblastic origin that occurs with increased frequency in transplant recipients and other immunosuppressed individuals (1-3). Although frequently involving many sites, this tumor is generally thought to be multicentric in origin and true metastases are not thought to occur (4). Prognosis in transplant recipients with this malignancy has been related to the presence or absence of visceral involvement (1, 5, 6) and current staging strategies are based on the presence or absence of tumor involvement as noted by computerized axial tomography of the chest and abdomen, together with findings on upper and lower

intestinal endoscopy (7). We describe a cadaveric renal transplant recipient who developed cutaneous manifestations of Kaposi's sarcoma less than a year following transplantation, in whom extensive evaluation failed to reveal evidence of visceral involvement despite the finding of diffuse sarcomatous infiltration of the transplanted kidney at nephrectomy. Cessation of immunosuppression resulted in complete tumor regression within three months. The finding of Kaposi's sarcoma in the transplanted kidney suggests a metastatic rather than multicentric origin, and failure to detect this involvement with computerized axial tomography suggests that caution be exer-

cised in accepting a negative staging evaluation in patients with Kaposi's sarcoma.

A 48-year-old white man with chronic membranoproliferative glomerulonephritis reached end-stage renal failure and was placed on chronic dialysis in June 1986, and begun on home hemodialysis in July 1986. After thorough evaluation he was found acceptable for transplantation, received three preparatory units of blood at monthly intervals, and was activated on the cadaveric recipient list in January 1987. His ABO blood type was A positive, Le (a neg, b neg) and HLA type was A 1, 2; B 27, 51; DR 4, 5. A CMV titer was strongly positive and HIV antibody was negative.

On March 21, 1987 he received an HIV-negative cadaveric renal transplant (Donor HLA:A 3, 24; B 7, 35; DR 1, 2) that functioned immediately. Immunosuppression was accomplished with rapidly tapering doses of steroids and azathioprine 150 mg/day. Cyclosporine (275 mg b.i.d.) was added on the 3rd hospital day. Except for persistence of hypertension, which was controlled with minoxidil 5.0 mg b.i.d. and furosemide 80 mg/day, his course was uneventful and he was discharged on April 3, 1987 with a serum creatinine of 2.0 mg/dl and a creatinine clearance of 69 ml/min.

On April 21, 1987 he was readmitted because of swelling in the region of the transplanted kidney, and a large lymphocele was surgically drained. He was discharged after 10 days and thereafter remained asymptomatic with stable renal function throughout the next six months. Immunosuppression during this period consisted of azathioprine 150 mg/day, prednisone 30 mg/day tapered to 17.5 mg/day, and cyclosporine (5–6 mg/kg/d.) In July 1987 tenormin 50–100 mg/day was added to his antihypertensive regimen.

In late November 1987 he noted the onset of painless smooth-surfaced nodular lesions on the left temple, left arm, and chest. In December the lesions developed a purplish hue and new lesions appeared in the left groin and on both ankles. An excisional biopsy of the chest lesion was performed in early January 1988. Microscopically (Fig. 1) the lesion was composed of closely set, thin-walled vascular channels lined by prominent

endothelial cells. Hemosiderin pigment was present focally throughout the specimen. A diagnosis of Kaposi's sarcoma was made. The patient had no systemic symptoms and significant physical findings were confined to the cutaneous lesions. An evaluation for visceral involvement including PA and lateral chest roentgenogram, CT scans of the chest and abdomen, esophagogastroduodenoscopy, and colonoscopy were negative, except for mild gastritis (biopsy-proved) and an adenomatous colonic polyp that was removed endoscopically. A repeat HIV titer was again negative. Renal ultrasound showed no change in size of the transplanted kidney. The patient's renal function since transplantation had remained stable except for a transient increase in serum creatinine to 2.3 mg/dl, which was thought to be secondary to cyclosporine and which returned to the previous baseline (1.9–2.0 mg/dl).

After the nature of the tumor and the therapeutic options were explained to the patient he elected to cease immunosuppressive therapy, undergo a transplant nephrectomy, and return to chronic hemodialysis. The transplanted kidney was removed on February 1, 1988. Grossly the kidney appeared normal, measured 12×5×5 cm in greatest dimensions and weighed 208 g. There were focal petechial hemorrhages on the cortical surface. Microscopically (Figs. 2–4) the kidney demonstrated nests of tumor cells scattered throughout the renal parenchyma that appeared similar to the original skin biopsy.

There was mild patchy interstitial fibrosis associated with distal convoluted tubules, consistent with mild chronic rejection. Areas of fairly well preserved parenchyma were interspersed with the sarcomatous infiltrate, and some areas appeared essentially normal. The patient was returned to chronic hemodialysis and discharged home on February 9, 1988. At a clinic visit 6 weeks later the residual skin lesions had decreased significantly in size and by three months had totally disappeared. It should be noted that the recipient of the other kidney from this donor is free of evidence of Kaposi's sarcoma and has stable renal function, with a creatinine of 1.6 mg%. Her HLA type was A 2, –; B 27, 44; DR 6, –. The CMV titer was 62.2 and the HIV titer was negative.

Kaposi's sarcoma is a relatively rare tumor that occurs with increased frequency in transplant recipients as well as other immunosuppressed individuals, either because of defective tumor surveillance or other effects of immunosuppression. Ka-

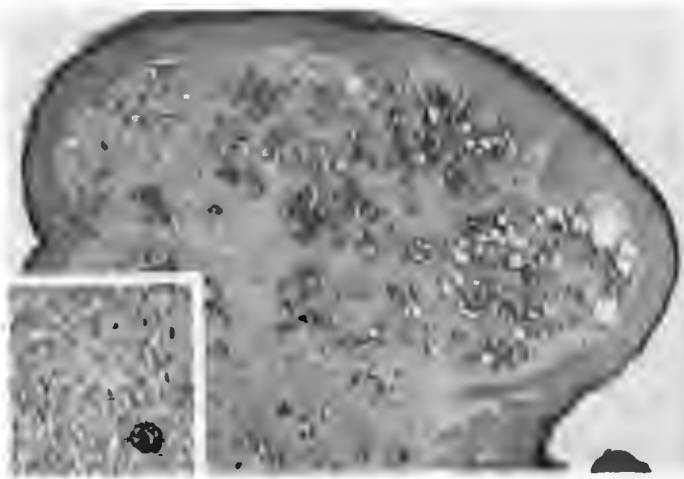


FIGURE 1. Section of skin lesion demonstrating intradermal proliferation of fusiform nuclei in abnormally shaped blood vessels and clustered in nests and bundles between abnormal vessels. Hemosiderin deposition is evident in the nests and adjacent stroma. (original magnification: $\times 40$). Inset demonstrates atypical spindling cells (original magnification: $\times 400$).

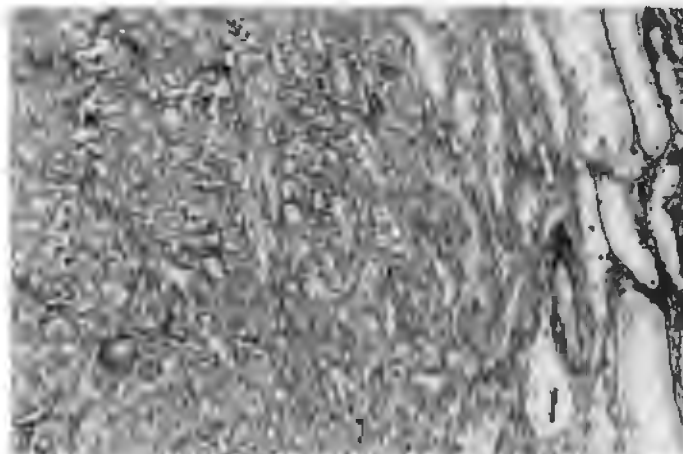


FIGURE 2. Section of transplanted kidney demonstrating perivascular Kaposi's sarcoma (PAS; original magnification: $\times 100$).

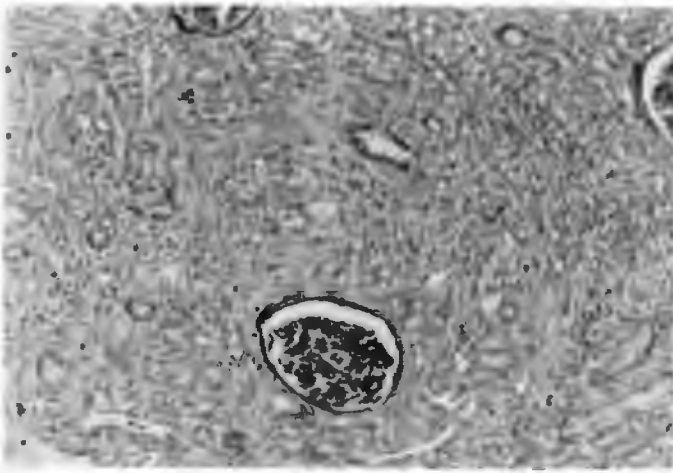


FIGURE 3. Section of transplanted kidney demonstrating periglomerular Kaposi's sarcoma. Trapped tubules, abnormal vessels, and spindle cells are apparent, (PAS; original magnification: $\times 100$).




FIGURE 4. Section of transplanted kidney demonstrating details of atypical spindle cells and blood vessels (PAS; original magnification: $\times 400$) Note similarity to cellular detail of skin lesion (Fig 1, inset).

posi's sarcoma has been reported to occur in approximately 0.4% of transplant recipients in Western countries (1) and up to 4–5.3% of transplant recipients of Jewish (5) and Arabic (6) descent, respectively. From 3 to 4% of all cancers occurring in transplant recipients in Western countries (1) and up to 89% in individuals of Arabic descent are Kaposi's sarcoma (6). This contrasts with an incidence of only .06% of cancers in the general population in Western countries (6). In addition to racial factors an increased frequency of Kaposi's sarcoma has been associated with HLA-2 and HLA DR-5 (9) and with evidence of previous CMV infection (10), although the latter has not been a consistent finding. Our patient was both HLA-2- and DR-5-positive, had high titers of CMV antibodies pre-transplant, and may have been at increased risk of developing this malignancy.

The outcome of Kaposi's sarcoma in the transplant patient is variable. Complete remissions have been reported in 24–28.5% of patients upon either decreasing or stopping immunosuppression alone or in combination with radiation or chemotherapy (1, 6); this appears to be related to the extent of the

disease and to the presence of visceral involvement. Thus Penn (1) reported that 8 of 9 patients with lesions confined to the skin underwent complete remission whereas, only 1 of 3 with visceral involvement improved. Similar observations were made by Qunibi et al. (6) who found that 7 of 9 patients with cutaneous involvement underwent complete remission, whereas only 1 of 5 with visceral involvement underwent remission. In transplant recipients Kaposi's is confined to the skin in 55–65% of individuals and has visceral involvement in 25–45% of cases.

Al-Khader et al. (7) have recently proposed a detailed staging system for posttransplant Kaposi's sarcoma: stage 1—localized skin lesions involving only one extremity; stage 2—widespread skin lesions involving more than one extremity; stage 3—generalized, involving viscera and/or lymph nodes and/or skin; and stage 4—any of the above in the presence of associated life-threatening infection or another neoplasm. Classification of visceral vs. cutaneous disease was based upon the findings at the time of upper and lower gastrointestinal endoscopy and computerized tomography of the chest and abdomen.

By Al-Khader's criteria our patient would have been classified as having stage 2 disease. Yet at time of nephrectomy he was found to have diffuse involvement in the transplanted kidney that would have placed him in stage 3 and would have portended a relatively poor prognosis. Despite this, his course has thus far been benign, and all apparent lesions have resolved following nephrectomy and cessation of immunosuppression. We believe this patient is unusual in this regard in that we are unable to find prior reports of Kaposi's sarcoma occurring in a transplanted organ, although polyclonal lymphoma and reticular cell sarcoma have been reported in the transplanted kidney (12–13).

Occurrence of Kaposi's sarcoma in the transplanted kidney might also suggest that this was metastatic rather than multicentric in origin, as is generally considered the case in this malignancy (4). If disseminated involvement in this malignancy represents multicentric origin one would not have expected it to occur simultaneously in the transplanted kidney unless that kidney was fortuitously derived from someone with a similar predisposition. The absence of predisposing HLA antigens in the donor, as well as the failure of the recipient of the other kidney to develop Kaposi's sarcoma, suggests that this was not the case.

Bovi et al. have recently isolated a growth factor from oncogene-transfected Kaposi's sarcoma cells that is similar to other fibroblast growth factors believed to be important in angiogenesis (14). This growth factor has recently been demonstrated to be released after infection with HIV and to cause endothelial and endothelial-like cells to proliferate (15). A similar mechanism has not been demonstrated in Kaposi's sarcoma in immunosuppressed transplant recipients, but either de novo production or increased sensitivity to such a growth factor would explain development of Kaposi's sarcoma in the transplanted kidney in our patient without having to evoke a metastatic mechanism. Determination of HLA antigenicity in the tumor might have confirmed whether the origin was from the host or the donor, but this was not performed.

In summary we believe that this individual was unique in that simultaneously with cutaneous manifestations he developed diffuse involvement of the transplanted kidney with Kaposi's sarcoma, which was not evident either from a change in renal function or an obvious increase in the size of the kidney

on either ultrasound or CT scan. Despite this, his course— with regression of all tumor on cessation of immunosuppression— has remained similar to that of individuals with localized cutaneous disease (1, 6). Moreover, the occurrence of the tumor in the transplanted kidney suggests that this may have been metastatic rather than multicentric in origin, and provides circumstantial evidence for the metastatic potential of Kaposi's sarcoma.

DONALD E. BUTKUS^{1,2}

KENT A. KIRCHNER

JAMES NEILL³

SESHADRI RAJU⁴

*The Departments of Medicine, Pathology, and Surgery
University of Mississippi Medical Center
Jackson, Mississippi 39216*

¹ Department of Medicine.

² Address correspondence to: Donald E. Butkus, M.D., Nephrology Division, University of Mississippi Medical Center, 2500 North State Street, Jackson, MS 39216.

³ Department of Pathology.

⁴ Department of Surgery.

REFERENCES

1. Penn I. Kaposi's sarcoma in organ transplant recipients. *Transplantation* 1979; 27: 8.
2. Safai B. Kaposi's sarcoma: a review of the classical and epidemic forms. *Ann NY Acad Sci* 1984; 437: 373.
3. Odajnyk C, Muggia FM. Treatment of Kaposi's sarcoma: overview and analysis by clinical setting. *J Clin Oncol* 1985; 3: 1277.
4. Schimpff SC. Acquired immunodeficiency syndromes. In: Mossa AR, Robson MC, Schimpff SC, eds. *Comprehensive textbook of oncology*. Baltimore: Williams and Wilkins, 1986: 605.

5. Harwood AR, Osoba D, Hofstader SL, et al. Kaposi's sarcoma in recipients of renal transplants. *Am J Med* 1979; 67: 759.
6. Qunibi W, Akhtar M, Shieth K, et al. Kaposi's sarcoma: the most common tumor after renal transplantation in Saudi Arabia. *Am J Med* 1988; 84: 225.
7. Al-Khader AA, Suleiman M, Al-Hasani M, Haleem A. Post-transplant Kaposi's sarcoma: staging as a guide to therapy and prognosis. *Nephron* 1988; 48: 165.
8. DiGiovanna JJ, Safai B. Kaposi's sarcoma: retrospective study of 90 cases with particular emphasis on familial occurrence, ethnic background and prevalence of other disease. *Am J Med* 1981; 71: 779.
9. Pollack MS, Safai B, Myskowski PL, Gold JWM, Padney J, Dupont B. Frequencies of HLA and Gm immunogenetic markers in Kaposi's sarcoma. *Tissue Antigens* 1983; 21: 1.
10. Kirchner H. Immunobiology of infection with human cytomegalovirus. *Adv Cancer Res* 1983; 40: 32.
11. Hood AF, Farmer ER, Weiss RA. Kaposi's sarcoma. *Johns Hopkins Med J* 1982; 151: 222.
12. Citterio F, Lauriola L, Nanni G, Magalini SC, Castagneto M. Polyclonal lymphoma confined to a renal allograft. *Transplant Proc* 1987; 19: 3732.
13. Brown RS, Schiff M, Mitchell MS. Reticulum cell sarcoma of host origin arising in a transplanted kidney. *Ann Intern Med* 1974; 80: 459.
14. Bovi PD, Curatola AM, Kern FG, Greco A, Ittmann M, Basilico C. An oncogene isolated by transfection of Kaposi's sarcoma DNA encodes a growth factor that is a member of the FGF family. *Cell* 1987; 50: 729.
15. Salahuddin AZ, Nakamura S, Biberfeld P, et al. Angiogenic properties of sarcoma-derived cells after long-term culture in vitro. *Science* 1988; 242: 430.

Received 22 September 1988.

Accepted 13 December 13, 1988.

ORTHOTOPIC LIVER TRANSPLANTATION IN A PATIENT WITH A GIANT CAVERNOUS HEMANGIOMA OF THE LIVER AND KASABACH-MERRITT SYNDROME

Hepatic hemangiomas are the second most common tumors of the liver (1), usually smaller than 4 cm in diameter. In autopsy series the incidence ranges from 0.6 to 7% (2). Hemangiomas are mostly solitary, 10% have multiple localizations (1), but are seldom symptomatic. Giant hemangiomas are rare (3, 4). Even the larger ones are often symptomless and require no treatment (5, 6). The bleeding risk seems to be low (3, 7, 8). If treatment is necessary, surgical resection may be an option. Radiation therapy (9) and corticosteroid treatment have been tried with success in some cases too (10). Large hemangiomas may induce abnormal coagulation parameters, thrombocytopenia, and a tendency to bleed (7, 11-15), suggesting disseminated intravascular coagulation. Kasabach and Merritt originally described this syndrome in association with a cutaneous hemangioma (16), but it can also be associated with hemangiomas in other areas. The coagulopathy in this so called Kasabach-Merritt syndrome is thought to be due to clotting and fibrinolysis within the hemangioma—i.e., a localized form of intravascular coagulation with secondary increased systemic fibrinolysis (8, 12). Treatment of this syndrome is often difficult. Recently a case report was published on aminocaproic acid (17) and on its combination with cryoprecipitate (11).

In 1983 a 27-year-old man was referred to our hospital for evaluation of hepatomegaly. Physical examination and liver

spleen scan showed that the liver extended to the edge of the iliac crest. Arterial angiography and laparoscopy showed a giant hemangioma of the liver. Liver function tests were normal. The hemangioma was very large and involved the left and right lobes of the liver. During follow-up the tumor size increased substantially. By December 1984 it was considered to be at risk for bleeding and rupturing due to its size.

From May 1984 a progressive coagulopathy developed, which was compatible with Kasabach-Merritt syndrome. The risk of bleeding considerably increased (Table 1). Lowered fibrinogen, plasminogen, and alpha-2 antiplasmin levels and a shortened euglobulinlysis time, together with strongly elevated levels of fibrin and fibrinogen split products, suggested fibrinogenolysis. Factor analysis showed normal plasma levels of factors II, V, VII, VII:C, IX, X, XI and XII. Screening for factor XIII deficiency was negative. The normal antithrombin 3 plasma level and the absence of microangiopathic hemolytic anemia made disseminated intravascular coagulation unlikely. The slightly decreased platelet count was attributed to pooling in the very large hemangioma.

Thus the coagulopathy was considered to be due to tumor-related increased fibrinogenolysis. Increased activity of tissue-type and urokinase-type plasminogen activator could not be demonstrated. It did not improve with tranexamic acid