

EXPERIMENTAL SMALL BOWEL TRANSPLANTATION UTILIZING CYCLOSPORINE¹

SESHADRI RAJU, RALPH H. DIDLAKE, MUKADDER CAYIRLI, M. DON TURNER, JAMES B. GROGAN,
AND JAMES ACHORD

Departments of Surgery and Medicine, University of Mississippi Medical Center, Jackson, Mississippi

Cyclosporine prolonged the survival of ectopic small bowel allografts in a canine model. A 9-fold increase in mean survival as compared with controls was obtained. Addition of prednisone to cyclosporine did not result in further graft prolongation, but improved the gross and histological appearance of the allograft. Monitoring the motility and histology of the allograft appears to be useful in predicting approaching rejection. Xylose absorption was not helpful in this regard. A new technique for measuring fat absorption in the transplant is described. Following allografting, fat absorption is resumed by 14 days posttransplantation.

Past work in small bowel transplantation has been relatively sparse, mainly because of the poor graft prolongation obtained with standard immunosuppressive agents (1). There is a substantial early mortality in dogs following small bowel transplantation. Even survivors receiving azathioprine (Imuran) and prednisone reject the grafts not long after transplantation, invariably with a fatal outcome (2). The dosage schedule of Imuran is critical and has a very narrow schedule range (3). It is generally conceded that denervation and division of lymphatics that are inevitable in small bowel transplantation affect the transplant function in their own way, in addition to the immunological parameters involved (4). Even after autotransplantation of the small bowel, animals suffer from diarrhea for several weeks as fat absorption is affected owing to division of lymphatics (1). Lymphatics eventually regenerate following autotransplantation (5), but the process takes several weeks. Autotransplanted animals do not regain their preoperative weight for several months.

Since there have been few chronically surviving animals with small bowel transplants (6), there is no description in the literature of the anatomic and physiologic features of long-term small bowel transplants. In short-term survivors (up to four weeks), such features as have been described (7, 8) are probably overlaid, to a considerable extent, by changes associated with the denervation and division of lymphatics. As a result, the literature is quite confusing and often contradictory regarding even basic aspects of small bowel transplantation. For example, conflicting reports have appeared regarding the presence or absence of small cell infiltration in transplanted bowel (7-9). There has been confusion as to whether graft-versus-host reaction occurs in transplantation of the entire small bowel and there has been no agreement as to whether dextrose absorption in the transplanted bowel is affected during rejection (9, 10). Other precise vital information on such features as fat absorption through the transplanted bowel; structural changes in the villi and mucosa—including neoplastic changes, if any; and

aspects of immunological rejection of the transplanted bowel is simply not available. Many of these basic features of small bowel transplantation were reexamined utilizing cyclosporine (11). These results are reported herein.

MATERIALS AND METHODS

Animals. Adult mongrel dogs (approximately 20 kg) of either sex (dewormed in the usual fashion) were utilized.

Cyclosporine. A large consignment of cyclosporine was requested and kindly donated by Sandoz, Ltd., for the purpose of this experiment. Cyclosporine was administered, 17 mg/kg/daily, as an oral suspension in corn oil. Transplanted animals received the drug orally from day 1.

Ectopic small bowel transplantation. Dogs were anesthetized with pentobarbital and placed on Byrd respirators. The recipient was prepared by exposing the external jugular vein and common carotid artery. In the donor animal, the distal jejunum and proximal ileum were identified through a midline abdominal incision. The distal portions of the superior mesenteric artery and vein supplying this segment were isolated, and the mesenteric fat, nerves, and lymphatics were dissected away. The remainder of the mesentery was then divided, ligating branch mesenteric vessels as necessary. The bowel itself was then divided. Following systemic hyparinization, the mesenteric artery and vein were clamped and divided. Approximately 35 cm of bowel was prepared in this manner. The graft was then placed in a basin of iced, heparinized, lactated Ringer's solution and the superior mesenteric artery was cannulated. The graft was then infused with cold (4 C), heparinized lactated Ringer's to obtain an intraluminal temperature of 10 C or less. This temperature appeared to provide a safe cold ischemic interval. The graft lumen was flushed with a cold solution of kanamycin (500 mg/L). The graft was then placed in the recipient's neck by creating a subcutaneous pouch. The superior mesenteric artery and vein were anastomosed to the external jugular vein and common carotid artery in an end-to-side fashion. Monofilament polypropylene (6-0 Prolene, Ethicon) suture has proved quite satisfactory. Warm ischemic time was less than three min, and cold ischemic interval ranged from 35 min to 65 min. Both ends of the bowel were brought through and sutured to the skin. It was found that creating two stomas was preferable to oversewing one end and leaving a single stoma. If the distal end of the bowel was oversewn, blowout of the stump invariably occurred. If the distal end was left as a stoma and the proximal end oversewn, prolapse frequently occurred. Attempts to anchor the bowel to prevent prolapse routinely resulted in fistula formation at the site of the anchor stitch. It was advantageous to orient the bowel in as straight a line as possible to facilitate biopsy with rigid instruments. The anterior 2/3 of the sternomastoid muscle was divided to prevent the donor mesentery from "straddling" the muscle and creating

¹ Presented at the 10th Annual Meeting of The American Society of Transplant Surgeons, May 1984, Chicago, IL.

tension at the vascular anastomosis. Following irrigation with kanamycin solution, the wound was closed in layers of chromic and nylon (Fig. 1). The recipient animals were given no special postoperative care and resumed a normal kennel diet on the first postoperative day. Cephalosporin antibiotics were given preoperatively and for 72 hr after surgery.

Segmental orthotopic transplants. Approximately 40 cm of donor midjejunum (measured in contracted state) was placed in the abdominal cavity of the recipients in a Roux-en-Y configuration. Graft vessels were anastomosed to the superior mesenteric artery and vein respectively. Host jejunum was not resected, allowing for cyclosporine absorption through the host small bowel (Fig. 1). This configuration created two graft host anastomoses while allowing direct access to the grafted segment for biopsy and motility studies.

D-xylose absorption. D-xylose absorption was determined using 1 g d-xylose in 20 ml of normal saline (12). Six consecutive blood samples were withdrawn at 30-min intervals for determination of d-xylose levels.

Fat absorption. A method utilizing oleic acid labeled with tritium has been successfully employed in our laboratory. Tritium-labeled oleic acid in toluene solution was stored under nitrogen at -70°C . The labeled acid was warmed to room temperature, evaporated to dryness, and dissolved in absolute ethanol. The oleic acid was then converted to its sodium salt by the addition of sodium hydroxide. Following dilution with saline, a stable solution was formed by the addition of bile salts (sodium cholate and sodium deoxycholate). Then 25 μCi of this solution in a volume of 1 ml was instilled into the graft lumen and the radioactivity of the animal's serum was counted at hourly intervals for 4 hr by standard liquid scintillation techniques. Uptake was linear over the initial 4 hr and the slopes of successive determinations could be compared to evaluate lipid uptake.

Jejunal biopsy. Specimens were obtained by direct vision through a rigid endoscope from ectopic transplants and from Roux-en-Y orthotopic transplants. Biopsies were taken alternate days during the first week and at weekly intervals thereafter. These were processed for light microscopy with hematoxylin and eosin in standard fashion.

Motility of canine cervical loops. Motility was measured daily

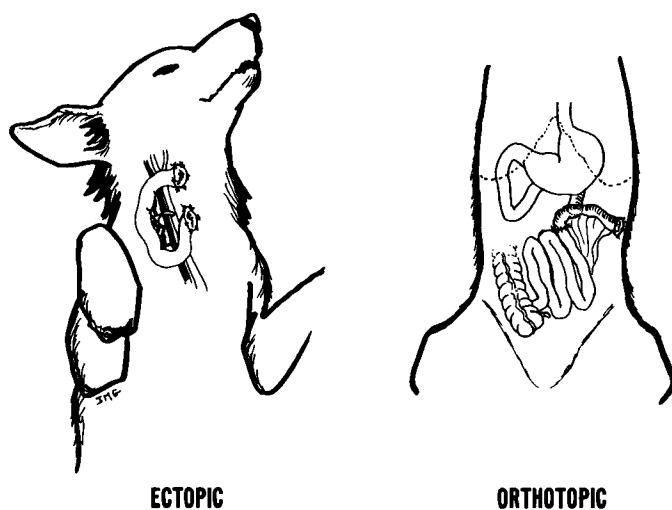


FIGURE 1. Technique of ectopic and orthotopic segmental small bowel transplantation.

by inserting a balloon catheter into the bowel lumen and recording the strength and frequency of contractions. The recording device was fashioned of a standard 12 French foley catheter connected to a Statham venous pressure transducer through a stopcock. The transducer was connected to a Statham pressure recorder interfaced to a chart recorder. All recordings were made with the animal in a fasting state.

Experimental groups. Cervical grafts were placed in forty animals, randomized into five groups of eight dogs each. Group 1 received cervical loop autografts. Group 2 received allografts without immunosuppression. Group 3 consisted of allografts treated with azathioprine 2 mg/kg/day. Group 4 had allografts and received cyclosporine 17 mg/kg/day in corn oil. Group 5 received cyclosporine as in group 4 and also received prednisone 2 mg/kg/day orally.

In addition, three dogs had segmental orthotopic allografts. Rejection, when it occurred, was allowed to proceed to its endpoint without modification by altering the drug protocol. The diagnosis of end-stage rejection was based upon the absence of motility for a 24-hr period associated with any one of the following: intense cellular infiltrate in the lamina propria; hemorrhagic mucus output; or obvious sloughing of the graft mucosa.

RESULTS

The surgical technique was initially perfected in a group of five animals that had been excluded from the present study. Technical failures from vascular thrombosis and graft loss was usually apparent within 36 hr of the procedure. Three such failures occurred in the present study, and these animals have been excluded from the analyses presented in this report. In several animals in the present study, graft thrombosis occurred much later, usually around the 5th or 6th day in group 2 and 3 animals and even later in group 4 and 5 animals. Even though technical problems with the vascular anastomosis could not be absolutely excluded as a basis for this late thrombosis, for the purposes of this study, these late events have been interpreted as a distinct form of vascular rejection.

All autografts survived and functioned indefinitely (Table 1). Untreated allografts had a mean survival of six days. Administration of azathioprine failed to prolong allograft survival significantly. In contrast, there was nearly a 10-fold increase in graft survival with cyclosporine administration (Table 1). Addition of steroids to cyclosporine appeared to improve graft histology (Table 1) but there was no further increase in graft survival.

Graft rejection. Loss of motility, loss of or marked change in mucus output, and swelling of the graft were consistent findings during the rejection process. However, none of these markers was present earlier than 48 hr prior to the diagnosis of rejection.

TABLE 1. Mean survival of ectopic small bowel transplants

Groups	Days of survival (\pm SD)	Cause of graft death	
		Rejection	Thrombosis
Autografts	>300	0/8	0/8
Untreated	6.6 \pm 1.5	7/8	1/8
Azathioprine	11.1 \pm 3.5	5/8	3/8
Cyclosporine	56.0 \pm 18.6 ^a	6/8	2/8
Cyclosporine + prednisone	60.0 \pm 11.2 ^a	6/8	2/8

^a $P < 0.05$ compared with untreated controls.

Only slightly more predictive was decreasing contractile frequency, which was occasionally noted 72 hr prior to the appearance of clinical rejection. Animals receiving cyclosporine appeared to exhibit two types of rejection: a chronic cellular type with a round cell infiltrate; and, less commonly, a predominantly vascular type leading to arterial thrombosis and graft death with sparse cellular infiltrate. The latter type often occurred late, after the graft had been in place for a month or more in group 4 and group 5 animals, ruling out technical factors in arterial thrombosis.

Motility studies. Transplanted bowel segments regained spontaneous peristalsis immediately upon revascularization. During the first few minutes peristalsis was hyperactive. The ultimate rate of contraction for each transplanted segment appeared intrinsic and remained constant for the life of the graft. The strength of contraction correlated moderately well with rejection. A stable graft exhibited a fairly predictable pattern of activity. A long forceful contraction was followed by a cycle of activity and a subsequent aperistaltic interval (Fig. 2). The rate of contraction from the first postoperative day to rejection was quite constant and only slightly less so was the peak contractile force of any given cycle.

Reduced contractile frequency could be used as a useful lead indicator of approaching rejection in cyclosporine-treated animals (groups 4 and 5), but not in others (Table 2).

Graft histology. After the initial inflammatory reaction had subsided (usually by day 7 posttransplant), autografts and long-

surviving allografts exhibited normal-looking mucosa and underlying musculature. However, in surviving allografts, a varying cellular infiltrate, more often sparse than dense, was present. Approaching rejection was heralded by villous blunting followed by dense cellular infiltration of the lamina propria in the subsequent 48 hr.

In some allografts in the untreated and azathioprine groups, mucosal loss occurred so rapidly as to be complete within 48 hr after initial detection of villous blunting. Examination of the specimen after the loss of mucosa invariably revealed an underlying muscular infiltrate.

The cellular infiltrate was the "small round cell" type ubiquitous in rejection histology. No attempt was made to further characterize these cells. In general, azathioprine-treated allografts appeared to have a denser cellular infiltrate (Fig. 3A) as compared with the cyclosporine-treated group. In some of the latter, rejection appeared to be predominantly vascular (Fig. 3B) with thrombosis of microcirculation but cellular infiltrates and edema were absent altogether or were not prominent features.

Addition of prednisone to cyclosporine appeared to yield a generally better histological appearance of the allograft, but did not influence graft survival. The villi were normal in length and thickness; cellular infiltrate and edema were slight or entirely absent. Some of these allografts were indistinguishable from autografts. In none of the autopsy specimens harvested for full-thickness histology could muscular hypertrophy as described by Craddock (13) be identified.

Oleic acid absorption. Oleic acid uptake was determined for all grafts surviving seven or more days. The initial study was performed on day 7 and weekly thereafter. Of 16 allografts surviving 10 days or longer, fifteen (91%) yielded positive oleic acid uptake through the transplant at a mean time of 13 days. All eight autografts showed positive uptake by day 14. No allografts or autografts surviving <10 days demonstrated an ability to absorb this fatty acid. Only one allograft of those tested, which had survived longer than 10 days, failed to absorb the labeled acid (Fig. 4).

Xylose absorption. Xylose absorption was determined for each graft on the third posttransplant day and weekly thereafter. Of 24 allografts, 20 demonstrated the ability to absorb this carbohydrate within the first postoperative week. Several determinations of xylose uptake revealed that grafts surviving 14 days or longer showed uptake curves similar to autografted controls (Fig. 5). There was no significant difference between the intact and rejecting allografts at any point of determination. At 2 hr and 3 hr, a significant difference ($P < 0.05$) was noted between autografts and rejecting allografts only.

The presence of a significant rejection reaction had little effect upon peak serum xylose levels, although the curve shape was somewhat different in the animals tested at the time of rejection (Fig. 5). This suggests non-energy-dependent or passive transfer of xylose across the damaged intestinal membrane in the presence of acute rejection. Contrary to suggestions in the literature, the xylose absorption test is not a sensitive indicator of acute rejection.

Segmental orthotopic grafts. Three animals were studied with segmental orthotopic grafts as described above. Even though the sample size was small, several relevant observations were made in this group: (1) motility studies with a balloon-tipped catheter are applicable to this model as well as to the cervical ectopic grafts; (2) rigid instrument biopsy can be performed

INTRALUMINAL PRESSURE - TRANSPLANT

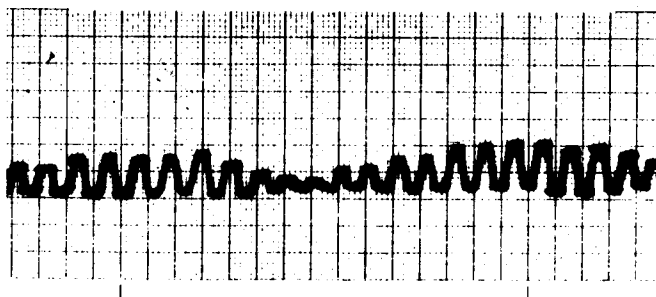


FIGURE 2. Motility tracing of an ectopic transplant.

TABLE 2. Relationship between motility changes and mean graft survival in ectopic small bowel transplants

Groups	Mean day of occurrence		Mean graft survival (day [mean \pm SD]) ^c
	Loss of motility ^a	Reduced contractile frequency ^b	
Autografts	None	None	>300
Untreated	5.2	4.0	5, 6, 6, 6, 6, 7, 7, 9 (6.6 \pm 1.3)
Azathioprine	10.0	9.1	7, 9, 10, 11, 11, 11, 14, 17 (11.2 \pm 3.5)
Cyclosporine	52.0	35.0	36, 45, 49, 51, 54, 64, 69, 80 (56.0 \pm 14.2)
Cyclosporine + prednisone	58.0	37.0	48, 50, 54, 59, 59, 63, 69, 78 (60.0 \pm 10.0)

^a Complete loss of motility for 24-hr period.

^b Contractile frequency less than 70% of baseline established for each graft.

^c Nonconcurrent controls.

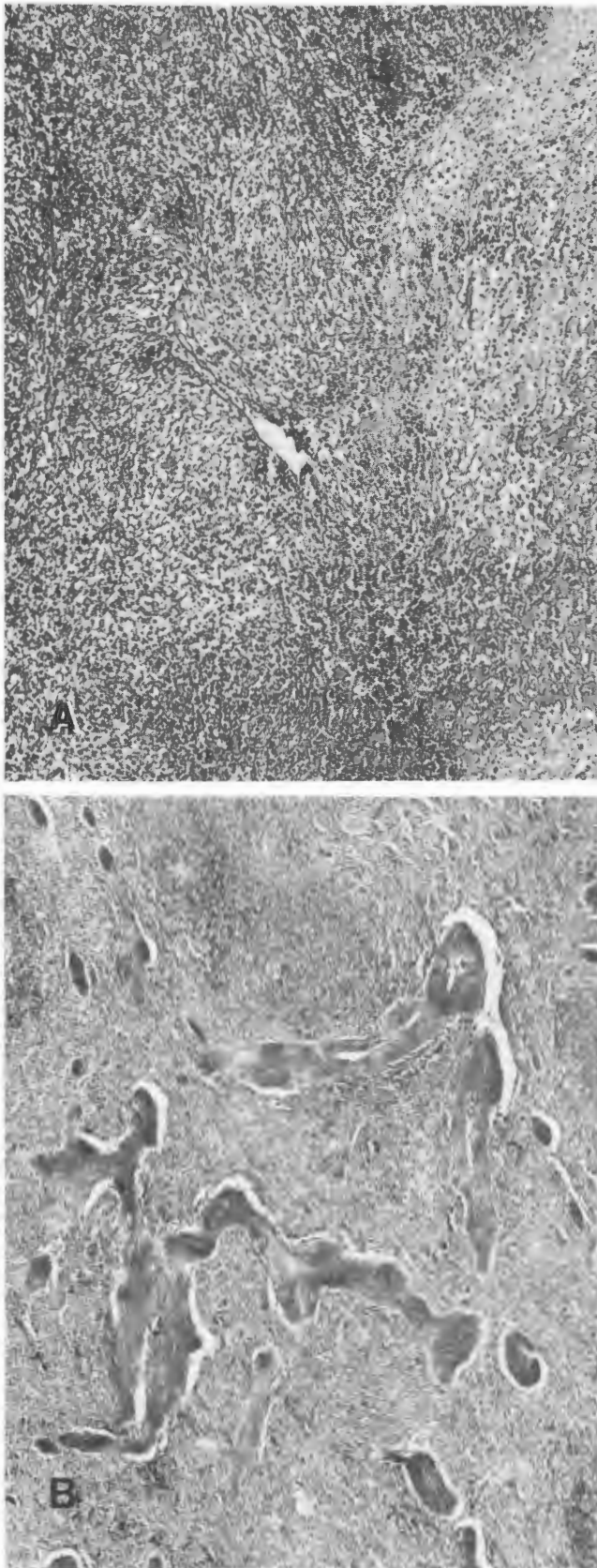


FIGURE 3. Cellular (azathioprine-treated dog, day 10) and vascular (cyclosporine-treated dog day 42) types of rejection. Note extensive thrombosis of small, medium, and large vessels in (B). Perivascular cuffing can be seen around two thrombosed arterioles.

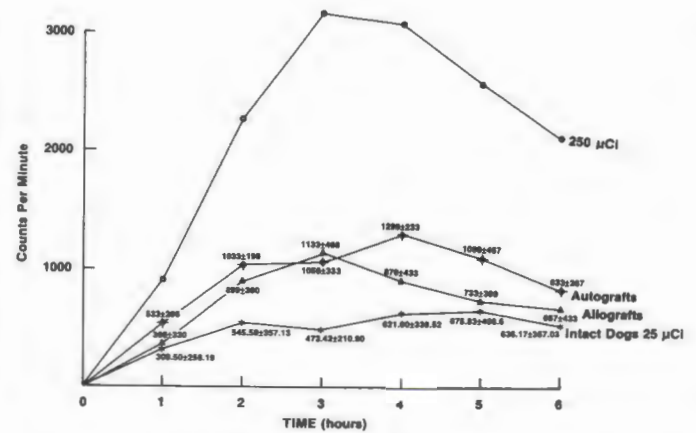


FIGURE 4. Oleic acid uptake curves in normal dogs, small bowel autografts, and allografts on day 14 after transplantation. All curves except the topmost represent 25 μ Ci of the isotope dose. The topmost curve represents 250 μ Ci of isotope administered orally to a normal dog.

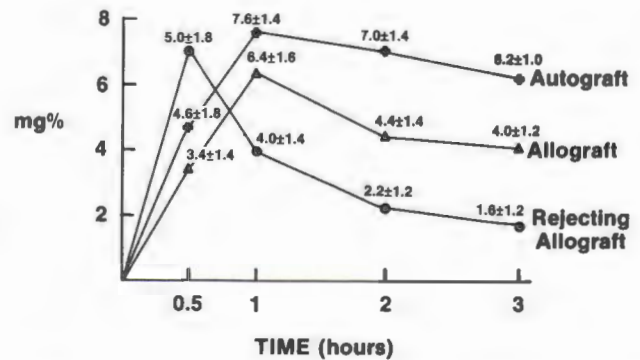


FIGURE 5. Xylose absorption curves in small bowel transplants at 14 days posttransplantation.

safely at twice-weekly intervals with adequate tissue obtained to monitor mucosal changes; (3) cyclosporine immunosuppression results in survival similar to that seen in the ectopic model; when cyclosporine was given at 17 mg/kg/day, mean survival in these three animals was 50.1 days; (4) uptake studies are less valid in this model due to the presence of normal host bowel distal to the graft; (5) cyclosporine absorption was probably diminished during rejection episodes despite presence of host bowel. Clinical ileus was seen from the onset of rejection.

The appearance of mucosal biopsy specimens during rejection was similar to that seen in the ectopic cervical loop. Round cell infiltration was not a prominent feature and became significant only late in rejection. Microvascular thrombosis appeared more prominent in these three grafts during rejection than in ectopic grafts—however, this may be due to distortion of the sample size.

DISCUSSION

The introduction of cyclosporine has facilitated experimental and clinical transplantation of many extrarenal organs previously considered difficult (11) because of poor graft prolongation obtained with azathioprine. It appears that small bowel allografts can be added to this growing list. In our model a 9-fold increase in allograft survival was obtained with cyclo-

sporine as compared with untreated control allografts; prolongation with azathioprine was negligible. The addition of prednisone to cyclosporine appeared to improve the histological appearance of small bowel allografts but did not improve graft survival obtained with cyclosporine alone. In our experimental design, no attempt was made to modify immunosuppression at onset of rejection. Even more dramatic graft survival may be possible if timely antirejection therapy can be instituted. This may be facilitated if some aspect of allograft function or histology can be used to monitor for early detection of the onset of rejection. In other organ systems, monitoring techniques once found useful with azathioprine have not had the same utility with cyclosporine. Allograft histology of the heart, lung, kidney, and liver obtained by sequential biopsy (unpublished data) appears to have become less reliable as a monitoring technique when cyclosporine is used. Our experience with small bowel allografts reported here is similar. There were no easily discernible lead changes in graft histology that could be utilized to reliably predict impending rejection (Table 3). Cellular infiltration often occurred randomly and did not consistently precede a rejection episode. When a rejection reaction did follow the appearance of a cellular infiltrate, the lead time was disappointingly negligible, especially when cyclosporine was used in combination with prednisone. The onset of villus blunting preceding rejection appeared to have a longer lead time, but this feature is too variable to be useful by itself. In combination with some other indicator such as graft motility, it may be a useful prediction of an approaching rejection episode.

Data from renal (14), lung (15), and heart (4) transplant work utilizing cyclosporine indicate the emergence of a vascular type of rejection not often seen with azathioprine. This unusual form of rejection process, with microvascular thromboses and sparse cellular infiltrate, appears to be a feature of small bowel transplants as well. The smooth muscle hypertrophy noticed by Craddock and associates (13) in some of their animals was not seen in our experience. Other features of small bowel transplant histology described by the Canadian group (16) are similar to our findings.

Motility characteristics of chronically surviving small bowel allografts have not been described in detail before, even though the methodology was described by Schiller et al. in 1973 (17). Even in the ectopic position, allografts maintain peristaltic activity that can be monitored quite easily with a pressure recording device. Decreased contractile frequency was found to be a useful lead indicator of approaching rejection in animals

receiving cyclosporine with or without prednisone (Table 2). With the Roux-en-Y technique motility studies can also be performed in the orthotopic allograft model.

Fat absorption is severely disturbed in small bowel autografts and allografts. This appears to be a function of lymphatic disruption associated with the transplant procedure. However, by two weeks following transplantation fat absorption is resumed. Since cyclosporine is fat-soluble, this drug should be administered i.v. for at least two weeks following total orthotopic transplantation of small bowel. The tritium-labelled oleic acid isotope technique to study fat absorption described here appears to be a useful technique in experimental small bowel transplantation.

The xylose technique for studying carbohydrate absorption is well established. Conflicting reports (9, 10) have appeared regarding the usefulness of xylose absorption curves in predicting rejection in small bowel transplants. It was our finding that xylose uptake is not affected until very late in the rejection process. Xylose absorption is unlikely to be useful in acute rejection.

It is generally believed that orthotopic small bowel grafts fare poorly compared with ectopic grafts. In our small number of segmental orthotopic grafts, this was not found to be true. In total orthotopic grafts, immunological factors, such as graft-versus-host reaction or technical complications, can limit recipient survival. This was not a problem in our study possibly due to the limited length of the small bowel graft. In massive small bowel replacement, a variety of technical and metabolic complications can be expected. Many of these metabolic features of small bowel transplantation remain to be clarified. For example, in the series reported by Craddock (16), experimental small bowel allografts were provided with venous drainage to the vena cava rather than the portal vein. Analogous to an Eck fistula, this technique could have been an adverse factor in the survival figures for orthotopic small bowel transplants reported by these researchers. This procedure in combination with the high cyclosporine dose employed by these investigators may have played a role in the high animal mortality reported in their series. Nevertheless, prolongation of orthotopic grafts with cyclosporine was unequivocally demonstrated in their study, as it was indeed confirmed by our own results reported here.

LITERATURE CITED

1. Alican F, Hardy JD, Cayirli M, et al. Intestinal transplantation: laboratory experience and report of a clinical case. *Am J Surg* 1971; 121: 150.
2. Ruiz JO, Uchida H, Schultz LS, Lillehei RC. Problems in absorption and immunosuppression after entire intestinal allotransplantation. *Am J Surg* 1972; 123: 297.
3. Preston FW, Macalalad F, Wachowski RJ, Randolph DA, Apostol JV. Survival of hemografts of the intestine with and without immunosuppression. *Surgery* 1966; 60: 1203.
4. Ballinger WF II, Christy MG, Ashby WB. Autotransplantation of the small intestine: the effect of denervation. *Surgery* 1962; 52: 151.
5. Kocandric V, Houttuin E, Prohaska JV. Regeneration of the lymphatics after autotransplantation and homotransplantation of the entire small intestine. *Surg Gynecol Obstet* 1966; 122: 587.
6. Hardy MA, Quint J, State D. Effect of antilymphocyte serum and other immunosuppressive agents on canine jejunal allografts. *Ann Surg* 1970; 171: 51.
7. Lillehei RC, Goldberg S, Goott B, Longerbeam JK. The present

TABLE 3. Relationship between histological changes and mean graft survival in ectopic small bowel transplants

Groups	Blunting of villi	Round cell infiltrate	Mucosal loss
Autografts			
5 dogs	0/5	0/5	0/5
Untreated			
5 dogs	5/5, 4 ^a	5/5, 4.7 ^a	3/5, 5.2 ^a
Azathioprine			
5 dogs	5/5, 8 ^a	4/5, 9.2 ^a	3/5, 9.6 ^a
Cyclosporine			
5 dogs	5/5, 40 ^a	2/5, 42.1 ^a	2/5, 51 ^a
Cyclosporine + prednisone			
5 dogs	5/5, 47 ^a	2/5, 52 ^a	1/5, 52 ^a

^a Mean day of appearance posttransplant.

- status of intestinal transplantation. *Am J Surg* 1963; 105: 58.
8. Lillehei RC, Idezuki Y, Feemster JA, et al. Transplantation of stomach, intestine, and pancreas: experimental and clinical observations. *Surgery* 1967; 62: 721.
 9. Holmes JT. Small-bowel transplantation: an experimental study. *Ann R Coll Surg Engl* 1973; 52: 165.
 10. Cohen WB, Hardy MA, Quint J, State D. Absorptive function in canine jejunal autografts and allografts. *Surgery* 1969; 65: 440.
 11. White DJG, ed. *Cyclosporin A*. Amsterdam: Elsevier, 1982.
 12. Benson JA Jr, Culver PJ, Ragland S, et al. The d-xylose absorption test in malabsorption syndromes. *N Engl J Med* 1957; 256: 335.
 13. Craddock GN, Nordgren SR, Renznick RK, et al. Small bowel transplantation in the dog using cyclosporin. *Transplantation* 1983; 35: 284.
 14. Kahan BS, ed. *Proceedings of the First International Congress on Cyclosporin*. (in press).
 15. Veith FJ, Kamholz SL, Mollenkopf FP, Montefusco CM. Lung transplantation 1983. *Transplantation* 1983; 35: 271.
 16. Lossing A, Nordgren S, Cohen Z, et al. Histologic monitoring of rejection in small intestinal transplantation. *Transplant Proc* 1982; 14: 643.
 17. Schiller WR, Suriyapa C, Mutchler JHW, et al. Motility changes associated with canine intestinal-allografting. *J Surg Res* 1973; 15: 379.

Received 21 December 1983.

Accepted 6 June 1984.