

Catheter-directed Thrombolysis for Deep Venous Thrombosis

Seshadri Raju, M.D.
Todd Fountain, B.S.
Scott H. McPherson, M.D.

Key words: *urokinase, thrombolysis, catheter-directed*

Introduction

Deep venous thrombosis is a common clinical problem. An estimated 2 to 3 million new cases occur annually in the United States.¹ The sequelae include pulmonary embolism and postthrombotic syndrome. While much clinical attention has focused on embolism because of potential loss of life from this complication, the incidence is actually quite low (12% to 20%; mortality 0.5% to 3%) compared to postthrombotic syndrome, which develops in 50% to 70% of patients after a bout of deep venous thrombosis.² Roughly half of these patients have the severe form of the syndrome. The reported incidence is probably an underestimate because of the slow evolution and indolent presentation of the syndrome. Several years and even decades may elapse before patients become symptomatic, typically following a recurrent bout of thrombosis that results in decompensation of an already damaged venous system. The direct and indirect costs of treating the syndrome are staggering.³ Because many in the working age population are affected, man hours and wages lost in the workplace contribute significantly to the social costs of this problem.

It is now recognized that a combination of outflow obstruction and valve reflux is the pathophysiological basis of the postthrombotic syndrome.⁴ These pathologic alterations are directly related to the onset and evolution of the thrombus load. Rapid elimination of the thrombus load after onset would logically be expected to eliminate

or at least ameliorate the evolution of postthrombotic syndrome. It is well established that the conventional heparin-warfarin anticoagulation regime has little or no thrombolytic role, hence the thrombus load remains largely unchanged. In about 20% of patients, the thrombus load may actually increase during the early period of anticoagulant induction.⁵ For this reason the incidence of postthrombotic syndrome has remained unaffected by the introduction of anticoagulant therapy for deep venous thrombosis. The major benefit has been a reduction in the incidence of pulmonary embolism.

There have been a number of attempts, particularly in Europe,⁶ to employ therapeutic approaches other than heparin-warfarin removal of the thrombus load after the onset of deep venous thrombosis. These have included systemically administered thrombolytic agents and surgical thrombectomy. The latter procedure pioneered by Mahorner⁷ in the United States in the 1940s, quickly lost favor due to a high incidence of recurrent thrombosis.⁸ The procedure was resurrected in Europe and has remained popular with the addition of a temporary adjunct A-V fistula to the thrombectomy procedure, which eliminated the problem of recurrent thrombosis.⁶ A meta analysis of the thrombolytic and surgical approaches to the elimination of the thrombus load shows a clear advantage over conventional anticoagulant therapy in terms of venous channel patency and reduction in the onset of clinical symptoms of postthrombotic syndrome.⁶ The recent advent of catheter-directed technologies for the administration of thrombolytic agents in the arterial

system, particularly the spectacular results achieved in the coronary and peripheral vascular thrombosis, has rekindled interest in their application in deep venous thrombosis. The previously noted superior results in the meta analysis lend some credibility to this approach. A national registry that was established only a few months ago for collecting uniform data on this thrombolytic technique already has nearly 200 entries. In this report, we describe our experience with catheter-directed thrombolysis in 24 cases of deep venous thrombosis.

Materials and Methods

Since the initiation of the program in July 1995, twenty-four patients have been treated with urokinase using the catheter-directed technique. Patients ranged in age from 17 to 70 (16 were male and 8 were female). Eighteen patients (80%) were treated within 3 weeks of the onset of deep venous thrombosis based on history while the remaining six patients were treated 3 to 24 weeks after the onset.

Deep venous thrombosis was confirmed by ascending venography prior to the initiation of treatment. The proximal extent of the thrombus was as follows: IVC 5, iliac 7, femoral 10, and popliteal 2.

Technique of Catheter-Directed Thrombolysis

The original internal jugular or contralateral femoral approaches have been abandoned in favor of ipsilateral venipuncture for catheter placement. Coaxial catheters for infusion of urokinase are preferentially used to traverse the entire length of the thrombus. This generally involves a "criss-cross" technique of employing two separate coaxial catheters for proximal and distal thrombus coverage when the venipuncture site is either femoral or popliteal vein midway in the extent of the thrombus. A single catheter traversing the entire thrombus can usually be employed if the portal of catheter entry is the posterior tibial vein near the ankle or the soleal sinusoid. Between 150,000 to 200,000 units of Urokinase per hour, divided between the catheters and the sheath, are administered for 24 to 72 hours to achieve complete or maximum possible clot dissolution. Intravenous heparin is simultaneously administered, preferably through the sheath or other venous access. Progression of thrombolysis is monitored by contrast venography at 24-hour intervals, at which time catheter positions may be readjusted and residual stenotic lesions may be balloon dilated or stented. Serum fibrinogen levels, fibrin split products and other coagulation parameters are routinely monitored every 12 hrs for the duration of thrombolytic therapy. Prior to the institution of thrombolysis all patients should be screened for

hypercoagulability and the presence of occult malignancy. Warfarin anticoagulation is instituted with cessation of urokinase, but heparin therapy is continued until targeted INR (International Normalization Ratio) levels are achieved. Patients have been followed up at 3-month intervals after thrombolytic therapy.

Catheter-directed thrombolysis is contraindicated during pregnancy, after recent surgery (<12 days), recent stroke, gastrointestinal hemorrhage, cerebral metastasis or thrombus in cardiac chambers.

Results

No mortality or major complications followed the procedure; one patient died twelve months later from coexisting malignancy. Two of 24 patients experienced local discomfort and hematoma at the venipuncture site; surgical intervention to stop the local bleeding was not necessary. Transfusion was required in two patients to maintain an adequate hematocrit. Complete thrombus clearance was achieved in 17 patients and partial clot clearance in four, while thrombolysis in the remaining three was considered unsuccessful. Balloon dilatation of a residual stenotic lesion was required in 12 patients, of whom six (25%) also required a stenting procedure (Fig. 1). At 3-months follow-up 79% of treated patients remain asymptomatic, 17% are improved over pretreatment symptomatology with residual symptoms, and 4% are considered to have received no therapeutic benefit from thrombolysis. Based on the arm-foot venous pressure differential technique,⁹ 81% of treated patients remain free of significant venous outflow obstruction. This hemodynamic technique is considered the most sensitive of currently available techniques to measure venous obstruction.³ Although duplex indicates that in 58% of

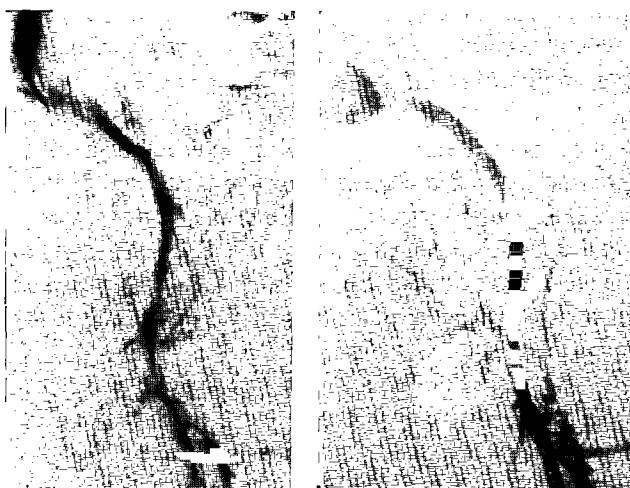


Figure 1. Residual stenosis after thrombolysis of iliac vein thrombus (left) treated by a long stent (right).

treated patients the venous valves in the segment occupied by the thrombus prior to dissolution are fully functional and competent, 77% of patients evince some evidence of reflux by airplethysmography or ambulatory venous pressure measurement.

Illustrative Cases

Case 1: A 17-year-old female was referred for sudden onset of bilateral leg swelling. She had been a passenger in a motor vehicle accident 3 weeks previously, but sustained no obvious injuries. Mild antithrombin III deficiency was present. Venography demonstrated extensive deep venous thrombosis extending proximally into the vena cava up to the renal veins (Fig. 2a&b). Catheter-directed thrombolysis was successful in complete resolution (Fig. 2c). One year after the intervention the patient is completely asymptomatic with no evidence of valve damage.

Comment: *Patients with such an extensive deep venous thrombosis are invariably symptomatic with*

traditional anticoagulation therapy. Restoration to an asymptomatic status is therefore unique to catheter-directed thrombolytic therapy.



Figure 2a.

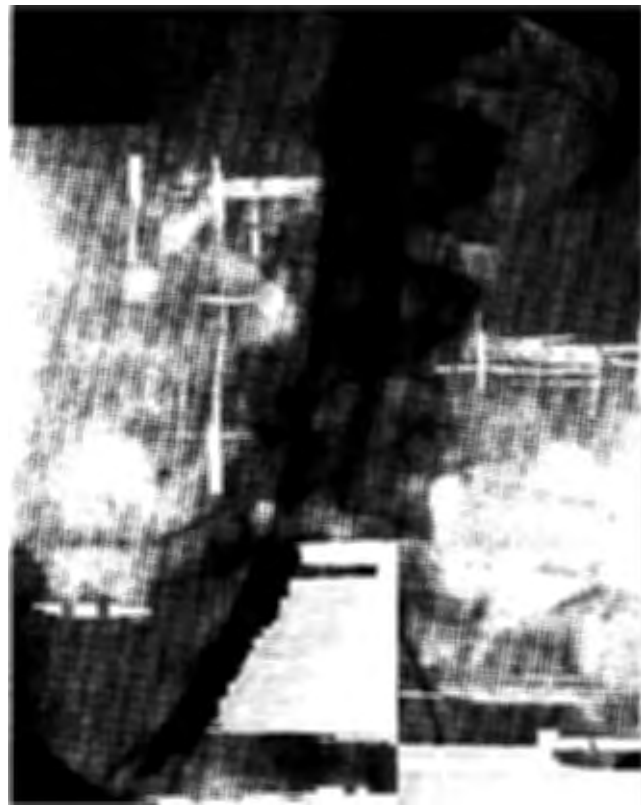

Figure 2b.




Figure 2c.

Figure 2. *Iliac vein thrombus (a) extending to the inferior vena cava (b) with complete resolution after urokinase thrombolysis (c).*

Case 2: A 63-year-old otherwise healthy male sustained deep venous thrombosis of the left lower extremity during Thanksgiving holidays, which was documented by Duplex scan. He was treated with conventional anticoagulation regimen with persistent moderate swelling and pain in the affected leg. He extended the thrombus on anticoagulation in February 1997, nearly 4 months after the initial event. Owing to excruciating pain associated with the new clot extension, he was treated with catheter-directed thrombolysis in the hope of restoring to the previously symptomatic level of tolerable pain. Surprisingly complete thrombolysis was obtained including the 4-month-old clot. The patient is totally asymptomatic 2 months after successful thrombolysis.

Comment: *Thrombolysis of a clot older than 3 weeks is rare. Clot resolution, however, can occur to a variable extent in a thrombus up to 6 months after its formation because of individual variation in the time course of thrombus organization. In rare instances, as in the case above, the thrombus fails to show any evidence of organization even after several months of initiation apparently because of a process of ongoing dynamic lysis and thrombosis. The precise mechanism of this phenomenon is unknown.*

Discussion

Traditional anticoagulation remains the gold standard of therapy for deep venous thrombosis. It has been highly effective in reducing the incidence of pulmonary embolism and the dreaded sudden death syndrome from this cause. The incidence of postthrombotic syndrome, however, has remained unaffected with this mode of therapy. This complication, while less dramatic than embolism, is more insidious and extracts a high monetary and social cost on the affected population. Many of these patients are in their productive years in terms of physical work and activity. A more aggressive approach toward thrombolysis rather than stabilization of existing thrombus load in this group of patients would seem to be justified. Short-term data and experience are promising but long-term follow-up is required to establish a benefit in reducing postthrombotic syndrome after catheter-directed thrombolysis.

References

1. Clagett GP, Anderson FA, Heit J, et al. Prevention of venous thromboembolism. *Chest* 108:312s-34s, 1995.
2. Meissner MH, Manzo RA, Bergelin RO, Markel A, Strandness DE, Jr. Deep venous insufficiency: The relationship between lysis and subsequent reflux. *J Vasc Surg* 18:596-608, 1993.

3. Nicolaidis AN. International Consensus Conference on Chronic Venous Insufficiency. Paris, France, February 1997 (in press).
4. Johnson BF, Manzo RA, Bergelin RO, Strandness DE, Jr. Relationship between changes in the deep venous system and the development of the postthrombotic syndrome after an acute episode of lower limb deep vein thrombosis: A one-to-six-year follow-up. *J Vasc Surg* 21:307-13, 1995.
5. Killewich LA, Bedford GR, Beach KW, Strandness DE, Jr. Spontaneous lysis of deep venous thrombi: Rate and outcome. *J Vasc Surg* 9:89-97, 1989.
6. Eklöf B, Neglén P. Venous thrombectomy. In: *Surgical Management of Venous Disorders*. Eds. Raju S, Villavicencio JL. Baltimore, Williams & Wilkins Publishers, 1997.
7. Mahorner H, Castelberry JW, Coleman WO. Attempts to restore function in major veins which are the site of massive thrombosis. *Ann Surg* 146:510-22, 1957.
8. Lansing AM, Davis WM. Five year follow-up study of iliofemoral venous thrombectomy. *Ann Surg* 168:620-28, 1968.
9. Neglén PN, Raju S. Detection of outflow obstruction in chronic venous insufficiency. *J Vasc Surg* 17:583-89, 1993.

Seshadri Raju, M.D.: Vascular Surgeon, River Oaks Hospital. Academic Appointment: Professor Emeritus and Honorary Surgeon, Department of Surgery, University of Mississippi Medical Center.

Todd Fountain, B.S.: Medical Student (M1) at University of Mississippi Medical Center.

Scott H. McPherson, M.D.: Internentional Radiologist, River Oaks Hospital. Academic Appointment: Clinical Assistant Professor of Radiology, University of Mississippi Medical Center. Practice Location: Lakeland Radiologists P.A., 1151 N. State Street, Jackson, MS 39202.

Reprint Requests: Seshadri Raju, M.D.
1020 River Oaks Drive, Suite 420
Jackson, MS 39208
Telephone: (601) 939-4230
Fax: (601) 939-5210