



Case Report

Utility of a Mechanical Thrombectomy Device in Treating Calcified Instent Restenosis Post Iliofemoral Venous Stenting

Arjun Jayaraj, and Seshadri Raju, Jackson, MS

Instent restenosis (ISR) following iliofemoral venous stenting is quite common with up to three-quarters of patients developing some degree of ISR. However, only around 16% develop recurrent symptoms impairing their quality-of-life meriting reintervention. The first line of treatment for such ISR involves the use of angioplasty balloons to recreate an adequate flow channel. At times such angioplasty alone is inadequate particularly in the presence of calcified ISR. It is in this setting that the authors decided to explore the utility of a mechanical thrombectomy device to debulk the ISR and thereby help create an adequate flow channel. The successful utilization of such a device in a patient presenting with recurrent, disabling, quality of life impairing symptoms due to ISR represents the focus of this report.

Stenting has become the standard of care for patients presenting with quality-of-life impairing symptoms of chronic iliofemoral venous obstruction (CIVO) who fail conservative therapy.¹⁻⁵ While an overwhelming majority of these patients go on to do well, a significant minority (~16%) develop instent restenosis (ISR) leading to recurrent symptoms of CIVO warranting reintervention.⁶ Historically such reintervention has been angioplasty with balloons equal to or larger than the rated diameter of the stent. Often such angioplasty alone does not lead to the creation of an adequate flow channel in up to 20% of patients.⁷ In these patients, laser ablation of ISR has been described.⁷ While laser ablation and subsequent angioplasty are helpful with recalcitrant ISR, this technique is not very helpful in the setting of calcified ISR. Such a lesion ideally requires debulking to create a channel

that can then be built upon by angioplasty. To help with such debulking of ISR the authors decided to use a mechanical thrombectomy device – the Inari ClotTrierer Thrombectomy System (Inari Medical, Irvine, CA). This case report describes the innovative technique and the outcome in a patient who underwent the procedure.

CASE REPORT

A 41-year-old African American female heterozygous for prothrombin gene mutation had originally presented with a 10-year history of left lower extremity swelling, pain, and hyperpigmentation suggestive of post thrombotic syndrome (PTS) back in 2016. These symptoms had started after an episode of deep venous thrombosis (DVT) and pulmonary embolism (PE) in 2006. For some unknown reason, she had been taken off her anticoagulation in 2015. Duplex ultrasound (DUS) done at the time of the clinic visit was suggestive of PTS. In light of her severe, quality of life impairing symptoms, she underwent intravascular ultrasound (IVUS) interrogation (Visions PV .035 digital IVUS catheter – Philips, Amsterdam, Netherlands) that confirmed the diagnosis. Angioplasty and stenting were consequently carried out using a composite

The RANE Center for Venous & Lymphatic Diseases, St. Dominic Hospital, Jackson, MS

Correspondence to: Arjun Jayaraj, MD, The RANE Center for Venous & Lymphatic Diseases, St. Dominic Hospital, 971 Lakeland Drive, Suite #401, Jackson, MS 39216, USA; E-mail: jayaraj.arjun2015@gmail.com

Ann Vasc Surg 2021; 000: 1.e1–1.e5

<https://doi.org/10.1016/j.avsg.2021.08.020>

© 2021 Elsevier Inc. All rights reserved.

Manuscript received: May 23, 2021; manuscript revised: June 21, 2021; manuscript accepted: August 27, 2021; published online: xxx

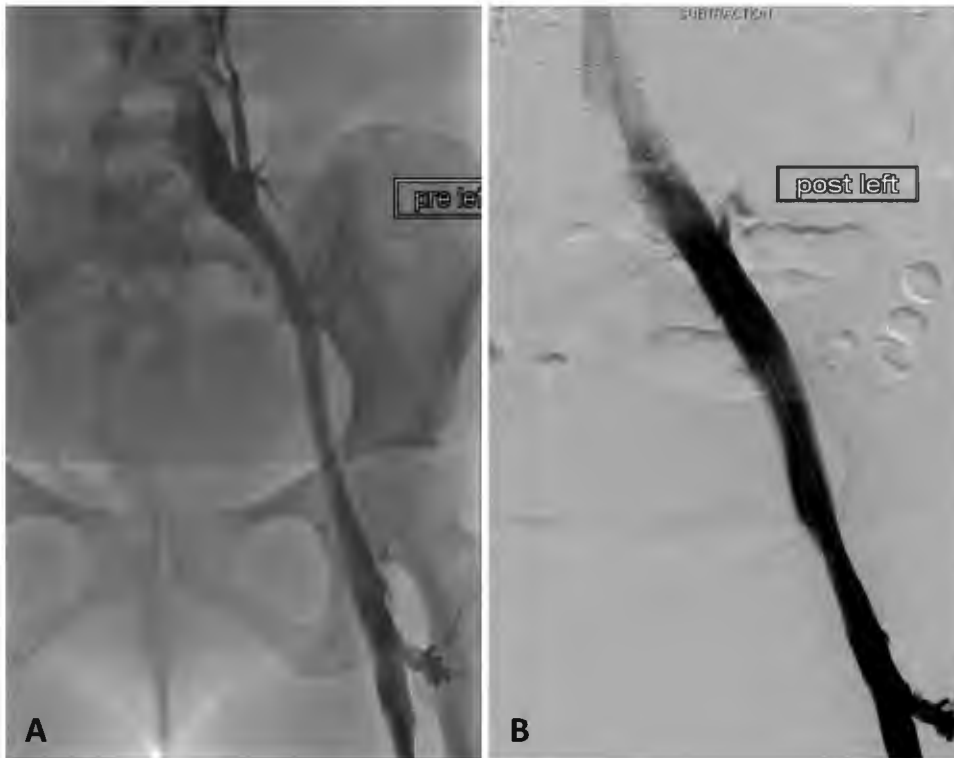

Fig. 1. (A–B). (A) Pre stenting venogram demonstrating severe stenosis with pancaking at the level of the left common iliac vein – caval confluence with filling of collaterals in addition to long segment iliac vein stenosis caudally. (B) Venogram demonstrating correction of stenotic components post stenting with preferential inline flow.

Wallstent (Boston Scientific, Marlborough, MA) - Z stent (Cook Medical, Bloomington, IN) configuration (Fig. 1 A, B) extending from the cranial common femoral vein to the distal inferior vena cava just cranial to the iliac confluence. Post stenting, she had significant improvement of her symptoms with the venous clinical severity score (VCSS) improving from a pre-op score of 9–5 post stenting, the visual analog scale (VAS) pain score improving from 8–0 and the grade of swelling going from 3 (swelling involving the leg up to the knee) to 0 (No swelling). Post intervention she was placed on apixaban 5 mg twice daily, cilostazol 50 mg twice daily, and aspirin 81 mg daily. At the 6-month mark post procedure, the cilostazol was stopped, and around the 9-month mark, the apixaban was dropped to 2.5 mg twice daily. The ASA was continued at the 81 mg dose. She was followed with routine DUS / clinical visits and remained asymptomatic till early 2021 when she developed a recurrence of disabling symptoms including, pain, swelling, heaviness, tiredness of the left leg with impairment of her quality of life over a 4-week period. DUS performed revealed a trickle flow channel in the external iliac vein with ISR in the remainder of the stent ranging from 38%–53%

(Fig. 2). Given this clinical deterioration and DUS findings, the apixaban was increased to 5 mg BID. Additionally, we decided to proceed with IVUS interrogation (Fig. 3A, B) to confirm the diagnosis. This was accomplished under general anesthesia with the patient in the prone position via access of the popliteal vein under ultrasound guidance using micropuncture technique and placement of a 11Fr x 10 cm sheath. The interrogation revealed severe ISR with calcifications including ring calcification within the EIV with associated near occlusion (Fig. 3A). In light of this discovery, it was decided to debulk the ISR before angioplasty. The 11Fr sheath was replaced with a ClotTrieve Sheath over an 0.035" 260 cm Amplatz super stiff guidewire (Boston Scientific, Marlborough, MA). 4 passes (3, 6, 9, and 12 o'clock) of the ClotTrieve Catheter were then carried out in a sequential manner across the entire length of the Wallstent column starting just below the Z stent. These passes retrieved chronic calcified thrombus (Fig. 4A–C). Interval IVUS interrogation revealed improvement of the ISR burden, particularly the calcified part with an improved flow channel. At this point angioplasty was carried out using a 16 × 60 mm Atlas Gold angioplasty balloon (Becton, Dickinson,

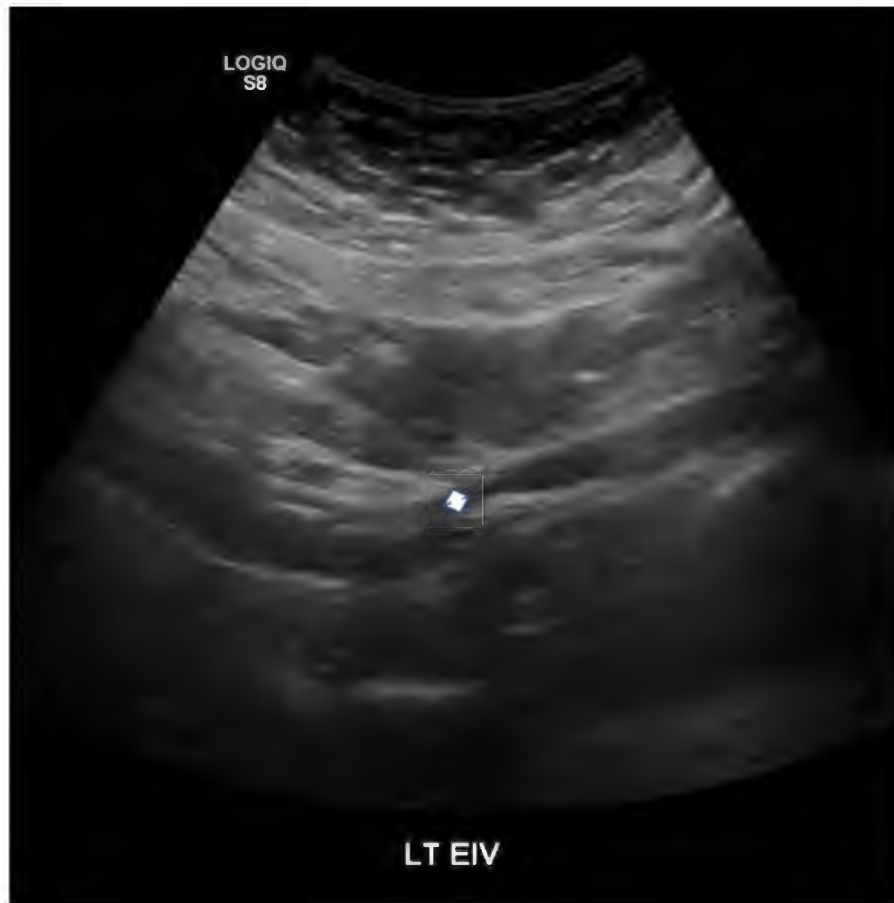

Fig. 2. Duplex ultrasound B mode transverse image of the left external iliac venous stent segment demonstrating severe in-stent restenosis with calcification (near occlusion). The white arrow depicts the remaining trickle flow channel.

and Company, Franklin Lakes, NJ) inflated to burst pressure (16 mm Hg) to help build on the work done by the thrombectomy device. Post angioplasty, we did one more pass with the device to see if we could further debulk the residual ISR. This was followed by stent extension (18 × 80 mm Venovo stent [Becton, Dickinson, and Company, Franklin Lakes, NJ]) into the widely patent common femoral venous segment to provide good inflow into the stent. Post dilation was then carried out using a 20 × 40 mm Atlas Gold angioplasty balloon inflated to burst pressure (16 mm Hg) to optimize the flow channel across the entire stent column at the same time deal with the minimal residual ISR and was successful on both counts. This was followed by completion IVUS (Fig. 5) and completion venogram, which demonstrated good results. She tolerated the procedure well and was discharged home the following day after the post procedure DUS demonstrated a widely patent iliofemoral stent column. Post intervention she was maintained on apixaban 5 mg BID and ASA 81, with plans to continue both lifelong. At one month follow up she

was doing well with her VCSS having improved from 9–5, the VAS pain score from 5–1, and GOS from 3–0. Additionally, she continued to have a widely patent stent.

DISCUSSION

In-stent restenosis following venous stenting represents the most common reason for reintervention. While balloon angioplasty has been in use to deal with this problem for some time, more recently, laser ablation of the ISR, and atherectomy have been described in patients who do not respond to angioplasty alone (~20%).^{7,8} While these techniques represent useful options in this situation, their effectiveness is limited in the presence of calcium. Additionally, they can provide only small volume debulking since they were primarily developed for use in the arterial system. The Inari ClotTriever Thrombectomy System on the other hand was developed for use in the venous territory. The coring element (Fig. 4B) that this device has enables larger volume shaving of

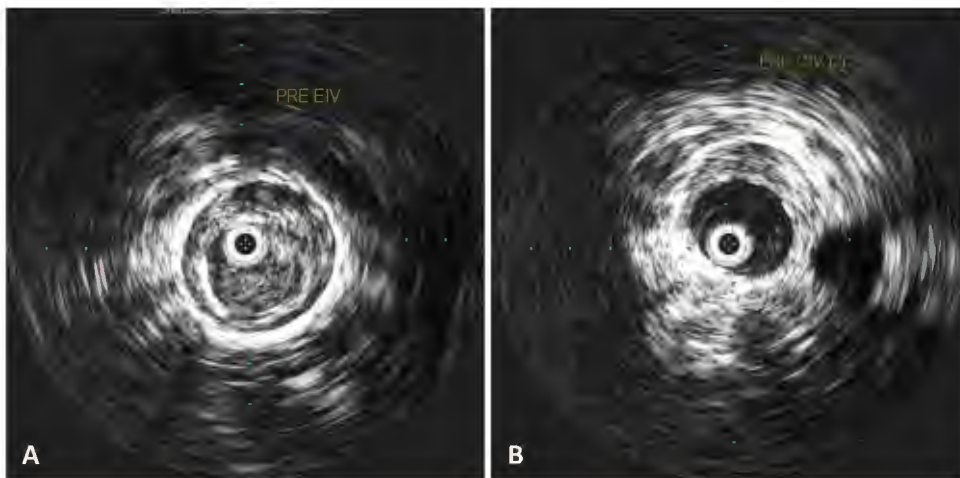


Fig. 3. (A–B) Initial IVUS interrogation of the left iliac vein stent. (A) demonstrates severe ISR with an internal ring of concentric calcification and barely a luminal channel. (B) moderate ISR in the common iliac venous stent segment.

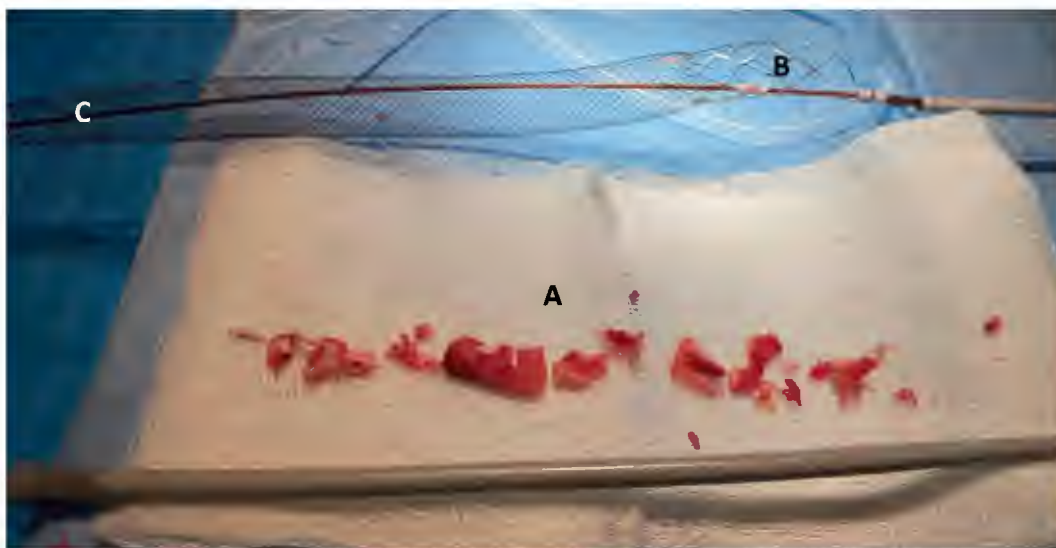


Fig. 4. (A–C) Chronic calcified thrombus (A) excised using the Inari ClotTrievers Thrombectomy System with the coring element (B) and the collection bag (C) in the background.

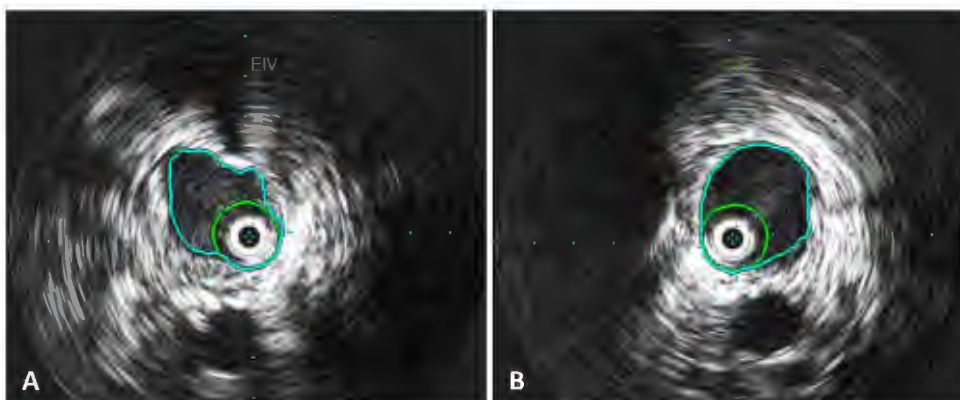


Fig. 5. (A–B) Completion IVUS interrogation of the left iliac vein stent. A and B - Widely patent external iliac and common iliac venous stent segments respectively post excision thrombectomy.

calcified lesions thereby enabling more effective debulking. The excised debris is captured by the collection bag and retrieved via the ClotTrievers sheath. Users should bear in mind that there is the risk of the collection bag (Fig. 4C) getting caught in the tines of an inferior vena cava filter or a Z stent. In the presence of such devices, it is best to start the excision thrombectomy below the filter / Z stent as was done for this patient.

Angioplasty in the setting of significant calcium burden within the ISR is often ineffective due to the resistance offered by the calcium and disruption of the balloon from the irregular edges of the deposited calcium. Debulking such ISR helps overcome these problems and enables the creation of a channel which can then be built upon by the angioplasty. This represents the rationale behind pursuing debulking first in calcified ISR lesions.

The reason for recurrent ISR build-up in this patient is unknown, possibly related to the lower dose of apixaban. Her ISR in the 5 years post stenting ranged from 26%–52%. However, an intervention was not pursued previously as she remained asymptomatic. Indication for reintervention for ISR is the recurrence of quality-of-life impairing symptoms and not a percentage ISR cut off.^{6,9} Follow up post iliofemoral venous stenting in our practice is lifelong using a combination of DUS and clinic visits. The initial post procedure DUS is performed on day 0/1 (if they have been admitted for overnight observation), week 3, months 3, 6, 12 post stenting. Clinic visits started at the 3-week mark post intervention and coincide with the DUS visits. Subsequent visits are usually on a yearly basis as long as the patient remains without quality of life impairing clinical recurrence and/or significant stent malfunction.

This report represents the innovative use of a thrombectomy device to deal with calcified ISR which while being rare is very hard to deal with using conventional techniques. While the report demonstrates the safety and efficacy of the technique, a larger series would help shed further light on the use of this technology.

CONCLUSIONS

The ClotTrievers Thrombectomy System can help debulk calcified in-stent restenosis in iliofemoral venous stents in patients presenting with recurrent quality of life impairing symptoms. While the technique appears to be safe and effective, further study is required to corroborate these findings.

REFERENCE

1. Gutzeit A, Zollikofer Ch L, Dettling-Pizzolato M, et al. Endovascular stent treatment for symptomatic benign iliofemoral venous occlusive disease: long-term results 1987-2009. *Cardiovasc Intervent Radiol* 2011;34:542–9.
2. Neglen P, Hollis KC, Olivier J, et al. Stenting of the venous outflow in chronic venous disease: long-term stent-related outcome, clinical, and hemodynamic result. *J Vasc Surg* 2007;46:979–90.
3. Hartung O, Loundou AD, Barthelemy P, et al. Endovascular management of chronic disabling ilio-caval obstructive lesions: long-term results. *Eur J Vasc Endovasc Surg* 2009;38:118–24.
4. Ye K, Lu X, Li W, et al. Long-term outcomes of stent placement for symptomatic nonthrombotic iliac vein compression lesions in chronic venous disease. *J Vasc Interv Radiol* 2012;23:497–502.
5. Seager MJ, Busuttill A, Dharmarajah B, et al. Editor's choice - a systematic review of endovenous stenting in chronic venous disease secondary to iliac vein obstruction. *Eur J Vasc Endovasc Surg* 2016;51:100–20.
6. Jayaraj A, Noel C, Kuykendall R, et al. Long-term outcomes following use of a composite Wallstent-Z stent approach to iliofemoral venous stenting. *J Vasc Surg Venous Lymphat Disord* 2020.
7. Jayaraj A, Fuller R, Raju S. Role of laser ablation in recalcitrant in-stent restenosis post iliofemoral venous stenting. *J Vasc Surg Cases Innov Tech* 2021;7:298–301.
8. Robertson C, Varcoe RL, Black S, et al. Histopathology of ilio-caval venous in-stent restenosis treated with directional atherectomy. *J Endovasc Ther* 2019;26:742–6.
9. Jayaraj A, Powell T, Raju S. Utility of the 50% stenosis criterion in patients undergoing stenting for chronic iliofemoral venous obstruction. *J Vasc Surg Venous Lymphat Disord* 2021. doi:10.1016/j.jvsv.2021.05.008.