

# Unexpected major role for venous stenting in deep reflux disease

Seshadri Raju, MD,<sup>a</sup> Rikki Darcey, BS,<sup>b</sup> and Peter Neglén, MD, PhD,<sup>b</sup> *Jackson and Flowood, Miss*

**Background:** Treatment of chronic venous insufficiency (CVI) has largely focused on reflux. Minimally-invasive techniques to address superficial and perforator reflux have evolved, but correction of deep reflux continues to be challenging. The advent of intravascular ultrasound (IVUS) scan and minimally invasive venous stent technology have renewed interest in the obstructive component in CVI pathophysiology. The aim of this study is to assess stent-related and clinical outcomes following treatment by iliac venous stenting alone in limbs with a combination of iliac vein obstruction and deep venous reflux.

**Methods:** A total of 528 limbs in 504 patients, ranging in age from 15 to 87, underwent IVUS-guided iliac vein stent placement to correct obstruction over an 11-year period. The etiology of obstruction was nonthrombotic in 196 (37%), post-thrombotic in 285 (54%) limbs, and combined in 47 (9%). Clinical severity class of CEAP was C<sub>3</sub> in 44%, C<sub>4,5</sub> in 27%, and C<sub>6</sub> in 25% of stented limbs. Deep venous reflux was present in all limbs, associated with superficial and/or perforator reflux in 69%. Reflux was severe in 309/528 (59%) limbs (reflux multisegment score  $\geq 3$ ) and 224/528 (42%) limbs had axial reflux. Venography and other functional tests had poor diagnostic sensitivity to detect obstruction, which was ultimately diagnosed by IVUS. The IVUS-guided iliac vein stenting was the only procedure performed and the associated reflux was left uncorrected.

**Results:** There was no mortality; morbidity was minor. Cumulative secondary stent patency was 88% at 5 years; no stent occlusions occurred in nonthrombotic limbs. Cumulative rates of limbs with healed active ulcers, freedom of ulcer recurrence in legs with healed ulcers (C<sub>5</sub>), and freedom from leg dermatitis at 5 years were 54%, 88%, and 81%, respectively. Cumulative rate of substantial improvement of pain and swelling at 5 years was 78% and 55%, respectively. Quality of life improved significantly. Reflux parameters did not deteriorate after stenting.

**Conclusion:** Iliac venous stenting alone is sufficient to control symptoms in the majority of patients with combined outflow obstruction and deep reflux. Partial correction of the pathophysiology in limbs with multisystem or multilevel disease can provide substantial symptom relief. Percutaneous stent technology in concert with other minimally-invasive techniques to address superficial and/or perforator reflux offers such partial correction in limbs with advanced CVI and complex venous pathology. Open correction of obstruction or reflux is now required only infrequently as a "last resort". (J Vasc Surg 2010;51:401-9.)

Reflux is considered the dominant pathology in chronic venous insufficiency (CVI). The diagnosis and treatment of reflux has been the main focus of managing symptomatic patients with CVI for over a century. It has, however, been recognized that obstruction alone may cause symptoms in a small subset of patients with CVI (with post-thrombotic limbs<sup>1</sup> or those with primary disease (May-Thurner syndrome).<sup>2</sup> Venovenous bypass was the standard in treating the obstruction in such cases.<sup>3</sup> With the use of intravascular ultrasound scans and other modern imaging technologies, it is now known that morphologic obstruction of the iliac veins is ubiquitous<sup>4</sup> and can be demonstrated to be present in the majority of patients with CVI alone or in association with reflux.<sup>5,6</sup> The pathophysiologic significance of this finding is unclear. Whether or not it is necessary to correct this iliac vein obstruction in limbs with combined obstruc-

tion/reflux is unknown. The indications for intervention are not well defined. The advent of percutaneous stent technology allows for a relatively simple way to correct iliac vein obstructions, and endovenous stenting has largely replaced Palma bypass with excellent stent patency and clinical outcome.<sup>7-10</sup> Stenting was initially performed in patients with CVI with isolated iliac vein obstruction without associated reflux. After having established its safety and efficacy, stenting was performed as the initial treatment of patients with combined obstruction and deep venous reflux. The intention was to later perform valve reconstruction with the aim of achieving better symptom relief than with valve reconstruction alone. Surprisingly, symptom relief with initial iliac vein stenting was so effective that additional valve repair was found to be unnecessary in the majority of patients. The aim of this study is to assess stent-related and clinical outcomes following treatment by iliac venous stenting alone in limbs with a combination of iliac vein obstruction and deep venous reflux. The reflux remained untreated.

From the University of Mississippi Medical Center,<sup>a</sup> and River Oaks Hospital.<sup>b</sup>

Competition of interest: none.

Presented at the 2009 Vascular Annual Meeting, Denver, Colo.

Reprint requests: Seshadri Raju, MD, 1020 River Oaks Dr, #420, Flowood, MS 39232 (e-mail: rajumd@earthlink.net).

The editors and reviewers of this article have no relevant financial relationships to disclose per the JVS policy that requires reviewers to decline review of any manuscript for which they may have a competition of interest.

0741-5214/\$36.00

Copyright © 2010 by the Society for Vascular Surgery.

doi:10.1016/j.jvs.2009.08.032

## PATIENTS AND METHODS

Iliac vein stenting was performed in a total of 1640 limbs during 1997-2008 (11 years). Of these, 1112 limbs were excluded from this analysis because deep reflux was absent or other procedures were carried out concurrent

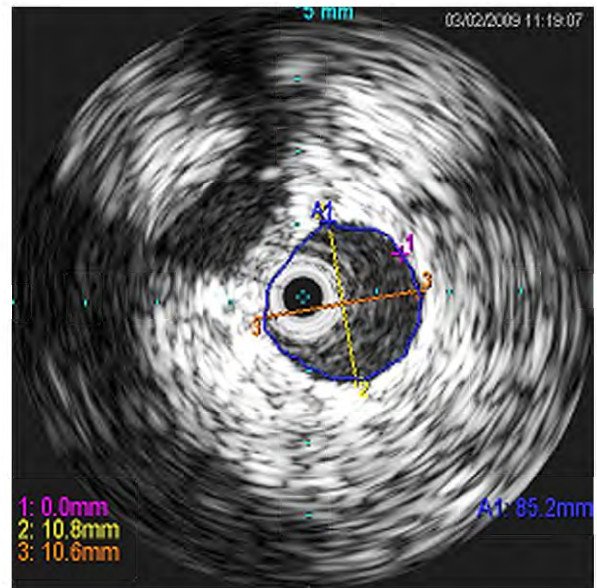
with stent placement, preventing stent-specific outcome analysis: limbs with intravascular ultrasound (IVUS)-detected iliac vein stenosis with no associated reflux ( $n = 445$ ); limbs with associated reflux confined to the superficial system ( $n = 255$ ); limbs with concurrent saphenous ablation performed along with the stenting ( $n = 366$ ); and limbs with incomplete information regarding concomitant reflux ( $n = 46$ ). Current analysis pertains to the remaining 528 stented limbs (32%) with deep venous reflux alone ( $n = 172$ ) or in combination with untreated superficial or perforator reflux ( $n = 356$ ). Iliac vein stenting was the sole corrective procedure and the reflux component was not treated.

**Indications for iliac vein stenting.** Patients with significant symptoms of pain (visual analog scale [VAS]  $\geq 5/10$ ), marked swelling, stasis skin changes including ulcers, or combinations of signs and symptoms unresponsive to conservative measures were considered for iliac vein stenting. As a tertiary referral center, most patients had been under the care of other physicians before referral for persistent symptoms and treated conservatively, including compression therapy.

**Clinical assessment.** The study endpoint of legs with stasis ulceration was complete epithelialization. Primary nonhealing ulcers were marked as such and censored at 4 months. Any breakdown of an ulcer after healing was considered a recurrence. The degree of pain was evaluated perioperatively using a VAS from 0-10, wherein 10 is the most severe pain.<sup>11</sup> Swelling was assessed as grade 0 (absent); grade 1 (pitting, not obvious); grade 2 (visible ankle edema); and grade 3 (massive, encompassing the entire leg). Patients were asked to fill out a health-related quality of life (QoL) questionnaire (CIVIQ) assessing subjective leg pain, leg symptoms affecting sleep, work, morale, and social activities before intervention, and again at each subsequent postoperative visit. The CIVIQ form has a proven specificity and relevance to chronic venous disease.<sup>12</sup> The last available clinical evaluation was used in postoperative outcome analysis.

**Investigations.** Preoperative investigations included duplex examination, arm/foot venous pressure test,<sup>13</sup> ambulatory venous pressure (AVP) measurement, percentage drop, venous filling time (VFT), air plethysmography (venous filling index [VFI<sub>90</sub>, mL/second]), and ascending and transfemoral venography with exercise femoral pressure measurements.<sup>14</sup> Tests were performed through the same venous access, if possible, to minimize venipunctures. An IVUS examination was the definitive diagnostic test and was also essential in guiding the stent placement. IVUS makes it possible to accurately identify the degree of stenosis and extent of the lesion by using incorporated software to use planimetry to measure lumen size and allows calculation of the cross-cut area stenosis. Intraluminal lesions, outside compression, and wall thickness can be better shown by IVUS than venography (Fig 1).<sup>15</sup>

**Technique.** When an iliac vein stenosis was confirmed by IVUS, iliac vein stenting was carried out concurrently. Details of work-up, technique, and perioperative manage-



**Fig 1.** Intravascular ultrasound (IVUS) scan appearance of a post-thrombotic stenosis. Lumen compromise and wall thickness are evident. The electronic scale (graticule shown) and planimetry capabilities of IVUS instrumentation allow accurate assessment of diffuse and focal stenoses.

ment including anticoagulation have been described in detail before.<sup>16-19</sup> The procedure is performed under general anesthesia for secure cardiopulmonary control in the elderly subset and to avoid the pain and discomfort often associated with iliac vein balloon dilatation. Use of large-caliber (14-18 mm) stents, stent coverage of all lesions without skip areas, 3 to 5 cm extension of braided iliac stents into inferior vena cava, and extension below the inguinal ligament, as necessary, are essential technical elements for a successful outcome. Wallstents (Boston Scientific, Nantucket, Mass) were used exclusively. Patients were discharged after an overnight hospital stay.

**Follow-up.** Patients were clinically examined at 6 weeks, 3 months, 9 months, and then annually. Stent patency was established by venography at 3 to 6 months and yearly thereafter. Duplex ultrasound scanning has been used in the last 5 years for more frequent stent surveillance.<sup>20</sup> When severe in-stent restenosis ( $>50\%$ ) was found during routine surveillance or the clinical response to the initial stenting was unsatisfactory, IVUS was repeated and the underlying malfunction was corrected when identified.<sup>21</sup> Reintervention was performed in 20% (17% of limbs with primary and 23% in limbs with post-thrombotic disease). Stent malfunction was due to thrombus layering within the stent, in-stent restenosis or stent compression, previously missed or new stenosis cephalad, or caudad to the stent, as described in a previous study.<sup>21</sup> Since the last postoperative response was used in follow-up, the effect of the reinterventions is incorporated in the cumulative stent and clinical outcome.

**Table I.** CEAP classification of 528 stented limbs

CEAP	n	(%)
Clinical class:		
2 (Varicose veins, pain $\geq 5$ VAS)	20	(4%)
3 (Venous edema)	232	(44%)
4a (Dermatitis, hyperpigmentation)	74	(14%)
4b (Lipodermatosclerosis, white scar)	33	(6%)
5 (Healed ulcer)	36	(7%)
6 (Active ulcer)	133	(25%)
Etiology:		
Primary	196	(37%)
Primary/secondary	47	(9%)
Secondary	285	(54%)
Anatomy:		
Deep	164	(31%)
Deep/perforator	21	(4%)
Deep/superficial	238	(45%)
Deep/superficial/perforator	105	(20%)
Pathology:		
Obstruction/reflux	528	(100%)

VAS, Visual analog scale.

**Data analysis.** Data were extracted from electronic medical records that were contemporaneously created during clinical evaluation. Continuous and categorical variables were analyzed by paired nonparametric Wilcoxon-Rank test and  $\chi^2$  test, respectively. Secondary patency rates and clinical outcomes were calculated using cumulative analysis with the Kaplan-Meier method. These curves were pruned at SEM  $>10\%$ . Log-rank test was used to compare cumulative curves. A commercially available statistical program (Graph Pad Prism for Windows, v 3.0; Graphpad Software Inc, La Jolla, Calif) was used for analysis.  $P < .05$  was considered significant. The number of subjects for individual parameters varies as shown because of lack of follow-up, test not performed due to technical difficulties, or refusal to have the test, etc. Institutional Review Board (IRB) permission was not required as retrospective analysis of clinical record data is presented in anonymous fashion.

## RESULTS

IVUS-guided iliac vein stenting was performed in 504 patients (median 55 years; range, 15-87; male/female ratio was 2:3). Bilateral disease was treated in 24 patients; thus, 528 limbs were included in the study (left/right limb ratio was 2:1; primary, post-thrombotic and combined etiology in 196 [37%], 285 [54%], and 47 [9%], respectively). CEAP classification of the treated limbs is shown in Table I.<sup>22</sup> All had advanced CVI symptoms, 96% were C-class of CEAP  $\geq 3$ , and 25% of limbs had active venous ulceration. The indication for stenting in C<sub>2</sub> limbs (4%) was complaint of significant leg pain (VAS  $\geq 5/10$ ) requiring narcotics for control. The median duration of symptoms before stenting was 36 months (range, 6-360).

Details of reflux present in stented limbs are shown in Table II. All patients had deep reflux, which was combined with superficial reflux in 65% and perforator reflux in 24% of limbs. The rate of different reflux patterns is given in Table I

**Table II.** Reflux details in 528 stented limbs

Type of reflux	Number of limbs	Prevalence (%)
Deep reflux alone	172	33%
+ Superficial reflux	343	65%
+ Perforator reflux	100	24%
Axial deep reflux	224	42%
Reflux multisegment score*	1: 107	20%
	2: 112	21%
	3: 140	27%
	4: 88	17%
	5: 52	10%
	6: 23	4%
	7: 6	1%

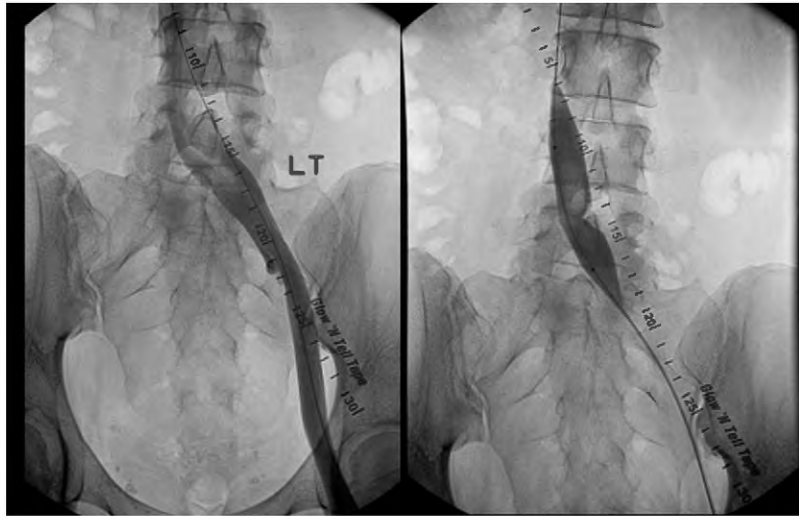
\*Reflux in the great saphenous vein (GSV) above the knee, GSV below the knee, small saphenous vein, perforators, femoral vein, profunda femoris, and popliteal vein are each given a score of 1. The total reflux score for the limb is calculated (maximum 7).

**Table III.** Tests suggestive of iliac venous obstruction leading to intravascular ultrasound (IVUS) investigation and stent placement

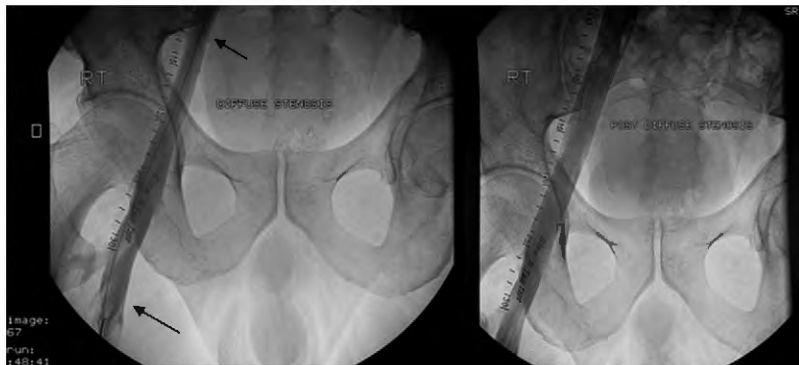
	Number of tested limbs	% positive
Transfemoral antegrade venography:		
Lesion present	245/386	(63%)
Collaterals visualized	165/382	(43%)
Femoral vein pressures:		
$\geq 3$ -mm Hg gradient over contralateral limb	20/133	(15%)
$\geq 4$ -mm Hg elevation with exercise	92/175	(53%)
Arm/foot pressure difference $\geq 4$ -mm Hg at rest	37/228	(16%)
Reactive hyperemia $\geq 6$ -mm Hg at rest	125/224	(56%)
Lack of phasicity on Doppler scan study of the common femoral vein	250/423	(59%)

(“A” of CEAP). Global reflux was severe in 309/528 limbs (59%) with reflux segment score  $\geq 3$ , and 224/528 (42%) limbs had deep axial reflux.

The indications to perform exploration with IVUS were several (Table III). Venography findings suggesting iliac vein obstruction included lesions such as webs, “pan caking”, or translucency at compression points, and obvious focal or diffuse stenosis (Figs 2 and 3).<sup>6</sup> These were found in 245/386 (63%) of treated limbs, and collaterals were visualized in 165/382 (43%). The venography was unrevealing (“normal”) in 141/386 (37%) limbs. Indirect evidence of obstruction such as obstructive flow pattern on Doppler scan investigations of the common femoral vein or at least one abnormal pressure study (femoral vein pressure, arm/foot pressure difference, and/or reactive hyperemia pressure augmentation) was present in 403/528 (76%) limbs prior to IVUS/stenting. Neither venography nor venous testing was indicative of iliac vein obstruction in 94/497 (19%) of limbs. IVUS was the only diagnostic test performed prior to stenting in 31/528 (6%), since other tests were excluded due to clinical or technical considerations.



**Fig 2.** Transfemoral antegrade venogram in a limb with a primary obstructive lesion. A translucent slight broadening of the iliac-caval junction can be noted on close inspection, but the venogram appears otherwise unremarkable (left). An obstructive lesion was obvious on intravascular ultrasound (IVUS) examination. Subsequent balloon dilatation prior to stenting shows tight focal “waisting” (right).



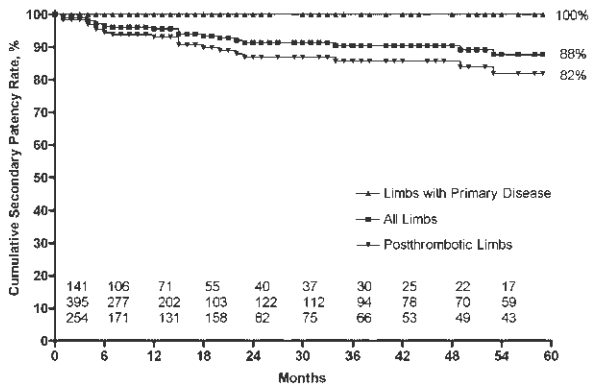
**Fig 3.** Diffuse post-thrombotic iliac vein stenoses occur from a constricting perivenous fibrotic sheath that prevents collateral formation as originally described by Rokitanski. Such lesions are easily overlooked on venography. Close inspection in this instance shows an iliac vein that is substantially more narrowed as compared to the femoral vein as highlighted by arrows (left). A uniform diameter of the vein is achieved after iliac vein stent placement (right).

Area stenosis (IVUS planimetry, mean  $\pm$  SD) was  $74\% \pm 22$ ; significantly worse ( $P < .001$ ) in post-thrombotic limbs ( $80\% \pm 22$ ) compared to that in primary disease ( $65\% \pm 20$ ;  $80\% \pm 22$ ). A total of 72% of limbs had the upper stent placed approximately 3 cm into the inferior vena cava for technical reasons, as previously described.<sup>16</sup> The upper end of the stent system was placed even higher up to correct associated caval stenosis in 19% and was limited to the common iliac vein (CIV) in 9% of limbs. The lower end of the stent was placed in the CIV, external iliac vein, common femoral vein, and profunda femoris vein in 9%, 15%, 75%, and 1% of limbs, respectively. Thus, the majority of patients had the entire ilio-common femoral vein segment covered by stent.

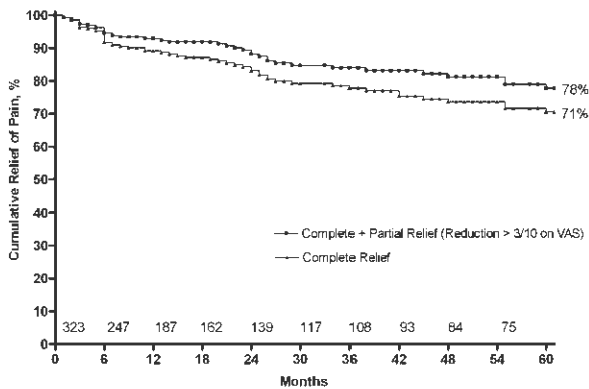
Follow-up data were available in 488/528 (92%) limbs with a median follow-up of 17 months (range, 1-145). No

mortality occurred ( $<30$  days). Early deep venous thrombosis ( $<30$  days) developed in 11 limbs (2%; 9 ipsilateral limbs, all involving the stent, and 2 contralateral limbs). Despite reintervention, the stented vein remained occluded in 29 post-thrombotic limbs. No occlusion was seen in limbs stented for primary disease. Cumulative secondary stent patency rate for all limbs at 5 years was 88% (Fig 4). It was greater for stented limbs with primary as compared to post-thrombotic disease (100% and 82%, respectively;  $P = .0002$ ).

Cumulative rates of symptom relief following stent placement are shown in Figs 5 and 6. Significant cumulative improvement of pain and swelling at 5 years was 78% and 55%, respectively; complete relief was 71% and 36%, respectively. No difference was observed between limbs with nonthrombotic and post-thrombotic obstruction ( $P =$



**Fig 4.** Cumulative secondary stent patency in 395 limbs with combined obstruction and reflux. Separate cumulative curves are shown for primary, post-thrombotic, and combined etiologies (SEM <10%).

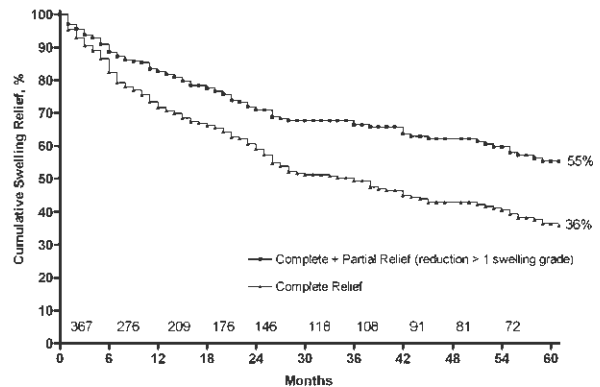


**Fig 5.** Cumulative rate of pain relief after stent placement in 323 patients complaining of pain prior to treatment. Curves representing limbs with complete relief (no residual pain) and limbs with substantial improvement are given (SEM <10%). VAS, Visual analog scale.

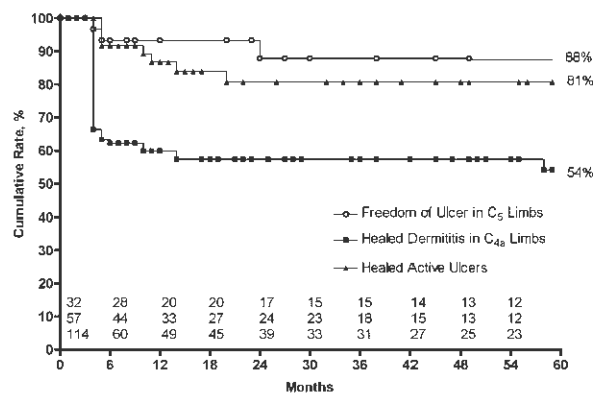
.465), limbs with severe ( $\geq 3$  reflux multisegment score) and moderate reflux ( $< 3$  reflux multisegment score;  $P = .341$ ) or limbs with axial and nonaxial reflux ( $P = .905$ ). Similarly, the cumulative rate of swelling relief was not significantly different in limbs with nonthrombotic and post-thrombotic disease ( $P = .378$ ), limbs with severe and moderate reflux ( $P = .326$ ), or limbs with axial reflux as compared to limbs with segmental reflux ( $P = .114$ ).

The effect on recurrence of ulcer in limbs with healed ( $C_5$ ) or active ulcer ( $C_6$ ) or dermatitis ( $C_{4a}$ ) at the time of stenting is shown in Fig 7. The cumulative rates of healing of active ulcer and continued freedom of ulcer in  $C_5$ -limbs were 54% and 88%, respectively, at 5 years. The cumulative rate of healed dermatitis was 81% at 5 years.

Quality of life questionnaires were completed by 395 patients prior to stenting, but collected post-stenting in only 179 patients because the assessment was introduced late in our database. Thus scores from 179 patients were



**Fig 6.** Cumulative rate of swelling relief after stent placement in 367 patients complaining of swelling prior to treatment. Curves representing limbs with complete relief (no residual swelling) and substantial improvement are given (SEM <10%).



**Fig 7.** Cumulative rates of ulcer-free  $C_5$  limbs (ie, limbs with healed ulcers at the time of stenting,  $n = 32$ ), dermatitis-free  $C_{4a}$  limbs (limbs with active dermatitis at the time of stenting,  $n = 57$ ), and healed ulcers in  $C_6$  limbs (limbs with active ulcer at the time of stenting,  $n = 114$ ; SEM <10%). A grace period of 4 months for initial healing of limbs with active leg ulcer was allowed at which time limbs with unhealed ulcers were censored. Similarly, a 5-month grace period was given for dermatitis to heal before the limbs with on-going dermatitis were censored. This explains the drop of the curves at 4 and 5 months (33% and 8%, respectively).

available for comparison pre- as compared to post-stenting. There was a significant improvement of all five CIVIQ categories (Table IV). The median pre-stent scores were the same in the subset of 179 limbs as compared to all 395 patients assessed pre-stenting.

Reflux parameters were assessed in more than 400 limbs prior to stenting, but available after stenting in only 134 to 226 limbs depending on parameter. The median values of AVP, VFT, and  $VFI_{90}$  in limbs with data available before and after stenting are shown in Table V. The median pre-stent values were the same in the subset of limbs as compared to all limbs assessed pre-stenting.

Open valve reconstruction procedures were carried out in 24 limbs (5%) in this series after the iliac vein stent

**Table IV.** Comparison of the scoring of quality of life according to the CIVIQ questionnaire in 179 patients assessed before and after stenting (median [range]; paired, nonparametric test)

<i>CIVIQ</i> categories	<i>Pre-stent</i>	<i>Post-stent</i>	<i>P value</i>
Pain	4 (1-5)	3 (1-5)	< .0001*
Work	4 (1-5)	3 (1-5)	< .0001*
Sleep	3 (1-5)	2 (1-5)	.0002*
Social	3.3 (1-5)	2.6 (1-5)	< .0001*
Morale	2.9 (1-5)	2.6 (1-5)	.0029*
Total	68 (20-100)	53 (20-100)	< .0001*

\*There was a significant improvement in all five categories.

**Table V.** Comparison of reflux measurements performed before and after iliac venous stent placement (median [range]; paired, nonparametric test)

	<i>n</i>	<i>Pre-stent</i>	<i>Post-stent</i>	<i>P value</i>
AVP, % drop	136	62 (0-100)	64 (19-100)	0.23
VFT, second	134	16 (1-123)	18 (2-160)	0.96
VFI <sub>90</sub> , mL/second	226	2.8 (0-16.6)	2.2 (0-14.1)	0.02*

*n*, Number; *AVP*, ambulatory venous pressure; *VFT*, venous filling time; *VFI<sub>90</sub>*, venous filling time.

\*Significant.

procedure failed to relieve symptoms. No venovenous bypass procedures were performed.

## DISCUSSION

This study suggests that iliac venous stenting alone significantly improved the clinical outcome in patients with combined iliac venous outflow obstruction and deep venous reflux even though the deep reflux component was left uncorrected. Stenting was safely performed with low morbidity and excellent long-term patency. Improvement of the pain was durable over the 5-year observation period, but the control of leg swelling was less effective. Limb swelling is the most difficult of venous symptoms to cure and is generally well tolerated if there is no associated pain. More than half of the patients with ulcers remained healed after 5 years. Patients treated because of previous leg ulcer, but healed at the time of stenting, and those with leg dermatitis had low cumulative recurrence rates at 5 years (12% and 19%, respectively). The patients' QoL significantly improved. This unexpected impact by stenting alone in these limbs with advanced chronic venous disease (CVD) and uncorrected remaining deep reflux suggests that, first, stenting alone is sufficient to control symptoms in the majority of patients with deep reflux, and secondly, that partial correction of the pathophysiology in limbs with multisystem disease can provide substantial symptom relief.

Valve incompetence, especially deep venous reflux, is often found in patients resistant to conservative therapy. The prevailing clinical practice is to address this reflux component. Ulcer healing and substantial improvement of symptoms have been clearly documented to occur when

underlying deep reflux is corrected.<sup>23,24</sup> Several reports suggest, however, that an obstructive component is also commonly present in limbs with CVI of both post-thrombotic and nonthrombotic etiology.<sup>5,6,17,25,26</sup> In limbs with primary nonthrombotic disease, the obstructive lesions occur at arterial crossover points, not only at the "classic" proximal location as previously known,<sup>27-29</sup> but commonly also at distal locations at the hypogastric artery crossing and behind the inguinal ligament.<sup>6,30</sup> This explains the frequent stenting of the entire iliofemoral vein segment in this study (76%). These so-called nonthrombotic iliac vein lesions (NIVLs) are found on both sides, in both genders, and in all age groups. The pathologic significance of the lesions has been debated for a long time, as varying degrees of NIVLs are present in two-thirds of the general population in silent form.<sup>4</sup> It has been suggested that NIVLs play a silent "permissive" role that precipitates symptoms only with additional insult such as development of reflux.<sup>6</sup> The favorable clinical outcome of stent correction suggests that the NIVL lesion contributes to the underlying pathophysiology. In post-thrombotic disease, the obstructive lesions are typically segmental with focal accentuations at compression points across the iliac vein.<sup>28</sup> In multilevel post-thrombotic obstruction, iliac vein lesions are the key pathology as infrainguinal obstructions are well tolerated due to adequate collateralization.<sup>31-33</sup>

The obstructive component is seldom investigated in clinical practice today since the main tool for diagnosis is an infrainguinal ultrasound scan. The pelvic outflow is rarely routinely investigated. It is important to consider obstruction as a contributing factor in all patients with symptomatic CVI, even those of primary etiology where deep reflux may be obvious and obstruction is not apparent. It is not known at what degree a venous stenosis becomes critical, and accurate noninvasive or invasive hemodynamic tests are, therefore, not available. A positive test supports further investigations, but a negative cannot exclude the presence of a significant obstruction. The diagnosis of occlusive or nonocclusive obstruction is, therefore, based on morphologic studies (>50% stenosis is considered significant, and this degree is arbitrarily chosen based on clinical outcome).

Since ultrasound scanning of the pelvic outflow is suboptimal in the detection of obstruction, additional studies, such as transfemoral venography, magnetic resonance (MR-) or computed tomography (CT)-venography, may be performed in patients with severe chronic venous disease. Contrast venography is poor in detecting pathologically important iliac vein lesions. Ascending venography using a dorsal foot vein often does not yield adequate opacification for proper iliac vein assessment. Transfemoral venography is required. Routine radiologic interpretation is often cursory ("iliac veins are patent"), unless obvious webs or obstruction are present. Some radiologic texts even indicate that the presence of transpelvic collaterals is a "normal anatomic variant". Venographic indications of iliac vein lesions are often subtle and require a high index of suspicion for proper identification of obstruction. Even given the observer bias of the authors, venography was

suspicious of a culprit iliac vein lesion in only 63% of limbs with collaterals being present only in 43% of limbs. The ultimate arbitrator is IVUS and a readiness to use this tool is required. IVUS has excellent sensitivity (90%) to detect iliac vein obstruction.<sup>5,6,15</sup> Because of the high diagnostic yield of IVUS in severely symptomatic patients, it should be used routinely even if venography is negative for obstruction. Venography preceding IVUS is still valuable as it detects collateral formation, better visualizes the continuous outflow, and provides a helpful “road map” for the stenting procedure. When IVUS has detected a significant obstruction, stent placement is conveniently combined with the diagnostic procedure with prior consent. The sensitivity to detect venous obstruction of high-resolution imaging techniques (MR-venography and CT-venography) is unknown, although initial reports are promising.

Symptom relief with partial correction of multisystem or multilevel venous pathology utilizing a variety of corrective techniques, other than stenting, has been well documented.<sup>34-38</sup> Ulcer healing and substantial improvement of symptoms have been reported after repair of the deep valves alone in complex venous pathology.<sup>23,24,31,39,40</sup> In this report, clinical outcome of stenting without correction of associated deep reflux, which was severe in the majority of stented limbs, was substantial and durable. Healing of stasis ulceration after stenting in the presence of deep reflux was the most surprising finding. Prevailing concept imputes ulcer formation to reflux, not obstruction. This study suggests that obstruction also plays a role and correction of either component (partial correction) can afford relief. With currently available technology, it is far easier to correct obstruction than deep reflux. The techniques available for open repair of the deep valves have not been widely adopted because of their complexity.

Minimally invasive interventions that are safe and efficacious have evolved to correct all of the pathologic components of CVI except deep venous reflux. These new interventions in combination with the lack of tests, which are available to assess the contribution of each refluxing or obstructive vein segment to the global hemodynamics, have changed the therapeutic approach. Since partial correction of the venous pathology may result in substantial improvement or complete relief of symptoms, a stepwise correction of pathology may be applied using initially minimally-invasive techniques. The current report suggests that deep reflux can be initially ignored if it is combined with iliac vein obstruction, which can be relieved by stent placement. Complex open surgeries to correct obstruction or reflux are only performed when percutaneous treatment fails and should be required infrequently (in this study, in only 5% of stented limbs).

#### AUTHOR CONTRIBUTIONS

Conception and design: SR, PN  
Analysis and interpretation: SR, PN  
Data collection: RD, SR, PN  
Writing the article: SR, PN  
Critical revision of the article: SR, PN  
Final approval of the article: SR, PN

Statistical analysis: RD, PN, SR  
Obtained funding: Not applicable  
Overall responsibility: SR

#### REFERENCES

1. Palma EC, Esperon R. [Treatment of the post-thrombophlebitic syndrome by means of internal saphenous transplants.] [Article in Spanish] *Bol Soc Cir Urug* 1959;30:115-25.
2. Taheri SA, Williams J, Powell S, Cullen J, Peer R, Nowakowski P, et al. Iliacaval compression syndrome. *Am J Surg* 1987;154:169-72.
3. Harris JP, Kidd J, Burnett A, Halliday P, May J. Patency of femoro-femoral venous crossover grafts assessed by duplex scanning and phlebography. *J Vasc Surg* 1988;8:679-82.
4. Kibbe MR, Ujiki M, Goodwin AL, Eskandari M, Yao J, Matsumura J. Iliac vein compression in an asymptomatic patient population. *J Vasc Surg* 2004;39:937-43.
5. Raju S. Endovenous treatment of patients with iliac-caval venous obstruction. *J Cardiovasc Surg (Torino)* 2008;49:27-33.
6. Raju S, Neglen P. High prevalence of nonthrombotic iliac vein lesions in chronic venous disease: a permissive role in pathogenicity. *J Vasc Surg* 2006;44:136-43; discussion 144.
7. Hartung O, Loundou AD, Barthelemy P, Arnoux D, Boufi M, Alimi YS. Endovascular management of chronic disabling ilio-caval obstructive lesions: long-term results. *Eur J Vasc Endovasc Surg* 2009;38:118-24.
8. Knipp BS, Ferguson E, Williams DM, Dasika NJ, Cwikiel W, Henke PK, Wakefield TW. Factors associated with outcome after interventional treatment of symptomatic iliac vein compression syndrome. *J Vasc Surg* 2007;46:743-9.
9. O'Sullivan GJ, Semba CP, Bittner CA, Kee ST, Razavi MK, Sze DY, Dake MD. Endovascular management of iliac vein compression (May-Thurner) syndrome. *J Vasc Interv Radiol* 2000;11:823-36.
10. Oguzkurt L, Tercan F, Ozkan U, Gulcan O. Iliac vein compression syndrome: outcome of endovascular treatment with long-term follow-up. *Eur J Radiol* 2008;68:487-92.
11. Scott J, Huskisson EC. Graphic representation of pain. *Pain* 1976;2:175-84.
12. Launois R, Reboul-Marty J, Henry B. Construction and validation of a quality of life questionnaire in chronic lower limb venous insufficiency (CIVIQ). *Qual Life Res* 1996;5:539-54.
13. Neglén P, Raju S. Detection of outflow obstruction in chronic venous insufficiency. *J Vasc Surg* 1993;17:583-9.
14. Negus D, Cockett FB. Femoral vein pressures in post-phlebotic iliac vein obstruction. *Br J Surg* 1967;54:522-5.
15. Neglén P, Raju S. Intravascular ultrasound scan evaluation of the obstructed vein. *J Vasc Surg* 2002;35:694-700.
16. Neglén P, Berry MA, Raju S. Endovascular surgery in the treatment of chronic primary and post-thrombotic iliac vein obstruction. *Eur J Vasc Endovasc Surg* 2000;20:560-71.
17. Neglén P, Hollis KC, Olivier J, Raju S. Stenting of the venous outflow in chronic venous disease: long-term stent-related outcome, clinical, and hemodynamic result. *J Vasc Surg* 2007;46:979-90.
18. Neglén P, Raju S. Balloon dilation and stenting of chronic iliac vein obstruction: technical aspects and early clinical outcome. *J Endovasc Ther* 2000;7:79-91.
19. Raju S, Neglén P. Percutaneous recanalization of total occlusions of the iliac vein. *J Vasc Surg* 2009;30:360-8.
20. Labropoulos N, Borge M, Pierce K, Pappas PJ. Criteria for defining significant central vein stenosis with duplex ultrasound. *J Vasc Surg* 2007;46:101-7.
21. Raju S, Tackett P Jr, Neglén P. Reinterventions for nonocclusive iliofemoral venous stent malfunctions. *J Vasc Surg* 2009;49:511-8.
22. Eklöf B, Rutherford RB, Bergan JJ, Carpentier PH, Gloviczki P, Kistner RL, et al. Revision of the CEAP classification for chronic venous disorders: consensus statement. *J Vasc Surg* 2004;40:1248-52.
23. Masuda EM, Kistner RL. Long-term results of venous valve reconstruction: a four- to twenty-one-year follow-up. *J Vasc Surg* 1994;19:391-403.
24. Raju S, Neglén P. Clinical practice. Chronic venous insufficiency and varicose veins. *N Engl J Med* 2009;360:2319-27.

25. Neglén P, Thrasher TL, Raju S. Venous outflow obstruction: an underestimated contributor to chronic venous disease. *J Vasc Surg* 2003;38:879-85.
26. Johnson BF, Manzo RA, Bergelin RO, Strandness DE Jr. Relationship between changes in the deep venous system and the development of the postthrombotic syndrome after an acute episode of lower limb deep vein thrombosis: a one- to six-year follow-up. *J Vasc Surg* 1995;21:307-12; discussion 313.
27. Cockett FB, Thomas ML. The iliac compression syndrome. *Br J Surg* 1965;52:816-21.
28. Cockett FB, Thomas ML, Negus D. Iliac vein compression. Its relation to iliofemoral thrombosis and the post-thrombotic syndrome. *Br Med J* 1967;2:14-9.
29. May R, Thurner J. The cause of the predominantly sinistral occurrence of thrombosis of the pelvic veins. *Angiology* 1957;8:419-27.
30. Neglén P, Tackett TP Jr, Raju S. Venous stenting across the inguinal ligament. *J Vasc Surg* 2008;48:1255-61.
31. Raju S, Fountain T, Neglén P, Devidas M. Axial transformation of the profunda femoris vein. *J Vasc Surg* 1998;27:651-9.
32. Raju S, Fredericks R. Venous obstruction: an analysis of one hundred thirty-seven cases with hemodynamic, venographic, and clinical correlations. *J Vasc Surg* 1991;14:305-13.
33. Raju S, Hollis K, Neglén P. Obstructive lesions of the inferior vena cava: clinical features and endovenous treatment. *J Vasc Surg* 2006;44:820-7.
34. Barwell JR, Davies CE, Deacon J, Harvey K, Minor J, Sassano A, et al. Comparison of surgery and compression with compression alone in chronic venous ulceration (ESCHAR study): randomised controlled trial. *Lancet* 2004;363:1854-9.
35. Kalra M, Gloviczki P. Surgical treatment of venous ulcers: role of subfascial endoscopic perforator vein ligation. *Surg Clin North Am* 2003;83:671-705.
36. Nelzén O, Fransson I. True long-term healing and recurrence of venous leg ulcers following SEPS combined with superficial venous surgery: a prospective study. *Eur J Vasc Endovasc Surg* 2007;34:605-12.
37. Raju S, Fredericks RK, Neglén PN, Bass JD. Durability of venous valve reconstruction techniques for "primary" and postthrombotic reflux. *J Vasc Surg* 1996;23:357-66; discussion 366-7.
38. Raju S, Hardy JD. Technical options in venous valve reconstruction. *Am J Surg* 1997;173:301-7.
39. Perrin M. Reconstructive surgery for deep venous reflux: a report on 144 cases. *Cardiovasc Surg* 2000;8:246-55.
40. Raju S, Neglén P, Doolittle J, Meydrech EF. Axillary vein transfer in trabeculated postthrombotic veins. *J Vasc Surg* 1999;29:1050-62; discussion 1062-4.

Submitted Jun 8, 2009; accepted Aug 14, 2009.

## DISCUSSION

**Dr Harry Schanzer** (*New York, NY*). The paper just presented by Dr Raju et al is extremely important because it challenges all the previous concepts of pathogenesis and treatment of chronic venous insufficiency. Dr Raju, you have really put upside down all our previous notions of venous disease. I have carefully followed your experience over the years. Initially, you reported excellent results with valvular reconstruction even in the setting of postphlebetic syndrome. Later on, you reported improved results with iliac vein stenting in the postphlebetic syndrome, and now you are presenting us with the treatment of primary valvular venous insufficiency by iliac vein stenting. This, if true, is really a revolutionary change in the conceptual understanding of the pathogenesis of CVI and its treatment. I have two questions with regards to your experience.

The first one is: you reported 90% of patients with primary venous insufficiency having an obstruction of the iliac system as determined by IVUS. I would like to know how significant is this obstruction? In a control population with no CVI, how often would you have these IVUS findings? How significant is this finding?

The second question is: is there any additional therapy that you use in these patients that can confuse the results of the stenting? I specifically refer to elastic compression.

Finally, I think that it is very important to wait for corroboration of your results. These are very impressive, and if other groups can reproduce them, this will change significantly the understanding and treatment of venous insufficiency.

**Dr Raju.** It is clear from modern imaging techniques that two-thirds of the normal population have obstructive iliac vein lesions that are silent. IVUS detectable lesions are present in over 90% of patients with chronic venous disease with CEAP clinical class 3 and higher presentation. Initially, we were worried that we were treating something that is normally present; but the clinical outcome, particularly healing of stasis ulceration, suggests that the obstructive lesion is contributory to the disease process.

No new stockings are issued after stent placement. So, the reported clinical improvement is due to the stent procedure itself.

**Dr Mark Adelman** (*New York, NY*). If you would, briefly comment on your anticoagulation regimen and how you manage these stents postimplantation. I imagine most of these patients have undergone a thrombophilic evaluation. But if that workup is

negative, and they are not found to be hypercoagulable, how do you manage the anticoagulation regimen over the long term?

**Dr Raju.** If the thrombophilia is absent, they just get aspirin when they go home. If thrombophilia is present, warfarin is instituted or continued.

**Dr Rabih Chaer** (*Pittsburgh, Pa*). How do you define venous stenosis on IVUS? What is your definition of a venous stenosis in general? And what degree of stenosis do you treat with stenting?

**Dr Raju.** The normal iliac vein measures about 175 to 250 sq mm. So you can measure the area with IVUS planimetry software and compute the stenosis. Anything over 50% area stenosis appears to be clinically significant.

**Dr Peter Gloviczki** (*Rochester, Minn*). This is a tremendous experience, and as Dr Schanzer said, it changes a lot of what we know about venous disease.

When we measured 23 limbs with venous reflux, we found that it became worse in 24% after ilio caval stenting. So my question is: do you have a subgroup where you see worsening in venous reflux?

Many patients who need iliac venous stenting also have infrainguinal venous reflux or post-thrombotic obstruction. It looks like you are not recommending elastic compression after venous stenting even in this group of patients. Could you tell us why not?

**Dr Raju.** Reflux does not get worse after stenting when the data are analyzed in aggregate; in fact, there was a small but significant improvement in VFI<sub>90</sub> afterwards. We have not performed intensive subset analysis to examine if this may not be the case in some limbs.

Most patients that come to us have already gone through compression programs. In about one-third of patients, compression is not appropriate because of local condition of the limb or systemic deterrents to regular use. In others, compression is not effective or not tolerated. Noncompliance with prescribed stockings is a difficult and often incorrigible problem that we have dealt with in a separate publication. We allow patients to maintain current compression regimen (use or nonuse) without modification near term after stent placement. Long term, they are allowed to abandon stockings if it made no difference. Most patients abandon stockings entirely or limit usage to only "hard" days if clinical outcome is successful.