

Role of laser ablation in recalcitrant instent restenosis post iliofemoral venous stenting

Arjun Jayaraj, MD, Robert Fuller, MS, and Seshadri Raju, MD, Jackson, Miss

ABSTRACT

Instent restenosis (ISR) represents the most common reason for recurrent symptoms requiring reintervention in patients who have undergone venous stenting for chronic iliofemoral venous obstruction. Treatment of ISR requires stent angioplasty typically using angioplasty balloons equal to or larger than the rated diameter of the stent. At times this does not yield the required result, and in these patients, utilization of a laser catheter supported by an angled sheath is helpful to ablate the ISR or make it more amenable to repeat balloon angioplasty. The authors report their experience with this technique for 18 patients with recurrent symptoms impacting quality of life as a result of recalcitrant ISR in this retrospective review of contemporaneously entered electronic medical record data. 12 (67%) limbs underwent laser ablation only, while 6 (33%) limbs underwent additional angioplasty post laser ablation. Post intervention for ISR, at 12 months, the venous clinical severity score improved from 5 to 3.5 ($P = .0005$) and the VAS pain score went from 7 to 5 ($P = .0005$). At 10 months, primary patency was 87% and primary assisted patency was 100%. There were no stent occlusions. Laser ablation of recalcitrant instent restenosis in patients presenting with recurrent chronic iliac venous obstruction post iliofemoral venous stenting is a safe and effective option. Corroboration from larger studies is warranted. (*J Vasc Surg Cases and Innovative Techniques* 2021;7:298-301.)

Keywords: Chronic iliofemoral venous obstruction; In-stent restenosis; Laser ablation; Venous stenting

At present, venous stenting for chronic iliofemoral venous obstruction is considered the standard of care for symptomatic patients with impaired quality of life in whom conservative therapy has failed.¹⁻⁵ However, these patients have a 20% incidence of reintervention for recurrent symptoms, including in-stent restenosis (ISR), which can account for as much as 83% of total reinterventions.⁶ The treatment of ISR is angioplasty with balloons either similar to or larger than the rated diameter of the stent.⁷ Although balloon angioplasty is often successful, in some cases, the ISR lesions will not be responsive to such angioplasty. To treat such recalcitrant lesions the authors resorted to use of laser ablation of the ISR using their experience in laser recanalization of occluded venous stents as a guide. This case series describes the novel technique and the outcomes in 18 patients who underwent the procedure.

METHODS

Retrospective review of contemporaneously entered EMR data on reinterventions following initial unilateral

From The RANE Center for Venous and Lymphatic Diseases, St Dominic Hospital.

Author conflict of interest: none.

Correspondence: Arjun Jayaraj, MD, The RANE Center, St Dominic Hospital, 971 Lakeland Dr, Ste 401, Jackson, MS 39216 (e-mail: jayaraj.arjun2015@gmail.com).

The editors and reviewers of this article have no relevant financial relationships to disclose per the Journal policy that requires reviewers to decline review of any manuscript for which they may have a conflict of interest.

2468-4287

© 2021 The Author(s). Published by Elsevier Inc. on behalf of Society for Vascular Surgery. This is an open access article under the CC BY-NC-ND license (<http://creativecommons.org/licenses/by-nc-nd/4.0/>).

<https://doi.org/10.1016/j.jvscit.2021.03.004>

iliofemoral venous stenting in 578 limbs/patients over a 4-year period from 2014 to 2018 was performed. ISR was estimated from stent and flow channel diameters measured using intravascular ultrasound (IVUS). Technique of stenting and peri/post-operative care have been described in prior publications.^{5,6,8} In brief diagnosis of chronic iliofemoral venous obstruction was confirmed through IVUS interrogation (Visions PV .035 digital IVUS catheter – Philips, Amsterdam, Netherlands) using normal minimal luminal areas [common femoral (125 mm²), external iliac vein (150 mm²) and common iliac vein (200 mm²) veins].⁹ Following confirmation of diagnosis, stenting was carried out using a combination of Wallstent body and a Z stent top that straddled the ilio caval confluence in the process overcoming the choke point effect. Follow up was lifelong in the form of a combination of clinic visits with duplex ultrasound evaluation of the stent at regular intervals. Patients presenting with recurrent limb symptoms impairing quality of life on follow up were offered repeat IVUS interrogation and intervention depending of the etiology of stent malfunction. Limbs with ISR initially underwent angioplasty with balloons equal to or larger than the rated diameter of the stent (eg, a 16 mm stent would undergo angioplasty with at least a 16 mm balloon).⁷ If there was persistence of ISR (luminal areas below previously described normal) on interval IVUS interrogation or if the angioplasty was ineffective on account of lack of purchase on the stent wall (watermelon seeding of balloon) laser ablation of the ISR was performed. This was carried out using a 2.3 mm Spectranetics laser catheter (Spectranetics Corp, Colorado Springs, CO) supported by 8.5Fr, 63 cm Swartz Braided Transseptal Guiding Introducer

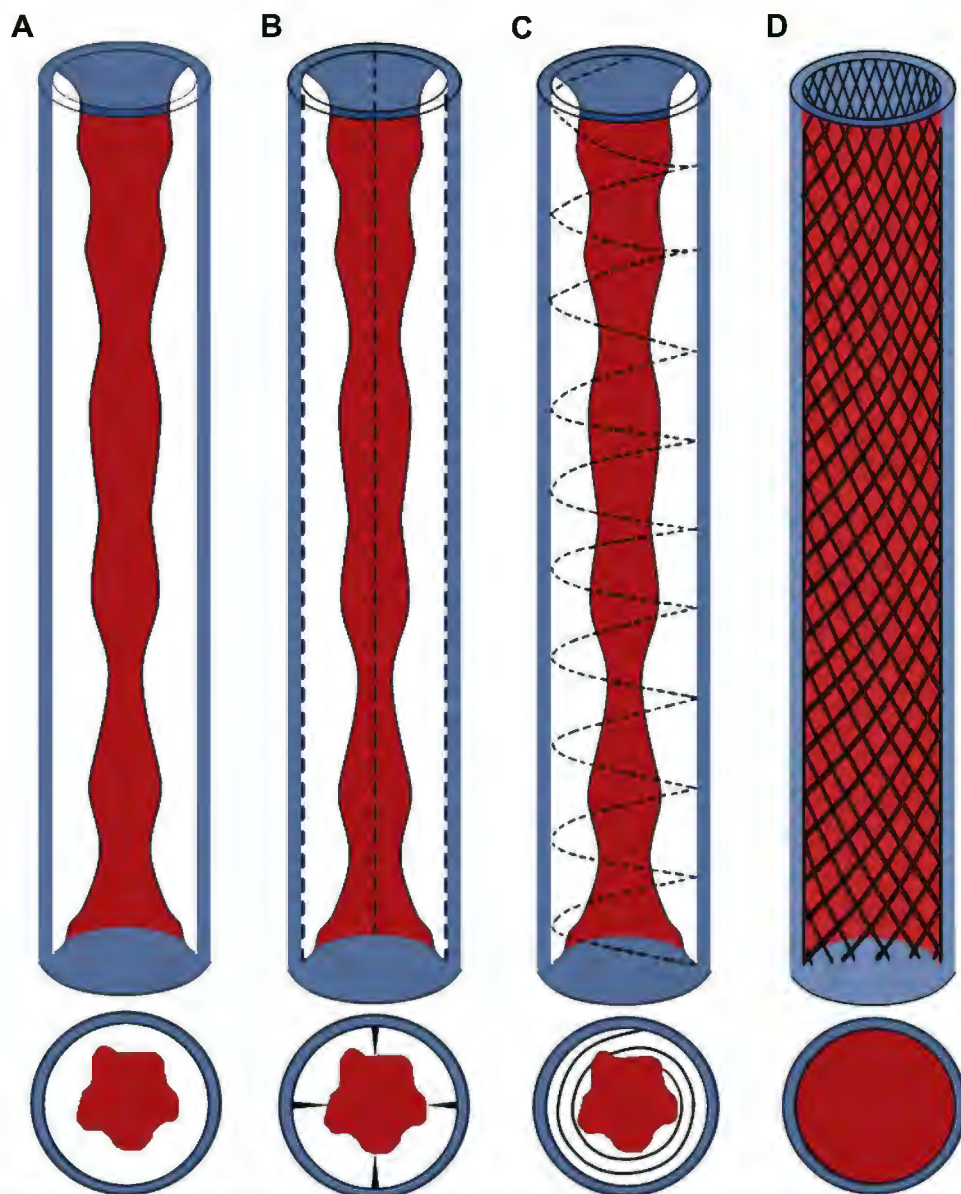


Fig 1. Diagrammatic representation of laser ablation of in-stent restenosis (ISR). **A**, Stent column with ISR. **B**, Four-quadrant laser ablation. **C**, Circumferential laser ablation. **D**, Stent column after laser ablation and balloon angioplasty.

(Abbott Labs, Abbott Park, IL). The ISR was scored in a 4-quadrant longitudinal and subsequently circumferential manner (Fig 1). Fluence for the laser was set at 60 mj/mm² and the rate at 80 pulses/second. Interval IVUS interrogation was performed to assess the result and if necessary, a repeat angioplasty was performed. The goal was to attain normal minimal luminal areas noted previously. Standard precautions for use of laser catheters were observed peri procedurally. Paired T test was used to evaluate pre- and post-outcomes including visual analog scale pain score (VAS) and the venous clinical severity score (VCSS). Mean + SD was used for normally distributed variables while median + IQR was used for

non-normally distributed variables. Stent patency post laser ablation of ISR was computed using Kaplan Meier analysis. Primary patency was defined as continued patency until the stent required a procedure for stenosis or occlusion. Continued maintenance of patency in a non-thrombosed stent was the definition used for primary assisted patency while secondary patency was defined as patency following restoration of flow in an occluded stent. "Hospital IRB approval was obtained for dissemination of deidentified patient data. Patient consent was obtained for the procedure."

The hospital institutional review board approved the present study and the use of de-identified patient data.

Table. Patient characteristics

Pt. No.	Age, years	Laterality	MTS/ PTS	CEAP class	ISR before ablation, %
1	42	Left	PTS	3	54
2	57	Right	NIVL	4	53
3	68	Right	PTS	4	49
4	52	Left	PTS	4	54
5	82	Left	PTS	3	51
6	45	Left	PTS	4	25
7	48	Left	PTS	4	50
8	55	Left	NIVL	4	37
9	56	Left	PTS	3	55
10	71	Right	PTS	4	59
11	31	Right	NIVL	4	55
12	64	Right	PTS	3	38
13	47	Right	NIVL	3	65
14	56	Left	NIVL	6	41
15	64	Left	PTS	3	41
16	45	Left	NIVL	4	36
17	62	Left	PTS	5	50
18	34	Left	NIVL	3	47

CEAP, Clinical, etiologic, anatomic, pathophysiologic; ISR, in-stent restenosis; MTS, May-Thurner syndrome; NIVL, nonthrombotic iliac vein lesion; Pt. No., patient number; PTS, post-thrombotic syndrome.

The patients provided written informed consent for the procedure.

RESULTS

Over a median follow up of 24 months, 94/578 (16.4%) limbs underwent reintervention for ISR either alone or in combination with stent compression. Stents had been placed in these patients for stenotic lesions. There were no recanalizations of chronic total occlusive lesions. Of these 94, 18 limbs (19%) underwent laser ablation of ISR. Patient characteristics are considered in Table. The median age was 56 years. Median follow up post reintervention was 19 months. While 12 (67%) limbs underwent laser ablation only, 6 (33%) limbs underwent additional angioplasty post laser ablation (Fig 2) to attain the normal minimal luminal areas. They were no major adverse events. The median number of pulses per limb was 36,198 Joules and the median laser time was 449 seconds. Post intervention for ISR, at 12 months, the VCSS score (median [IQR]) improved from 5 (4-6) to 3.5 (3-5) ($P = .0005$) and the VAS pain score (median [IQR]) went from 7 (7-8) to 5 (3-8) ($P = .0005$). At 10 months, primary stent patency was 87% and primary assisted patency was 100%. There were no stent occlusions. A total of 6/18 (33%) limbs underwent repeat intervention following laser ablation of ISR. Median time to reintervention following laser ablation was 11 months.

After intervention for ISR, at 12 months, the median venous clinical severity score had improved from 5 (IQR, 4-6) to 3.5 (IQR, 3-5; $P = .0005$) and the median visual analog scale score from 7 (IQR, 7-8) to 5 (IQR, 3-8; $P = .0005$). At 10 months, primary stent patency was 87% and primary assisted patency was 100%. No stent occlusions developed. Of the 18 limbs, 6 (33%) had required repeat intervention after laser ablation for ISR. The median time to reintervention after laser ablation was 11 months.

DISCUSSION

ISR represents the most common reason for reintervention after stenting for chronic iliofemoral venous obstruction. Most ISR lesions will be amenable to balloon angioplasty alone using an adequate caliber balloon. The length of the balloon can be a factor determining adequate purchase. Typically, a 60-mm-long balloon will be better than a 40-mm-long balloon. However, even 60 mm can be inadequate for a long-segment ISR lesion. For close to one fifth of patients undergoing reintervention for ISR, angioplasty alone will not provide an adequate result. For these patients, the use of a laser catheter to score or ablate the ISR provides an alternate technique to restore an adequate flow channel. Laser ablation will eliminate the ISR in two thirds of the limbs, enabling restoration of an adequate flow channel, and softens the residual ISR in the remaining limbs, making it more amenable to subsequent angioplasty. Either the 2.3- or 2.5-mm laser catheter can be used for this purpose. An angled sheath should be used to enable adequate scoring of the ISR. In our practice, we have found the Swartz sheath (Abbott Laboratories) to be suitable. The laser settings for the procedure are similar to those we use for laser recanalization of occluded venous stents and for laser sheaths during complex inferior vena cava filter retrieval, with the fluence set at 60 mJ/mm² and the rate set at 80 pulses/seconds. The use of laser sheaths to treat ISR represents a last resort to restore the normal minimal luminal areas after failure of conventional angioplasty. At present, alternate technology is not available to accomplish this. Restoration of the normal minimal luminal areas is imperative to ameliorate venous hypertension and restore clinical benefit. It is important to remember that flow is related to the fourth power of the radius by Poiseuille's equation:

$$\text{Flow (F)} = \frac{\text{Pressure gradient } (\Delta P)}{\text{Resistance (R)}}$$

$$F = \frac{\Delta P \pi r^4}{8L\eta}$$

where L is the length of the vein, η is the viscosity of blood, and r is the radius of the vein.

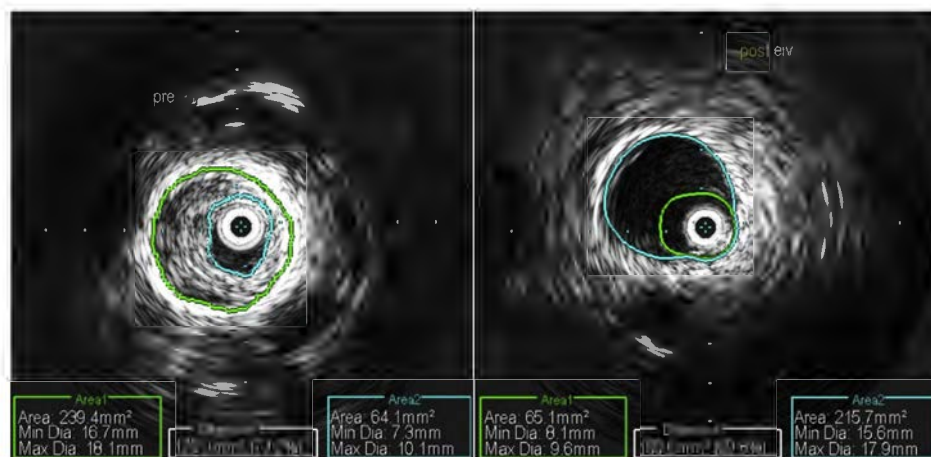


Fig 2. Intravascular ultrasound (IVUS) scans demonstrating the external iliac vein segment of the stent before (Left) and after (Right) laser ablation of in-stent restenosis (ISR).

Any reduction in the flow channel from residual ISR will decrease flow and result in persistent and/or residual venous hypertension and its clinical manifestations. Thus, it is important to restore the normal minimal luminal areas throughout the stent and not aim for a degree of luminal gain. Once this has been accomplished, good clinical outcomes and stent patency can be expected.

Study limitations. The limitations included the small, retrospective cohort nature of the study with the relatively short follow-up. A larger series would be helpful to validate our findings. Another limitation is the increased cost of using laser catheters. Additionally, the use of the laser catheter in this context represents an off-label use. Laser technology in the venous sphere is, nevertheless, here to stay. Other uses for laser catheters and sheaths include recanalization of occluded femoroiliacal stents and complex inferior vena cava filter retrieval.

CONCLUSIONS

Laser ablation of recalcitrant ISR in patients presenting with recurrent chronic iliofemoral venous obstruction after iliofemoral venous stenting is safe and effective, with good clinical and stent-related outcomes. Further study is required to corroborate these findings.

REFERENCES

1. Hartung O, Loundou AD, Barthelemy P, Arnoux D, Boufi M, Alimi YS. Endovascular management of chronic disabling ilio-caval obstructive lesions: long-term results. *Eur J Vasc Endovasc Surg* 2009;38:118-24.
2. Gutzeit A, Zollikofer Ch L, Dettling-Pizzolato M, Graf N, Largiader J, Binkert CA. Endovascular stent treatment for symptomatic benign iliofemoral venous occlusive disease: long-term results 1987-2009. *Cardiovasc Intervent Radiol* 2011;34:542-9.
3. Seager MJ, Busuttill A, Dharmarajah B, Davies AH. Editor's choice – a systematic review of endovenous stenting in chronic venous disease secondary to iliac vein obstruction. *Eur J Vasc Endovasc Surg* 2016;51:100-20.
4. Ye K, Lu X, Li W, Huang Y, Huang X, Lu M, et al. Long-term outcomes of stent placement for symptomatic nonthrombotic iliac vein compression lesions in chronic venous disease. *J Vasc Interv Radiol* 2012;23:497-502.
5. Neglen P, Hollis KC, Olivier J, Raju S. Stenting of the venous outflow in chronic venous disease: long-term stent-related outcome, clinical, and hemodynamic result. *J Vasc Surg* 2007;46:979-90.
6. Jayaraj A, Noel C, Kuykendall R, Raju S. Long-term outcomes following use of a composite Wallstent–Z stent approach to iliofemoral venous stenting. *J Vasc Surg Venous Lymphat Disord* 2021;9:393-400.e2.
7. Raju S, Knight A, Buck W, May C, Jayaraj A. Caliber-targeted reinterventional overdilation of iliac vein Wallstents. *J Vasc Surg Venous Lymphat Disord* 2019;7:184-94.
8. Jayaraj A, Buck W, Knight A, Johns B, Raju S. Impact of degree of stenosis in May-Thurner syndrome on iliac vein stenting. *J Vasc Surg Venous Lymphat Disord* 2019;7:195-202.
9. Raju S, Buck WJ, Crim W, Jayaraj A. Optimal sizing of iliac vein stents. *Phlebology* 2018;33:451-7.

Submitted Dec 19, 2020; accepted Mar 7, 2021.