

# Percutaneous laser recanalization in chronically occluded iliofemoral venous stents

Taimur Saleem, MBBS, FACS, Cooper Luke, MS, and Seshadri Raju, MD, FACS, Jackson, MS

## ABSTRACT

Occlusion is a challenging complication of endovenous stenting. The treatment of chronic iliofemoral stent occlusion involves wire recanalization followed by balloon angioplasty. However, this approach will not always be successful. To treat such cases, we have successfully used a laser recanalization technique in 34 limbs (31 patients). This technique involved the use of a laser to first create a channel through the chronically occluded stent, followed by balloon angioplasty to improve the caliber of this recanalized tract. The mean age of the patients was  $52 \pm 13.6$  years (range, 24-73 years). No adverse events related to the use of the laser occurred. Following laser recanalization, the venous clinical severity score had improved from  $8.2 \pm 4$  to  $5.1 \pm 3.3$  ( $P < .0001$ ). The visual analog scale score for pain had improved from  $7.8 \pm 2.5$  to  $4.9 \pm 3$  ( $P = .0009$ ). The grade of swelling had improved from  $2.7 \pm 1.3$  to  $1.6 \pm 1.4$  ( $P = .0001$ ). At 12 months after intervention, the primary stent patency was 60% (standard error of the mean, 9.3%), and the secondary stent patency was 80%. Excimer laser recanalization of chronically occluded venous stents appears to be a rarely required but useful modality with reasonable clinical outcomes. Further reinterventions might be required to maintain long-term stent patency. (*J Vasc Surg Cases Innov Tech* 2022;8:399-403.)

**Keywords:** Balloon angioplasty; Chronic iliofemoral venous stent occlusion; In-stent restenosis; Laser recanalization; Venous stenting

Endovascular venous stenting has been increasingly used to alleviate symptoms resulting from chronic iliofemoral venous obstruction for patients for whom conservative therapy has failed.<sup>1</sup> One difficult complication of such stenting is occlusion. This occlusion can be acute (<30 days; 31%) or chronic (>30 days; 69%).<sup>2</sup> The treatment of acute stent occlusion involves thrombectomy with or without balloon maceration of thrombus. In contrast, the treatment of chronic iliofemoral stent occlusion involves wire recanalization with balloon angioplasty.<sup>2</sup> However, in a subset of patients, this primary approach by itself might not be successful in the recanalization of chronically occluded venous stents. To treat such cases, we have used a laser recanalization technique. This technique involved the use of a laser to first create a channel through the chronically occluded stent, followed by balloon angioplasty to improve the caliber of this recanalized tract. In the present report, we have described this technique of laser recanalization and the

associated clinical outcomes for 34 limbs (31 patients) that had undergone this procedure.

## METHODS

From January 2016 to December 2020, the records of all consecutive patients for whom laser had been successfully used to cross a chronic total venous stent occlusion (CTVSO) were retrospectively reviewed. The diagnosis of CTVSO was determined from either the duplex ultrasound, computed tomography venography, or magnetic resonance venography findings. Recanalization was offered to patients with CTVSO for whom the symptoms were severe enough to affect their quality of life and for whom conservative therapy of  $\geq 3$  to 6 months had failed. In all symptomatic patients with CTVSO, initial wire recanalization was attempted (Fig 1). Access was obtained via a mid- or lower thigh femoral vein. For some patients, access via the profunda, popliteal, or internal jugular veins was obtained if femoral venous access was not successful owing to severe post-thrombotic disease. Wire recanalization of the occluded stent involved the use of a 0.035-in. Glidewire braced by a support catheter such as the angled tip Glidewire (Terumo Medical Corp, Somerset, NJ) or Quick-Cross catheter (Spectranetics Corp, Colorado Springs, CO).<sup>2</sup> If this primary technique was unsuccessful, we resorted to the use of a laser to cross the CTVSO. Given its superiority over venography,<sup>3-5</sup> intravascular ultrasound (IVUS; Visions PV 0.035 digital IVUS catheter; Philips, Amsterdam, Netherlands) was used at regular intervals to confirm that the trajectory of the laser was internal to the stent interstices. Once the terminal portion of the stent had been engaged (Fig 2, A) in the common femoral vein segment, laser recanalization

From The RANE Center for Venous and Lymphatic Diseases.

Author conflict of interest: S.R. has a U.S. patent for IVUS diagnostics and for an iliac vein stent design. T.S. and C.L. have no conflicts of interest.

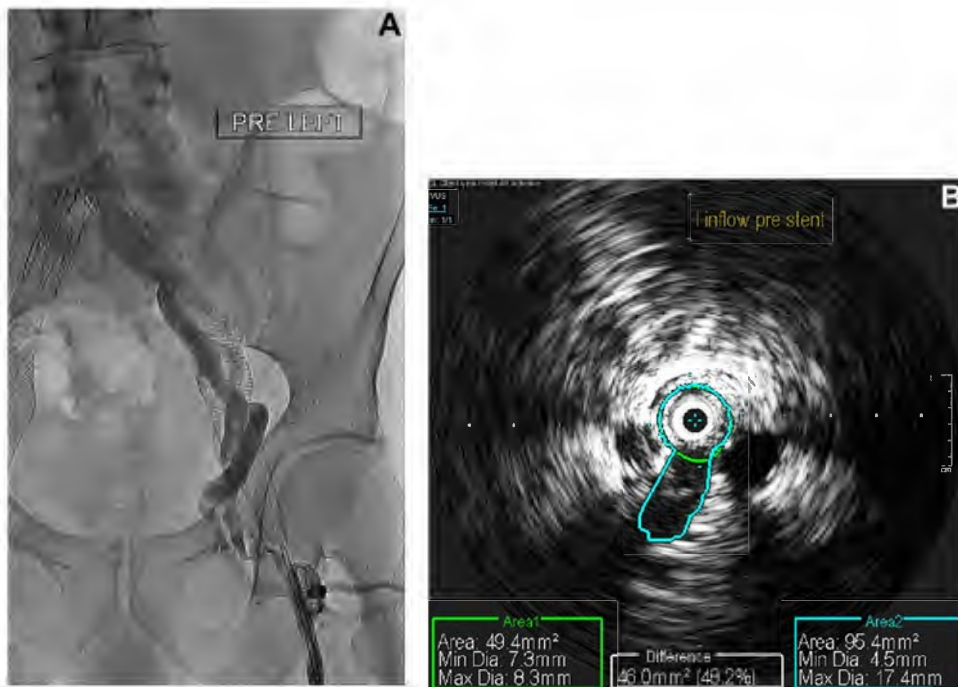
Correspondence: Taimur Saleem, MBBS, FACS, The RANE Center for Venous and Lymphatic Diseases, Ste 401, 971 Lakeland Dr, Jackson, MS 39216 (e-mail: [taimur@gmail.com](mailto:taimur@gmail.com)).

The editors and reviewers of this article have no relevant financial relationships to disclose per the Journal policy that requires reviewers to decline review of any manuscript for which they may have a conflict of interest.

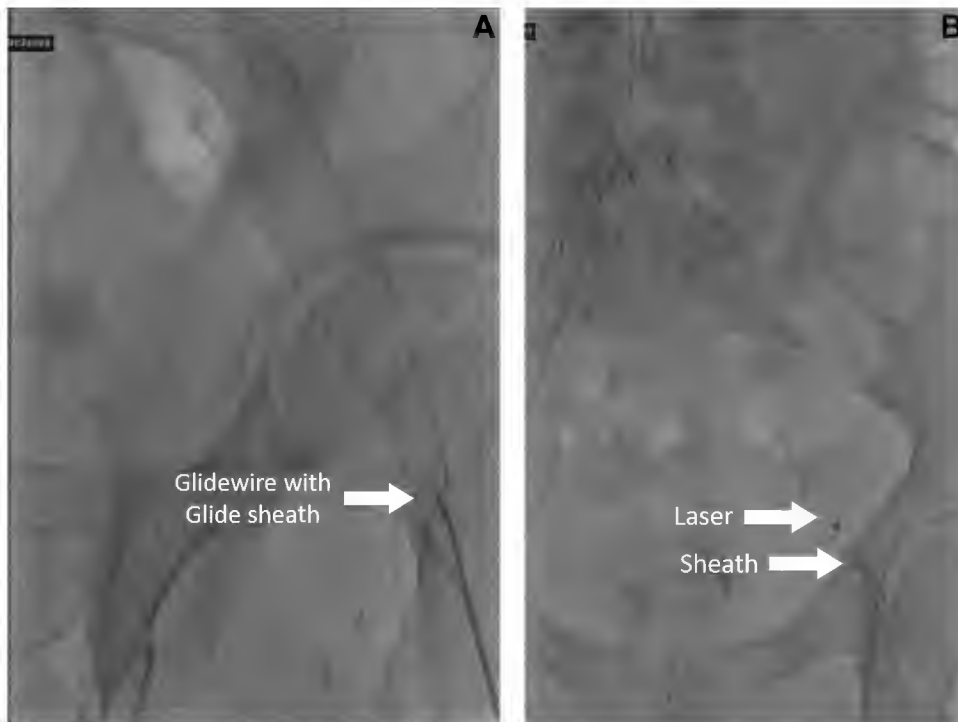
2468-4287

© 2022 The Author(s). Published by Elsevier Inc. on behalf of Society for Vascular Surgery. This is an open access article under the CC BY-NC-ND license (<http://creativecommons.org/licenses/by-nc-nd/4.0/>).

<https://doi.org/10.1016/j.jvscit.2022.06.006>



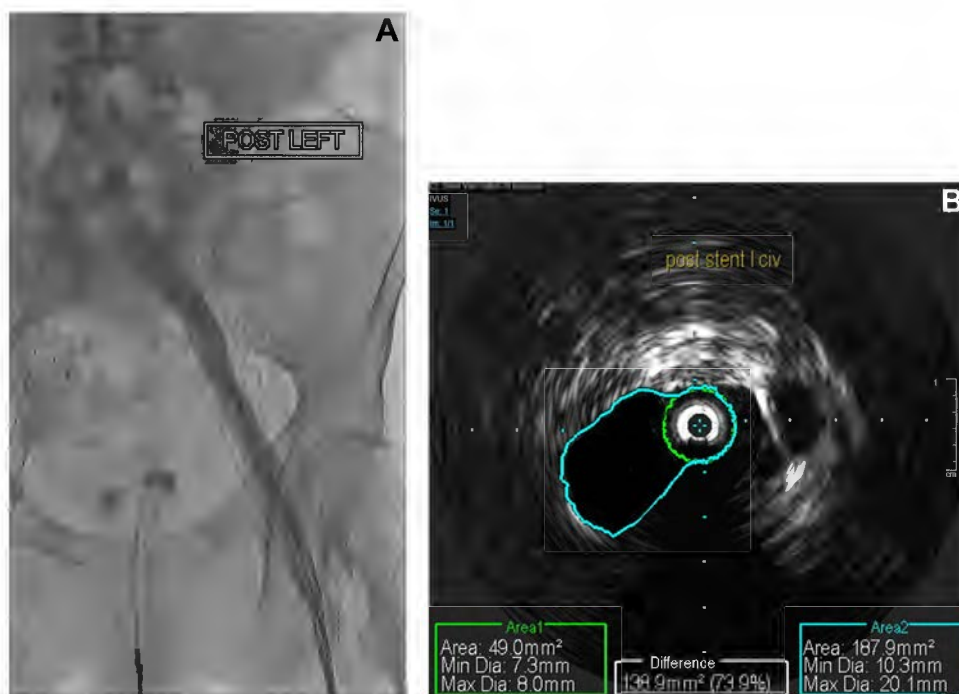
**Fig 1. A,** Anteroposterior projection venogram demonstrating stent occlusion. The stent could not be traversed with the Glidewire alone. Collateral veins can also be seen. **B,** Intravascular ultrasound image demonstrating occlusion of the stent in the common femoral venous segment.



**Fig 2. A,** A Glidewire with a Glide catheter used to engage the terminal portion of the chronically occluded stent in the common femoral vein segment. **B,** Laser supported by a sheath was used to recanalize the stent, followed by angioplasty.

was performed (Fig 2, B) using a 2.3-mm Spectranetics laser (Spectranetics Corp, Colorado Springs, CO). To support the laser catheter, we used an 8.5F, 6-cm Swartz

Transseptal sheath (Abbott Laboratories, Abbott Park, IL). The laser settings were as follows: fluence, 60 mJ/mm<sup>2</sup>; and a rate of 80 pulses/s. Following successful laser



**Fig 3. A,** Venogram showing flow through the stent column after laser recanalization and balloon angioplasty. **B,** Intravascular ultrasound (IVUS) image demonstrating a patent stent in the common iliac venous segment after intervention.

recanalization of the CTVSO, balloon angioplasty was performed to improve the caliber of the recanalized stented tract. Completion IVUS and venography were then performed (Fig 3). In a few cases ( $n = 3$ ; 15%), distal or proximal stent extension was also performed for inflow or outflow lesions that were deemed prohibitive for optimal venous flow. After the procedure, these patients were prescribed chronic anticoagulation therapy.

Follow-up was performed at our clinic at 2 weeks, 6 weeks, and 3 months after the procedure and then at 6- to 12-month intervals. Ultrasound was performed at each clinic visit. Data from the most recent follow-up visit were used for the purposes of the present analysis to best determine how long the improvements in the various clinical parameters had lasted. For residual or recurrent symptoms that were not responsive to conservative therapy for  $\geq 3$  to 6 months, IVUS was offered to investigate the cause of stent malfunction further. If in-stent restenosis (ISR) was encountered, the patients underwent either isodilation or hyperdilation. These techniques for the management of ISR have been described in detail previously.<sup>5</sup> In brief, isodilation refers to balloon angioplasty of the stent using a balloon of the same rated diameter as the stent (eg, a 16-mm balloon for a 16-mm stent). Hyperdilation refers to balloon angioplasty of the stent using a balloon larger than the rated diameter of the stent (eg, an 18-mm balloon for a 16-mm stent). Isodilation was attempted first in all patients. If isodilation had failed to produce the desired result (adequate correction of ISR), hyperdilation was used. For cases of reocclusion,

thrombectomy or wire recanalization was performed, depending on the acuity of the occlusion. Statistical analysis was performed using a commercially available statistics program (Prism software, Irvine, CA). All the patients provided written informed consent. The institutional review board approved the present study and publication of de-identified patient data from our study.

## RESULTS

During the study period, 353 cases of chronic total venous occlusion were encountered. Laser recanalization was attempted in 69 limbs (19.5%). The laser recanalization technique was successful in 34 limbs (31 patients) with chronic total occlusive stented lesions. Therefore, the technical success of laser recanalization was 49.3%. The demographic details are presented in the Table. The mean patient age was  $52 \pm 13.6$  years (range, 24-73 years). The mean time from initial venous stent placement to laser recanalization was  $53 \pm 70.8$  months, and the mean time from occlusion to reintervention was  $24.2 \pm 14.8$  months. The mean number of pulses per limb was  $29,280 \pm 20,047$ . The mean duration of laser application was  $344.9 \pm 276.4$  seconds. No adverse events related to laser use occurred. Balloon angioplasty after laser crossing was isodilation in 24 limbs (70.6%). In 10 limbs (29.4%), hyperdilation had been required needed to obtain an adequate stent caliber.

After intervention for CTVSO laser recanalization, the venous clinical severity score had improved from  $8.2 \pm 4$  to  $5.1 \pm 3.3$  ( $P < .0001$ ). The visual analog scale

**Table.** Patient characteristics

Characteristic	Mean $\pm$ SD (range) or No. (%)
Age, years	52 $\pm$ 13.6 (24-73)
BMI, kg/m <sup>2</sup>	34.3 $\pm$ 9.9 (18-60)
Left/right ratio	1.5:1
Male/female ratio	1:2.5
CEAP class <sup>a</sup>	
0-2	0 (0)
3	7 (20)
4	18 (53)
5	5 (15)
6	4 (12)

BMI, Body mass index; CEAP, Clinical, Etiologic, Anatomic, Pathophysiologic; SD, standard deviation.

<sup>a</sup>Only clinical class reported.

score for pain had improved from  $7.4 \pm 2.5$  to  $4.9 \pm 3$  ( $P = .0009$ ). The grade of swelling had improved from  $2.7 \pm 1.3$  to  $1.6 \pm 1.4$  ( $P = .0001$ ). Four patients had an active chronic venous ulcer in the present series (CEAP [Clinical, Etiologic, Anatomic, Pathophysiologic] class C6). The ulcer had healed successfully after laser recanalization in all four patients. The mean time to ulcer healing was 8 weeks after intervention. No ulcer recurrence was noted.

The mean follow-up after the intervention was  $26 \pm 20.9$  months. At 12 months after the intervention, primary stent patency was 60% (standard error of the mean, 9.3%) and primary assisted patency was 80%. The secondary stent patency was 80%. Thirteen limbs (38.2%) had required repeat intervention after laser recanalization of CTVSO. The mean time to reintervention after laser recanalization was  $\sim 9$  months. Of the 13 limbs, 6 had required reintervention for acute stent occlusion and 7 owing to the development of symptomatic ISR. Reintervention for ISR was only offered to symptomatic patients. Of the six cases of acute stent occlusion, three were symptomatic and three were detected by duplex ultrasound surveillance without the development of severe symptoms. The stents that had required reintervention had poorer inflow than the ones that had not required reintervention.

For acute stent occlusions that had developed following laser recanalization of CTVSO, pharmacomechanical or mechanical thrombectomy with balloon maceration of thrombus was used. For symptomatic ISR, balloon angioplasty with either isodilation or hyperdilation techniques was used as detailed.

## DISCUSSION

Venous stent occlusions, although overall rare, can be difficult to cross. Laser recanalization is a rarely required, but helpful, technique in this regard. Compared with laser ablation for ISR,<sup>1</sup> laser recanalization for CTVSO

uses fewer mean pulses per limb and a shorter mean time for laser application. In contrast to the patency results we reported for the laser recanalization technique at 12 months in the present study, the previously reported 60-month primary, primary assisted, and secondary patency for recanalized stents with wire technique was 35%, 25%, and 18% respectively.<sup>2</sup>

Several technical aspects merit consideration with the use of laser energy for recanalization of chronic venous occlusions. The use of an excimer laser in native venous occlusions, although described,<sup>6,7</sup> should be used with caution owing to the potential risk of perforation and damage to surrounding vital structures and the lack of a supporting external scaffold such as a metallic stent. IVUS should be used throughout the procedure to monitor the progress and trajectory of the laser catheter. The laser cannot be used with the Glidewire (Terumo Medical Corp) because it can severely damage the coating of the Glidewire. If a wire must be used while the laser is in use, a 3.5-cm tip Amplatz Super Stiff polytetrafluoroethylene-coated guidewire (Boston Scientific, Marlborough, MA) is a reasonable option.<sup>2</sup> An alternative is to bareback the laser without a wire. The laser catheter by itself lacks support compared with the concrete-like material often encountered in chronically occluded venous stents. Hence, the use of a supporting sheath such as the Swartz transeptal sheath has been recommended.<sup>1,2</sup> Finally, a small amount of contrast should be injected slowly through the laser catheter during the procedure intermittently owing to its cavitation effect on the occlusive material in the stent. Absorption of the ultraviolet light is believed to induce shock waves that expedite the advancement of the laser catheter through the occluded stent.<sup>8</sup>

**Study limitations.** The main limitations of the present study included its retrospective nature, small sample size, and relatively short follow-up. The additional cost of laser catheters is another consideration.<sup>1</sup> However, we believe the use of this technique is clinically meaningful owing to the improvements seen in the clinical parameters, including ulcer healing.

## CONCLUSIONS

Excimer laser recanalization of chronically occluded venous stents appears to be a rarely required, but useful, technical modality with reasonable clinical outcomes. Further reintervention could be required to maintain stent patency in the long term.

## REFERENCES

- Jayaraj A, Fuller R, Raju S. Role of laser ablation in recalcitrant in-stent restenosis post iliofemoral venous stenting. *J Vasc Surg Cases Innov Tech* 2021;7:298-301.
- Jayaraj A, Crim W, Knight A, Raju S. Characteristics and outcomes of stent occlusion after iliofemoral stenting. *J Vasc Surg Venous Lymphat Disord* 2019;7:56-64.

3. Saleem T, Knight A, Raju S. Diagnostic yield of intravascular ultrasound in patients with clinical signs and symptoms of lower extremity venous disease. *J Vasc Surg Venous Lymphat Disord* 2020;8:634-9.
4. Saleem T, Raju S. Comparison of intravascular ultrasound and multi-dimensional contrast imaging modalities for characterization of chronic occlusive iliofemoral venous disease: a systematic review. *J Vasc Surg Venous Lymphat Disord* 2021;9:1545-56.e2.
5. Saleem T, Raju S. An overview of in-stent restenosis in iliofemoral venous stents. *J Vasc Surg Venous Lymphat Disord* 2022;10:492-503.e2.
6. Rambhia S, Janko M, Hacker RI. Laser recanalization of central venous occlusion to salvage a threatened arteriovenous fistula. *Ann Vasc Surg* 2018;50:297.e1-3.
7. Henrikson CA, Alexander D, Ringel RE, Brinker JA. Laser recanalization of the subclavian vein. *Pacing Clin Electrophysiol* 2006;29:436-7.
8. Biamino G, Scheinert D. Excimer laser treatment of SFA occlusions. *Endovascular Today*. Available at: [https://evtoday.com/articles/2003-may-june/0503\\_101.html](https://evtoday.com/articles/2003-may-june/0503_101.html). Accessed March 3, 2022.

Submitted Mar 14, 2022; accepted Jun 15, 2022.