

Management of iatrogenic inferior vena cava perforation with composite Wallstent–Z-stent technique

Taimur Saleem, MBBS, and Seshadri Raju, MD, FACS, Jackson, Miss

ABSTRACT

Inferior vena cava rupture is uncommon but can occur as a result of trauma or catheterization and during venous interventions. We have described two cases of iatrogenic inferior vena cava perforation, with their successful management with bare metal stents (a composite Wallstent–Z-stent technique). This management strategy was possible owing to the unique properties of the venous system. (*J Vasc Surg Cases Innov Tech* 2021;7:630-3.)

Keywords: Inferior vena cava; Pseudoaneurysm; Venous; Wallstent; Z-stent

Inferior vena cava (IVC) rupture is uncommon but can occur as a result of trauma or catheterization and during venous interventions. IVC rupture has also been described spontaneously, after IVC filter removal, or because of IVC filter migration.¹⁻³ We report two cases of IVC rupture and their subsequent management with bare metal stents (composite Wallstent–Z-stent technique). Both patients had provided written informed consent before the index scheduled procedure for recanalization coupled with angioplasty and stenting and any additional procedures necessary to correct any complications arising from the procedure. We believe our report will contribute to the limited data on the management of IVC rupture during deep venous interventions because the Wallstent–Z-stent composite represents a category of uncovered stents.

CASE REPORT

Patient 1. A 65-year-old man had presented with bilateral nonhealing venous leg ulcerations (CEAP [clinical, etiologic, anatomic, pathophysiologic] C6). He was noted to have chronic total occlusion of bilateral iliofemoral venous segments and the IVC with severe post-thrombotic syndrome. Preoperatively, he was given thromboprophylaxis (enoxaparin 40 mg subcutaneously and intravenous bivalirudin 75 mg). He underwent successful right iliofemoral and IVC recanalization under general anesthesia. After angioplasty of the severely post-thrombotic IVC with a 24 × 40-mm angioplasty balloon, IVC perforation was

noted on subsequent venograms. The patient developed hypotension (blood pressure 70/38 mm Hg), and fluid resuscitation was immediately started. Initially, the angioplasty balloon had been inflated in the IVC; however, contrast extravasation had persisted when the balloon was deflated. A composite Wallstent (24 × 45 mm; Boston Scientific, Marlborough, Mass) and Z-stent (30 × 50 mm; Cook Medical, Bloomington, Ind) technique was used to exclude this rupture near the iliac–caval venous confluence with sustained inflation of the previously used angioplasty balloon (*Fig 1, A*). A second Z-stent was used cephalad, near the renal vein orifice to fenestrate the ostia of the renal veins. No antifactor Xa reversal agents were administered. Contrast extravasation stopped after placement of this Wallstent–Z-stent composite and angioplasty, and patient's vital signs had stabilized (*Fig 1, B*). No postprocedural sequelae occurred. Therapeutic anticoagulation was resumed within 24 hours after the procedure, and the patient was discharged home on postoperative day 2 after an uneventful stay. The patient reported mild postprocedural abdominal pain that had resolved on postoperative day 2. The postoperative ultrasound on day 1 did not demonstrate any extravasation from the IVC. At the 6-month follow-up, ultrasound interrogation revealed patent stents without any further sequelae. The patient reported his ulcers had healed and significant improvement in lower extremity swelling and pain. No deterioration of renal function was noted at follow-up.

Patient 2. A 45-year-old man had presented with nonhealing venous ulceration (CEAP C6) of his left leg. He was noted to have left chronic iliofemoral and IVC outflow obstruction and severe post-thrombotic syndrome. He had also had an indwelling IVC filter in place for ≥20 years. Intervention was performed with the patient under general anesthesia. After left iliofemoral angioplasty and venous stenting, an attempt was made to retrieve the IVC filter (*Fig 2, A*) via a right internal jugular approach. At the level of the IVC filter, intravascular ultrasound (IVUS) was used, which demonstrated significant IVC narrowing with a cross-sectional area of only 125 mm² (*Fig 2, B*), representing significant outflow obstruction. IVC filter retrieval was challenging owing to the prolonged time since implantation. However, IVC filter retrieval was successful using advanced techniques,

From The RANE Center for Venous and Lymphatic Diseases.

Author conflict of interest: S.R. receives royalties from Veniti Inc. for a U.S. patent for intravascular ultrasound diagnostics and iliac vein stent design. T.S. has no conflicts of interest.

Correspondence: Taimur Saleem, MBBS, RANE Center for Venous and Lymphatic Diseases, 971 Lakeland Dr, Ste 401, Jackson, MS 39216 (e-mail: taimur@gmail.com).

The editors and reviewers of this article have no relevant financial relationships to disclose per the Journal policy that requires reviewers to decline review of any manuscript for which they may have a conflict of interest.

2468-4287

© 2021 The Author(s). Published by Elsevier Inc. on behalf of Society for Vascular Surgery. This is an open access article under the CC BY-NC-ND license (<http://creativecommons.org/licenses/by-nc-nd/4.0/>).

<https://doi.org/10.1016/j.jvsct.2021.08.005>

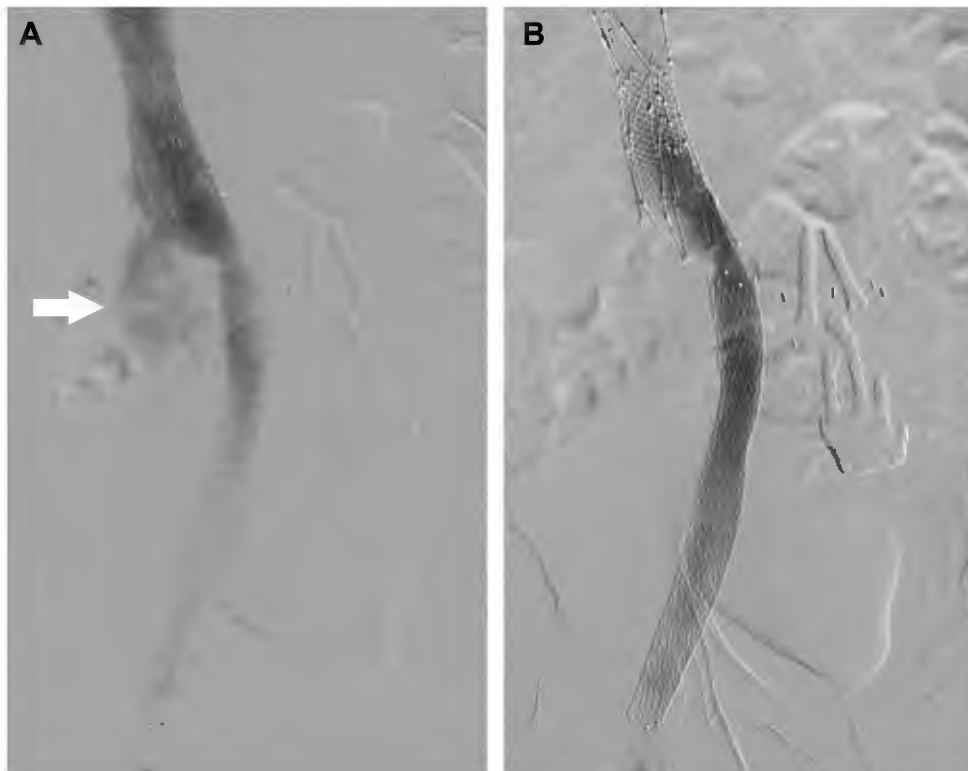


Fig 1. A, After angioplasty, an inferior vena cava (IVC) perforation (*white arrow*) was noted on the venogram proximal to the iliac–caval confluence. A Wallstent–Z-stent composite was deployed. **B,** After composite Wallstent–Z-stent placement and sustained angioplasty, the contrast extravasation had significantly diminished. Note the Z-stent was placed both proximally and distally in the IVC.

including centering techniques and coaxial double sheath dissection. Venography performed immediately after IVC filter retrieval demonstrated an infrarenal IVC rupture (Fig 2, C) below the renal veins. Hemodynamically, the patient developed hypotension (blood pressure 90/42 mm Hg). Initially, the angioplasty balloon was inflated; however, the rupture was not sealed with balloon inflation. The rupture was excluded using a Wallstent (24 × 45 mm) and Z-stent (30 × 50 mm) composite configuration with sustained angioplasty. Contrast extravasation stopped after deployment of the Wallstent–Z-stent composite, and no postprocedural sequelae ensued (Fig 2, D). The patient was hemodynamically stable at this time. Therapeutic anticoagulation was resumed within 24 hours after the procedure, and the patient was discharged home on postoperative day 1 after an uneventful course. The patient did not report any postprocedural abdominal pain. The postoperative day 1 ultrasound scan did not demonstrate any delayed hematoma or extravasation from the IVC. At the 6-month follow-up, ultrasound interrogation showed patent stents without any further sequelae. The patient reported healing of the ulcers and significant improvement in lower extremity swelling and pain. No decline in renal function was noted at follow-up.

DISCUSSION

Wallstent–Z-stent composite technique. The Wallstent–Z-stent composite technique has been well

described previously during iliofemoral stenting for both nonthrombotic iliac vein lesions and post-thrombotic lesions, with excellent long-term relief of symptoms, primary patency, primary-assisted patency, and secondary patency. Also, the incidence of contralateral deep vein thrombosis (DVT) was extremely rare with this configuration (<1%).⁴ Using this technique, the Wallstent is landed just short of the iliac–caval confluence proximally. Next, the Z-stent is deployed within the Wallstent, such that a part of the Z-stent protrudes into the distal IVC and a part remains within the Wallstent in the common iliac vein. In our two patients, we used this composite technique to exclude the IVC rupture that had occurred from a combination of severe post-thrombotic disease and angioplasty with large-size balloons. Z-stents were placed across the ostia of the renal veins. These cases have demonstrated several key points.

Uncovered stents for exclusion of IVC rupture. Marsala et al² described the use of aortic extender endoprosthesis (W. L. Gore & Associates, Flagstaff, Ariz) and the Gore TAG thoracic endoprosthesis to seal the site of IVC rupture after removal of an IVC filter. Although the use of covered grafts has been described in the setting of IVC filter retrieval complications,² we found that uncovered stents (Wallstent and Z-stent) resulted in effective

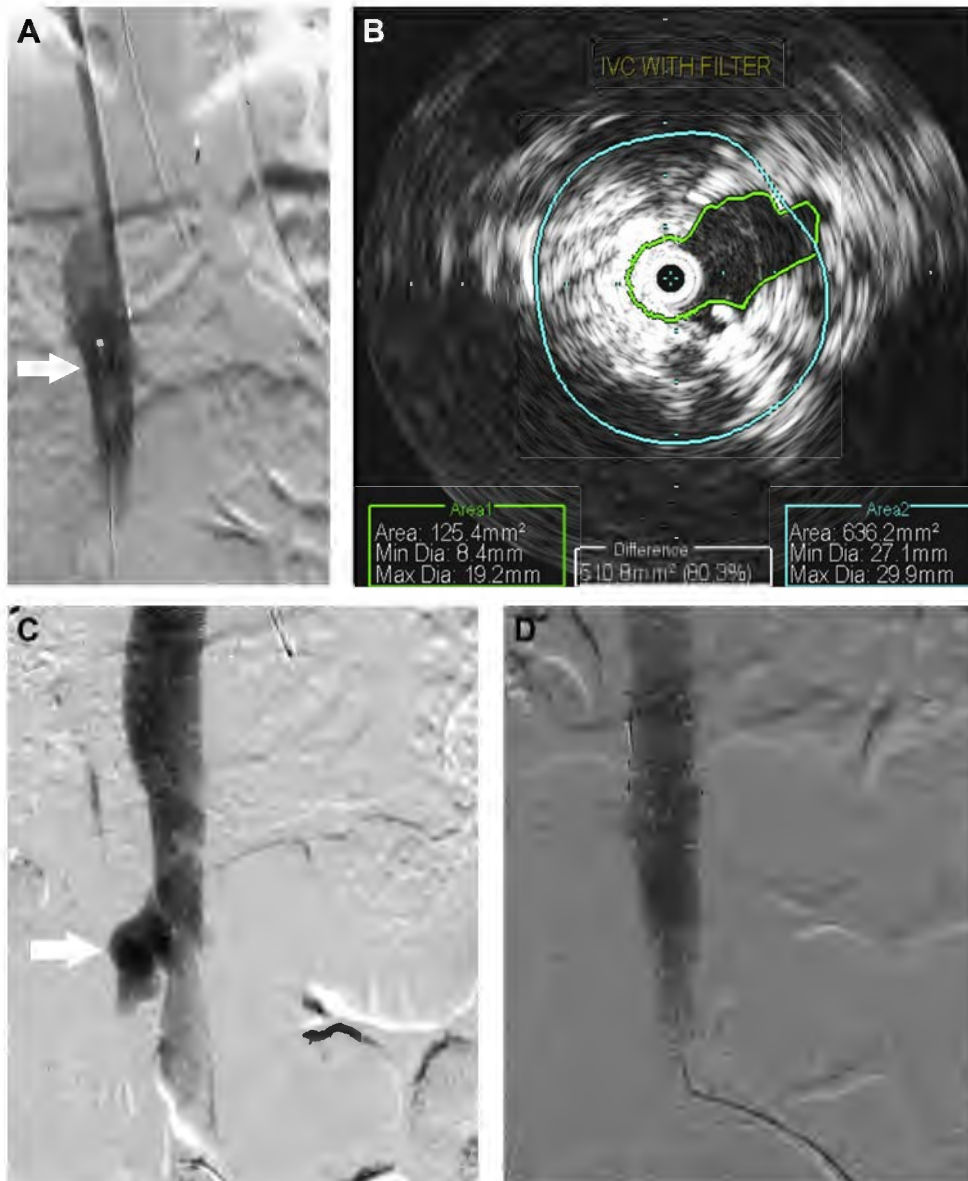


Fig 2. **A**, Inferior vena cava (IVC) filter seen in the infrarenal IVC (*white arrow*). Note that no obvious focal stenosis is readily apparent on the venogram. **B**, Intravascular ultrasound (IVUS) showed severe IVC stenosis at the level of the IVC filter resulting in outflow venous obstruction. **C**, After filter removal, a venogram of the IVC showed IVC perforation (*white arrow*). **D**, Cessation of contrast extravasation after stenting and sustained angioplasty.

exclusion of the ruptured IVC by providing the path of least resistance and simultaneously addressing coexisting venous outflow stenosis. This exclusion was possible with uncovered stents because of the less robust blood flow in the veins compared with the arteries.

Use of IVUS is important in venous interventions. The use of IVUS during IVC filter placement and retrieval has been recommended to size the IVC correctly and uncover any IVC filter-related stenosis that might not be readily apparent using venography because IVUS is more sensitive than venography.⁵

Indications for repair of IVC rupture. An IVC rupture encountered during endovenous intervention should be repaired if hemodynamic instability is present and contrast extravasation from the ruptured segment of IVC is persistent or enlarging. Small contained ruptures can be monitored serially with anticoagulation withheld because such ruptures might seal on their own. Effective and prompt exclusion of the IVC rupture allowed for resumption of anticoagulation therapy without any major delay in our two patients; both of whom had had post-thrombotic syndrome and had a high risk of recurrent DVT. With expectant or conservative

management, anticoagulation therapy would likely need to be withheld for a longer duration, increasing the risk of DVT and/or pulmonary embolism.

Stenting across renal vein ostia. The Z-stent is recommended when stenting across the renal vein orifices is required to reduce the potential risk of future renal vein thrombosis. The interstices of the Z-stent are much larger than those of the Wallstent; hence, they are more resistant to complete endothelialization. Theoretically, the Z-stent remains more “porous” than the Wallstent because of its larger interstices. In the iliac system, it has been demonstrated that using the Z-stent at the ilio caval confluence will reduce the consequences of “jailing” the contralateral iliac vein orifice. In contrast, the use of the Wallstent without the Z-stent carries a 10% risk of contralateral DVT in the iliac venous system when the Wallstent has been extended into the IVC.⁶ The use of the Z-stent combined with the Wallstent reduces this risk to $\leq 1\%$.^{4,6}

CONCLUSIONS

We have described a unique method of treating complications of iatrogenic IVC rupture when recanalizing occluded or severely post-thrombotic iliofemoral veins and the IVC. This management strategy was possible owing to the unique properties of the venous system.

The key technical considerations include (1) deployment of the Z-stent near the renal ostia to reduce the potential risk of renal vein thrombosis from long-term endothelialization of the stents; and (2) use of IVUS to detect venous stenosis not readily apparent by venography to provide a channel of least resistance and reduce flow from the rupture.

REFERENCES

1. Choi HI, Kim YK, Choi SI, Kim K. Spontaneous rupture of inferior vena cava. *Am J Emerg Med* 2017;35:1383.e3-4.
2. Marsala A, Haddock T, Baril D, Kee S. Rupture of the inferior vena cava during filter removal. *J Vasc Interv Radiol* 2018;29:1618-9.
3. Satya R, Anderson J, Lievano G, Satya RJ. Inferior vena cava (IVC) rupture and retroperitoneal hemorrhage caused by IVC filter migration. *J Vasc Interv Radiol* 2009;20:1102-4.
4. Jayaraja A, Noel C, Kuykendall R, Raju S. Long-term outcomes following use of a composite Wallstent–Z stent approach to iliofemoral venous stenting. *J Vasc Surg Venous Lymphat Disord* 2021;9:393-400.e2.
5. Saleem T, Raju S. Comparison of intravascular ultrasound and multi-dimensional contrast imaging modalities for characterization of chronic occlusive iliofemoral venous disease: a systematic review [e-pub ahead of print]. *J Vasc Surg Venous Lymphat Disord*. <https://doi.org/10.1016/j.jvsv.2021.03.022>. Accessed June 26, 2021.
6. Murphy EH, Johns B, Varney E, Buck W, Jayaraj A, Raju S. Deep venous thrombosis associated with caval extension of iliac stents. *J Vasc Surg Venous Lymphat Disord* 2017;5:8-17.

Submitted Jun 29, 2021; accepted Aug 17, 2021.