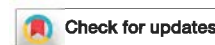

Impact of degree of stenosis in May-Thurner syndrome on iliac vein stenting



Arjun Jayaraj, MD, William Buck, MS, Alexander Knight, BS, Blake Johns, BS, and Seshadri Raju, MD, Jackson, Miss

ABSTRACT

Objective: May-Thurner syndrome (MTS) patients with lifestyle-limiting symptoms undergo stenting of the iliac vein for relief of compressive disease. The impact of degree of stenosis on clinical symptoms and outcomes after stenting is unknown and examined in our study.

Methods: Retrospective review of contemporaneously entered data of 202 patients who underwent stenting for MTS between 2005 and 2011 was performed. Classification into three groups based on luminal area obtained by intraoperative intravascular ultrasound interrogation of the involved femoroiliac segments was carried out. Normal luminal diameters and areas were defined as 12 mm and 125 mm², 14 mm and 150 mm², and 16 mm and 200 mm² in the common femoral, external iliac, and common iliac veins, respectively. Mild (<60%), moderate (60%-89%), and severe (>90%) compression groups were defined using the normal values noted previously and observed after stenting to evaluate outcomes. Kaplan-Meier analysis was done to assess primary, primary assisted, and secondary patencies. Visual analog scale for pain scores, grade of swelling, and Venous Clinical Severity Score (VCSS) before and after stenting at 6, 24, and 48 months were analyzed using paired *t*-test and Tukey test. Logistic regression was used to gauge the impact of multiple variables including degree of stenosis on stent reintervention.

Results: There were 55 patients who had mild, 87 patients who had moderate, and 60 patients who had severe iliac vein compression. Baseline demographic characteristics and comorbidities were similar across all groups. In addition, there was no statistically significant difference in median baseline visual analog scale score, grade of swelling, and VCSS among the groups. Compression was treated with angioplasty and stenting encompassing all areas of disease as determined by intravascular ultrasound. Stent technique involved use of Wallstent (Boston Scientific, Marlborough, Mass) only in 183 patients and Wallstent-Z stent (Cook Medical, Bloomington, Ind) combination in the remainder. No difference in median stent patency was noted on follow-up. Clinically, at 48 months, a statistically significant recurrence of pain, swelling, and worsening of VCSS were noted in the severe stenosis group but not in the other two groups. No variable was noted to have an impact on stent reintervention.

Conclusions: Severity of MTS stenosis is not a predictor of initial clinical symptoms. Long term, patients with ≥90% initial MTS stenosis experience recurrence of symptoms. The degree of iliac venous stenosis does not appear to affect stent patency. Such information will help counsel patients before intervention. (*J Vasc Surg: Venous and Lym Dis* 2019;7:195-202.)

Keywords: May-Thurner syndrome; Nonthrombotic iliac vein lesion; Iliac compression syndrome; Iliac vein stenting; Iliofemoral stenting

The original description of obstructive lesions of the ilioacaval territory was given by McMurrich¹ and included multiple types of lesions that involved this venous segment. Further work by Ehrich and Krumbhaar² in

1943 and subsequently by May and Thurner³ in 1957 confirmed the existence of this disease and the preponderance of left laterality of such lesions. May and Thurner³ also provided a histologic basis to the condition, describing the obstructive spur as composed of loose endothelialized connective tissue instead of smooth muscle and elastic fibers. They hypothesized that these lesions arose because of pulsatile trauma to the vein from the overlying artery. However, there is also support for congenital origin of such a lesion, underscoring its likely multifactorial basis.^{1,2,4-6} The term *iliac compression syndrome* was coined by Cockett and Thomas,⁷ who went on to describe diagnosis and treatment of the condition.⁴ The same group noted that the left common iliac compression/bands did not give rise to the symptoms themselves but served as a site for development of deep venous thrombosis and subsequent development of post-thrombotic stricture.^{4,8} More recently,

From The RANE Center for Venous and Lymphatic Diseases, St. Dominic Hospital.

Author conflict of interest: S.R. holds a U.S. patent regarding intravascular ultrasound diagnostics in chronic venous disease and has stock in Veniti.

Presented as a plenary session at the Twenty-ninth Annual Meeting of the American Venous Forum, New Orleans, La, February 14-17, 2017.

Correspondence: Arjun Jayaraj, MD, The RANE Center for Venous and Lymphatic Diseases at St. Dominic Hospital, 971 Lakeland Dr, Ste 401, Jackson, MS 39216 (e-mail: jayaraj.arjun2015@gmail.com).

The editors and reviewers of this article have no relevant financial relationships to disclose per the Journal policy that requires reviewers to decline review of any manuscript for which they may have a conflict of interest.

2213-333X

Copyright © 2018 by the Society for Vascular Surgery. Published by Elsevier Inc. <https://doi.org/10.1016/j.jvs.2018.10.001>

Kibbe et al⁹ found that up to 66% of individuals have at least 25% or greater compression of the left common iliac vein. The authors noted mean compression of around 35.5%, with women having greater compression.⁹ In addition, multiple sites can be affected by compression, and an anatomic classification based on the nature and extent of the obstruction has recently been proposed.¹⁰ In spite of high prevalence of May-Thurner anatomy, only a small percentage go on to develop the syndrome. In fact, post-thrombotic syndrome makes up the majority of disease burden of chronic venous insufficiency due to deep venous disease. However, nonthrombotic iliac vein lesions including May-Thurner syndrome (MTS) also make a significant contribution, with MTS contributing to 15% of the disease burden in patients meriting intervention for occlusive disease.¹¹

Contemporary treatment of patients with MTS presenting with lifestyle-limiting symptoms is ilio caval stenting. Whereas technique and outcomes of such stenting have been described, the impact of the degree of stenosis in MTS on clinical and stent outcomes has not been explored.¹²⁻²⁰ This study evaluates these aspects of stenting for MTS.

METHODS

Contemporaneously entered data into electronic medical records of 202 lower limbs that underwent stenting for MTS between 2005 and 2011 were analyzed. The degree of compression as ascertained by reduction in luminal area on intravascular ultrasound (IVUS) was determined. Normal luminal diameters and areas were defined as 12 mm and 125 mm², 14 mm and 150 mm², and 16 mm and 200 mm² in the common femoral, external iliac, and common iliac veins, respectively.²¹ Luminal compression so quantified was classified into three groups: mild (<60% compression), moderate (60%-89% compression), and severe (>90% compression). The groups were observed after stenting to evaluate clinical and stent outcomes.

IVUS

IVUS is considered the "gold standard" in the management of obstructive femoroiliac lesions. IVUS guidance is essential for accurate diagnosis, disease characterization, intraoperative treatment guidance, and follow-up in patients with recurrent symptoms. IVUS is performed using an 8.2F, 10 MHz transducer (Phillips Volcano, San Diego, Calif). Planimetric evaluation of the luminal areas of the common femoral vein, external iliac vein, and common iliac vein is made with normal luminal areas and diameters as defined before.²¹

Treatment

Patients presenting with disabling symptoms including pain, swelling, hyperpigmentation, and lipodermatosclerosis suggestive of MTS underwent IVUS interrogation to confirm diagnosis and stenting once diagnosis was confirmed.

ARTICLE HIGHLIGHTS

- **Type of Research:** Retrospective cohort study
- **Key Findings:** In 202 patients who underwent iliofemoral vein stenting for May-Thurner syndrome, the severity of stenosis did not predict initial clinical symptoms or stent patency. At 48 months, patients with >90% stenosis experienced recurrence of symptoms.
- **Take Home Message:** Patients with severe iliofemoral stenosis due to May-Thurner syndrome should expect some recurrence of symptoms in spite of successful stenting.

Stent sizing. Appropriate stent sizes were used, taking into account the element of recoil and potential for in-stent restenosis. In this regard, we used 14-mm, 16-mm, and 18-mm stent sizes in the common femoral vein, external iliac vein, and common iliac vein, respectively.²¹

Type of stent. Either Wallstents (Boston Scientific, Marlborough, Mass) alone or more recently Wallstent-Z stent (Cook Medical, Bloomington, Ind) combination was used to treat the culprit lesion. The use of the Cook Gianturco Z stent across the ilio caval confluence was to provide additional radial force.

Extent of stenting. Stenting was pursued to cover all areas of disease with cranial extension across the ilio caval confluence and caudal extension into an area of good inflow.

Technique of stenting. Our technique of stenting described previously in multiple publications was used.^{13,22-29} In essence, it involves access to the ipsilateral femoral vein under ultrasound guidance and placement of a 11F × 10-cm sheath. Ascending venography was then performed, followed by IVUS interrogation. Once diagnosis was confirmed, predilation was carried out using 18-mm angioplasty balloons of the femoroiliac segment. Stenting was then performed using Wallstent in isolation (previous technique) or Wallstent-Z stent combination (current technique). IVUS was used to decide landing zones and to confirm adequacy of apposition of the stent to the vein wall. Completion venography was finally performed to confirm adequacy of flow dynamics.

Anticoagulation

Anticoagulation in the perioperative period was through use of both enoxaparin and bivalirudin. Whereas enoxaparin (40 mg) was given preoperatively, bivalirudin 75 mg was given intravenously in the operating room before the start of the procedure to effectively reduce intraoperative thrombus buildup. Postoperative anticoagulation was continued with direct oral anticoagulants for a minimum of 3 months to reduce in-stent restenosis. Continuation beyond this period was dictated by clinical

presentation on follow-up, status of stent, and presence of thrombophilia. In addition, aspirin 81 mg with cilostazol 50 mg twice daily was also used unless contraindicated. The role of cilostazol is guided by its ability to suppress neointimal hyperplasia.³⁰⁻³³ The time to re-endothelialization after venous trauma is approximately 6 weeks.³⁴ Cilostazol is continued for at least this duration.

Follow-up

Clinical and diagnostic imaging follow-up after stenting was pursued at 2, 4, and 6 weeks after intervention. Beyond this, follow-up with duplex ultrasound was every 3 to 6 months for the first year and 6 to 12 months subsequently. More frequent follow-up was used if clinical presentation or stent status called for it. Recurrence of disabling symptoms on follow-up was an indication to repeat IVUS interrogation and potentially to pursue angioplasty. Postoperatively, the last available clinic follow-up metric was used for postoperative outcome analysis.

Consent of the patients for the study and approval from the Institutional Review Board of the hospital were obtained.

Statistical analysis

All statistical analysis was performed using SPSS Statistics version 24 (IBM Corp, Armonk, NY). Clinical outcomes including pain, swelling, and Venous Clinical Severity Score (VCSS) were compared before and after intervention using the paired *t*-test and Tukey test. Patency was assessed using the Kaplan-Meier analysis. Multivariable logistic regression was used to evaluate risk factors for reintervention and symptom recurrence. *P* value ≤.05 was considered significant.

RESULTS

Mild compression (<60%) was noted in 55 patients (28%), moderate compression (60%-89%) in 87 patients (42%), and severe compression (>90%) in 60 patients (30%). Baseline demographic characteristics and comorbidities were similar across all groups except for

Table I. Comparison of baseline demographic variables between the three groups

Variable	Degree of stenosis			P value
	<60%	60%-89%	≥90%	
Age, years	57 (17-39)	55 (17-83)	54 (20-84)	.25
Sex, M/F	13/46	13/73	10/46	.57
Thrombophilia	12 (33)	9 (23)	9 (19)	.32
Smoking	6 (17)	15 (29)	14 (33)	.30
Anticoagulation	20 (34)	38 (44)	31 (55)	.07
Side, left/right	30/29	75/11	48/8	<.001

Categorical variables are presented as number (%).

Table II. Impact of degree of stenosis on preintervention clinical presentation

Variable	Degree of stenosis			P value
	<60%	60%-89%	≥90%	
VAS score (pain)	1.25	1.53	1.72	.08
GS	1.98	1.79	1.88	.61
VCSS	5.35	5.13	5.30	.93

GS, Grade of swelling; VAS, visual analog scale; VCSS, Venous Clinical Severity Score.

predominance of left laterality (Table I). In addition, there was no statistically significant difference in median baseline visual analog scale score, swelling, or VCSS among the groups (Table II). Compression was treated with angioplasty and stenting encompassing all areas of disease as determined by IVUS and noted previously. Stent technique involved use of Wallstent only in 183 patients (91%) and Wallstent-Z stent combination in the remainder (19 [9%]). Median follow-up was 94 months.

Clinical outcomes

Pain. Pain scores were improved across all three groups at 6 months of follow-up (Table III). These scores continued to improve at 2 years. At 48 months, however, although there continued to be a statistically significant improvement compared with baseline in the mild and moderate stenosis groups, no such benefit remained in the severe stenosis group.

Swelling. Swelling was significantly improved across all three groups at 6 months after intervention and remained so at 24 months (Table III). At 48 months, only the mild and moderate stenosis groups continued to have improvement. There was no statistically significant improvement in the severe group at 48 months compared with baseline.

VCSS. The VCSS parameter was calculated without using the points attributed to use of compression stockings. At 6 months, all three groups demonstrated an improvement in the VCSS metric that remained statistically significant at 24 months (Table III). At 48 months, only the mild and moderate stenosis groups continued to have a significant improvement. There was no significant difference between the baseline and 48-month VCSS metric in the severe stenosis group.

Lymphedema and stent compression on follow-up duplex ultrasound were evaluated as possible risk factors for clinical recurrence in the ≥90% stenosis group at 48 months. There was no statistically significant difference in lymphedema at baseline between the three groups. In addition, when lymphedema was broken down on the basis of severity (mild to moderate vs severe on the basis of lymphoscintigraphy findings), there was not a statistically significant increased prevalence of severe

Table III. Impact of degree of stenosis on postintervention clinical presentation

Visual analog scale (VAS) score for pain									
Variable	<60% Stenosis								
	6 months			24 months			48 months		
	Pre	Post	P	Pre	Post	P	Pre	Post	P
VAS score	1.42	0.11	<.01	1.42	0.00	<.01	1.42	0.21	<.01
Variable	60%-89% Stenosis								
	6 months			24 months			48 months		
	Pre	Post	P	Pre	Post	P	Pre	Post	P
VAS score	1.43	0.25	<.01	1.43	0.50	<.01	1.43	0.45	<.01
Variable	≥90% Stenosis								
	6 months			24 months			48 months		
	Pre	Post	P	Pre	Post	P	Pre	Post	P
VAS score	1.48	0.31	<.01	1.48	0.44	.04	1.44	0.88	>.05
Grade of swelling (GS)									
Variable	<60% Stenosis								
	6 months			24 months			48 months		
	Pre	Post	P	Pre	Post	P	Pre	Post	P
GS	2.26	0.68	<.01	2.26	0.90	<.01	2.26	0.74	<.01
Variable	60%-89% Stenosis								
	6 months			24 months			48 months		
	Pre	Post	P	Pre	Post	P	Pre	Post	P
GS	1.86	0.56	<.01	1.86	0.92	<.01	1.86	0.95	<.01
Variable	≥90% Stenosis								
	6 months			24 months			48 months		
	Pre	Post	P	Pre	Post	P	Pre	Post	P
GS	2.00	0.79	<.01	2.00	1.00	<.01	2.00	1.25	>.05
Venous Clinical Severity Score (VCSS)									
Variable	<60% Stenosis								
	6 months			24 months			48 months		
	Pre	Post	P	Pre	Post	P	Pre	Post	P
VCSS	5.35	2.18	<.01	5.35	1.73	<.01	5.35	2.86	<.01
Variable	60%-89% Stenosis								
	6 months			24 months			48 months		
	Pre	Post	P	Pre	Post	P	Pre	Post	P
VCSS	5.13	1.65	<.01	5.13	2.31	<.01	5.13	2.36	<.01
Variable	≥90% Stenosis								
	6 months			24 months			48 months		
	Pre	Post	P	Pre	Post	P	Pre	Post	P
VCSS	5.30	1.86	<.01	5.30	2.00	<.01	5.30	3.59	>.05

Post, After intervention; pre, before intervention.

lymphedema in the severe stenosis (≥90%) group. On univariate analysis, lymphedema was not found to be a statistically significant predictor for recurrence of symptoms. To enable adequate sample size for the stent compression

variable, we compared the <90% stenosis group (n = 5) with the ≥90% stenosis group (n=12). Statistically significant stent compression ($P \leq .05$) occurred between 24 and 48 months across both mild to moderate (<90%)

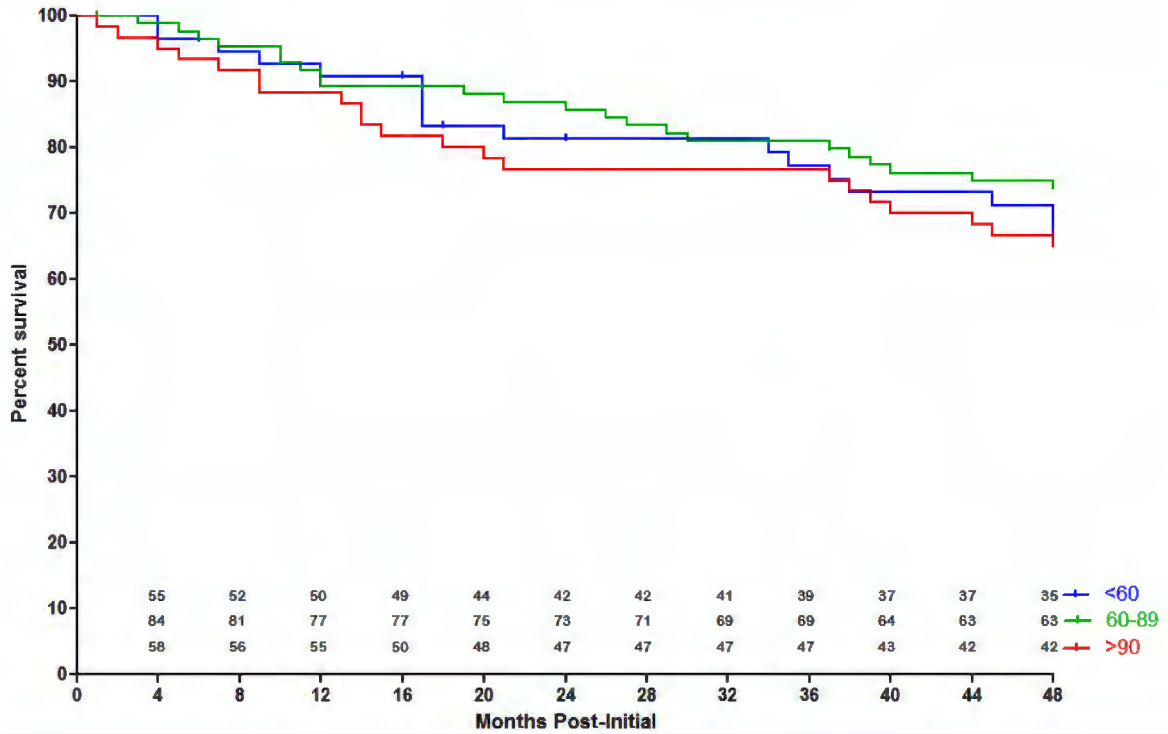


Fig 1. Primary patency after ilio caval stenting for May-Thurner syndrome (MTS).

and severe ($\geq 90\%$) groups. However, the data were inadequate (missing variables) to demonstrate a significant difference between $<90\%$ and $\geq 90\%$ stenosis groups,

although it is possible that a significant difference might have been found if there had been an adequate sample size on follow-up.

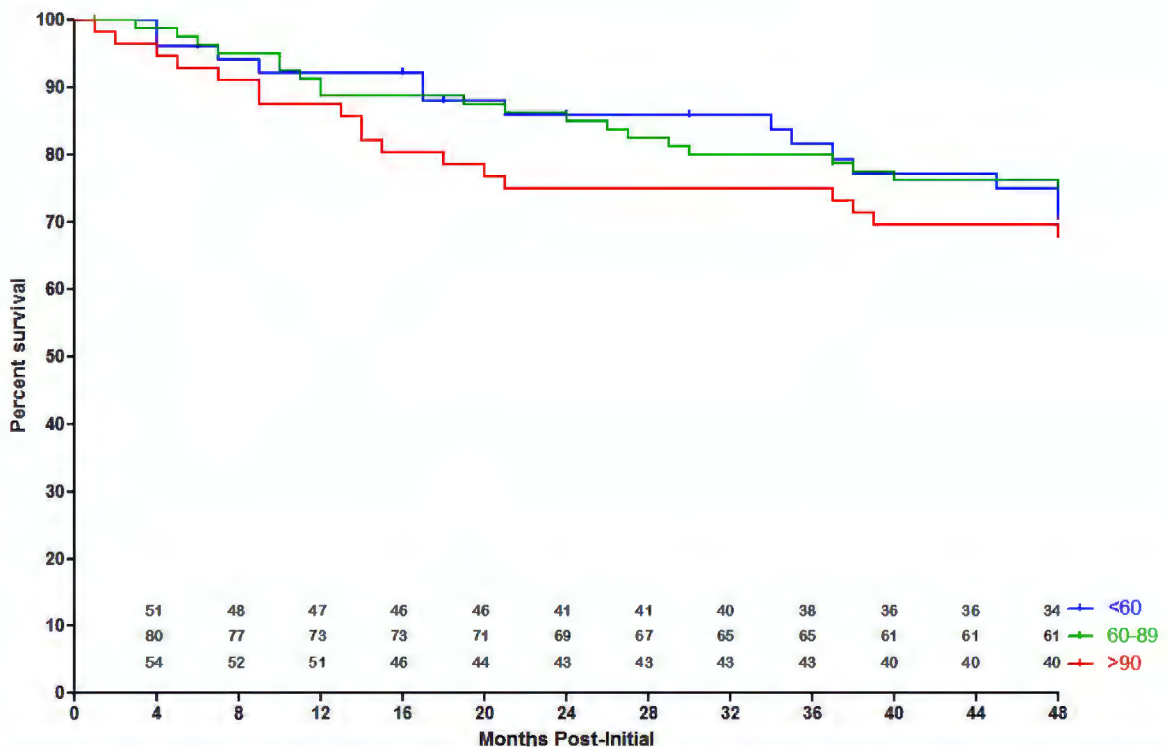


Fig 2. Primary assisted patency after ilio caval stenting for May-Thurner syndrome (MTS).

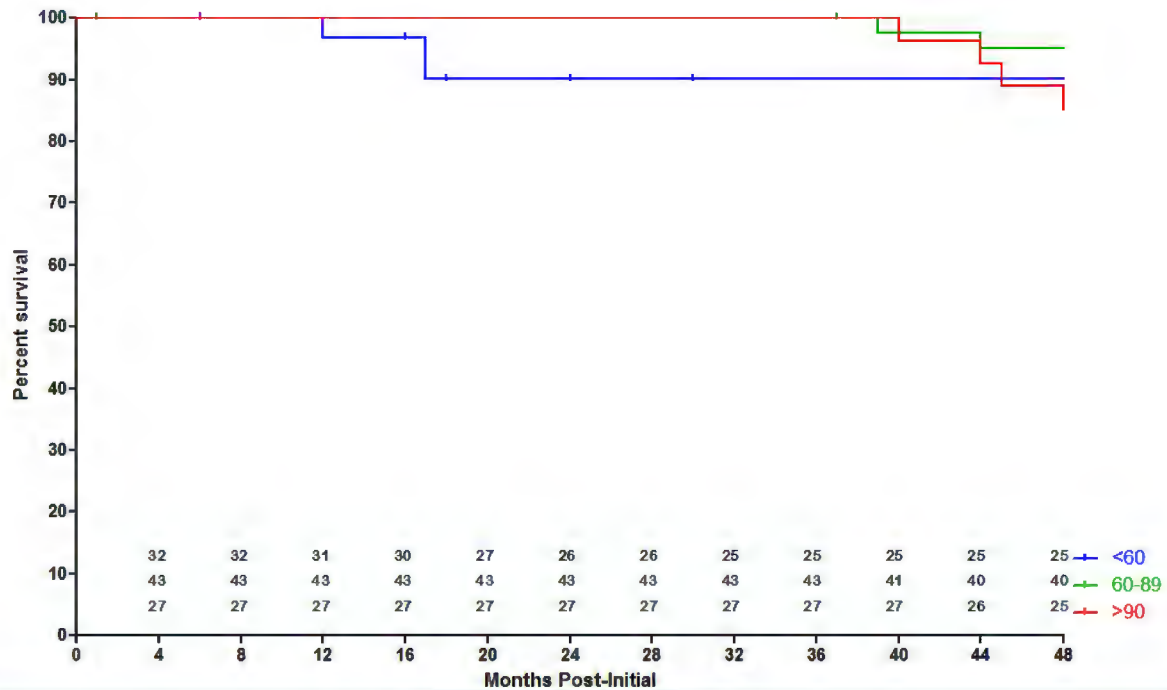


Fig 3. Secondary patency after ilio caval stenting for May-Thurner syndrome (MTS).

Stent outcomes

Patencies are depicted in Figs 1 to 3. There was no statistically significant difference in primary patency between mild, moderate, and severe stenosis groups. The median patencies in the three groups were 88 ± 17 months, 93 ± 13 months, and 96 ± 21 months for the mild, moderate, and severe stenosis groups, respectively (P > .05). Primary assisted patency was also not statistically significantly different across the groups (35 ± 7 months, 38 ± 6 months, and 47 ± 5 months for mild, moderate, and severe stenosis groups). Secondary patency demonstrated a similar picture with no difference in median patency between the three groups (8 ± 2 months, 20 ± 9 months, and 38 ± 5 months for mild, moderate, and severe stenosis groups; P > .05).

Risk factors for reintervention in MTS

Sex, age, thrombophilia, and degree of stenosis were evaluated as potential predictors for reintervention after

stenting for MTS (Table IV). However, logistic regression analysis did not demonstrate a statistically significant predictor. There was no difference in the reintervention rates between the three groups. In addition, there did not appear to be a difference in reintervention rates based on nature of stenting (Wallstent alone vs Wallstent-Z stent combination) across all three groups (Table V).

DISCUSSION

Endovenous techniques have supplanted open surgery as the treatment of choice in patients with MTS presenting with disabling symptoms. Whereas better outcomes have been reported with stenting for MTS compared with stenting for post-thrombotic syndrome, it is not known whether the degree of stenosis in MTS itself has an impact on such outcomes. Such data would help provide prognosis data to patients under consideration for ilio caval stenting.

Table V. Reintervention for Wallstent and Wallstent-Z stent combination across the three groups

Type of stent	Reintervention, No.		
	<60%	60%-89%	≥90%
Wallstent alone	49	79	55
Wall stent reintervention	22	40	35
Wallstent + Z stent	6	8	5
Wallstent + Z stent reintervention	5	8	2
Total patients	55	87	60
Total reinterventions	27	48	37

Table IV. Results of multivariable regression analysis: Predictors for reintervention

Variable	OR	95% CI		P value
		Lower	Upper	
Sex	1.3	0.6	2.8	.4
Age	0.7	0.5	1.3	.3
Thrombophilia	0.9	0.4	2.7	.9
Degree of stenosis	1.3	0.8	1.8	.1

CI, Confidence interval; OR, odds ratio.

Impact of degree of stenosis on clinical presentation and outcomes. As noted from Table II, there is no difference in the baseline clinical presentation between the groups, indicating that the degree of stenosis probably does not affect the initial clinical picture. After stenting, there is relief of symptoms across all groups until the 24-month follow-up. However, on long-term follow-up (48 months), the severe stenosis group appears to have recurrence of symptoms, including pain and swelling. There is also a decline of the VCSS metric in this group to the point of no statistically significant benefit at 48 months of follow-up. It appears that patients with severe MTS have a statistically significant recurrence of symptoms on long-term follow-up compared with the mild and moderate stenosis cohorts.

Impact of degree of stenosis on stent outcomes. On evaluation of primary, primary assisted, and secondary patencies, there does not appear to be an impact of degree of stenosis in MTS on such patencies. A statistically significant difference was not noted for patencies across the three groups. Whereas the severe stenosis group may have had recurrent symptoms, this has not come at the cost of loss of stent patency. Logistic regression was used to determine predictors for reintervention in the entire cohort. However, none of the variables examined appeared to be statistically significant predictors for reintervention. Whereas the degree of stenosis had an odds ratio of 1.3, the *P* value of 0.1 did not lend support to presence of an impact of such stenosis on stent reinterventions. No impact was noted on stent outcomes based on type of stenting (Wallstent alone vs Wallstent-Z stent combination), although the latter group constituted only a small number, making it difficult to draw a firm conclusion.

The degree of stenosis in MTS is a predictor for clinical recurrence of symptoms on long-term follow-up. Our hypothesis is that this symptom recurrence is due to reduction in the caliber of the stent over time in the severe stenosis group compared with the mild and moderate stenosis groups, reflecting greater extrinsic compression from a greater degree of stenosis.

CONCLUSIONS

Severity of MTS stenosis is not a predictor of initial clinical symptoms. Long term, patients with $\geq 90\%$ initial MTS stenosis experience recurrence of symptoms. The degree of iliac venous stenosis does not appear to affect stent patency. Such information will help counsel patients before intervention.

AUTHOR CONTRIBUTIONS

Conception and design: AJ

Analysis and interpretation: AJ, WB, AK, SR

Data collection: AJ, WB, AK, BJ

Writing the article: AJ, WB, AK, BJ, SR

Critical revision of the article: AJ, SR

Final approval of the article: AJ, WB, AK, BJ, SR

Statistical analysis: AJ, WB, AK, BJ

Obtained funding: Not applicable

Overall responsibility: AJ

REFERENCES

1. McMurrich JP. The occurrence of congenital adhesions in the common iliac veins and their relation to thrombosis of the femoral and iliac veins. *Am J Med Sci* 1908;135:342-6.
2. Ehrich WE, Krumbhaar EB. A frequent obstructive anomaly of the mouth of the left common iliac vein. *Am Heart J* 1943;26:737-50.
3. May R, Thurner J. The cause of the predominantly sinistral occurrence of thrombosis of the pelvic veins. *Angiology* 1957;8:419-27.
4. Negus D, Fletcher EW, Cockett FB, Thomas ML. Compression and band formation at the mouth of the left common iliac vein. *Br J Surg* 1968;55:369-74.
5. Pinsolle J, Drouillard J, Grenier F, Videau G, Cabanié H. Internal arrangement of the union between iliac vein and inferior vena cava. *Anat Clin* 1982;4:295-306.
6. Mitsuoka H, Ohta T, Hayashi S, Yokoi T, Arima T, Asamoto K, et al. Histological study on the left common iliac vein spur. *Ann Vasc Dis* 2014;7:261-5.
7. Cockett FB, Thomas ML. The iliac compression syndrome. *Br J Surg* 1965;52:816-21.
8. Cockett FB, Thomas ML, Negus D. Iliac vein compression.—Its relation to iliofemoral thrombosis and the post-thrombotic syndrome. *Br Med J* 1967;2:14-9.
9. Kibbe MR, Ujiki M, Goodwin AL, Eskandari M, Yao J, Matsumura J. Iliac vein compression in an asymptomatic patient population. *J Vasc Surg* 2004;39:937-43.
10. Crowner J, Marston W, Almeida J, McLafferty R, Passman M. Classification of anatomic involvement of the ilio caval venous outflow tract and its relationship to outcomes after ilio caval venous stenting. *J Vasc Surg Venous Lymphat Disord* 2014;2:241-5.
11. Titus JM, Moise MA, Bena J, Lyden SP, Clair DG. Iliofemoral stenting for venous occlusive disease. *J Vasc Surg* 2011;53:706-12.
12. Knipp BS, Ferguson E, Williams DM, Dasika NJ, Cwikiel W, Henke PK, et al. Factors associated with outcome after interventional treatment of symptomatic iliac vein compression syndrome. *J Vasc Surg* 2007;46:743-9.
13. Neglen P, Hollis KC, Olivier J, Raju S. Stenting of the venous outflow in chronic venous disease: long-term stent-related outcome, clinical, and hemodynamic result. *J Vasc Surg* 2007;46:979-90.
14. Hartung O, Loundou AD, Barthelemy P, Arnoux D, Boufi M, Alimi YS. Endovascular management of chronic disabling ilio-caval obstructive lesions: long-term results. *Eur J Vasc Endovasc Surg* 2009;38:118-24.
15. Rosales A, Sandbaek G, Jorgensen JJ. Stenting for chronic post-thrombotic vena cava and iliofemoral venous occlusions: mid-term patency and clinical outcome. *Eur J Vasc Endovasc Surg* 2010;40:234-40.
16. Gutzeit A, Zollikofer ChL, Dettling-Pizzolato M, Graf N, Largiader J, Binkert CA. Endovascular stent treatment for symptomatic benign iliofemoral venous occlusive disease: long-term results 1987-2009. *Cardiovasc Intervent Radiol* 2011;34:542-9.
17. Meng QY, Li XQ, Qian AM, Sang HF, Rong JJ, Zhu LW. Endovascular treatment of iliac vein compression syndrome. *Chin Med J (Engl)* 2011;124:3281-4.

18. Ye K, Lu X, Li W, Huang Y, Huang X, Lu M, et al. Long-term outcomes of stent placement for symptomatic non-thrombotic iliac vein compression lesions in chronic venous disease. *J Vasc Interv Radiol* 2012;23:497-502.
19. Alhalbouni S, Hingorani A, Shiferson A, Gopal K, Jung D, Novak D, et al. Iliac-femoral venous stenting for lower extremity venous stasis symptoms. *Ann Vasc Surg* 2012;26:185-9.
20. de Wolf MA, de Graaf R, Kurstjens RL, Penninx S, Jalaie H, Wittens CH. Short-term clinical experience with a dedicated venous nitinol stent: initial results with the sinus-Venous stent. *Eur J Vasc Endovasc Surg* 2015;50:518-26.
21. Raju S, Buck WJ, Crim W, Jayaraj A. Optimal sizing of iliac vein stents. *Phlebology* 2018;33:451-7.
22. Neglen P, Raju S. Balloon dilation and stenting of chronic iliac vein obstruction: technical aspects and early clinical outcome. *J Endovasc Ther* 2000;7:79-91.
23. Neglen P, Berry MA, Raju S. Endovascular surgery in the treatment of chronic primary and post-thrombotic iliac vein obstruction. *Eur J Vasc Endovasc Surg* 2000;20:560-71.
24. Raju S, Neglen P. High prevalence of nonthrombotic iliac vein lesions in chronic venous disease: a permissive role in pathogenicity. *J Vasc Surg* 2006;44:136-43; discussion: 144.
25. Neglen P, Tackett TP Jr, Raju S. Venous stenting across the inguinal ligament. *J Vasc Surg* 2008;48:1255-61.
26. Raju S, Darcey R, Neglen P. Unexpected major role for venous stenting in deep reflux disease. *J Vasc Surg* 2010;51:401-8; discussion: 408.
27. Raju S. Long-term outcomes of stent placement for symptomatic nonthrombotic iliac vein compression lesions in chronic venous disease. *J Vasc Interv Radiol* 2012;23:502-3.
28. Raju S. Best management options for chronic iliac vein stenosis and occlusion. *J Vasc Surg* 2013;57:1163-9.
29. Raju S, Ward M Jr, Kirk O. A modification of iliac vein stent technique. *Ann Vasc Surg* 2014;28:1485-92.
30. Iftikhar O, Oliveros K, Tafur AJ, Casanegra AI. Prevention of femoropopliteal in-stent restenosis with cilostazol: a meta-analysis. *Angiology* 2016;67:549-55.
31. Takigawa T, Tsurushima H, Suzuki K, Tsuruta W, Nakamura K, Matsumura A. Cilostazol suppression of arterial intimal hyperplasia is associated with decreased expression of sialyl Lewis X homing receptors on mononuclear cells and E-selectin in endothelial cells. *J Vasc Surg* 2012;55:506-16.
32. Kudo FA, Kondo Y, Muto A, Miyazaki K, Dardik A, Nishibe M, et al. Cilostazol suppresses neointimal hyperplasia in canine vein grafts. *Surg Today* 2009;39:128-32.
33. Jang JS, Jin HY, Seo JS, Yang TH, Kim DK, Kim DS, et al. A meta-analysis of randomized controlled trials appraising the efficacy and safety of cilostazol after coronary artery stent implantation. *Cardiology* 2012;122:133-43.
34. Raju S, Perry JT. The response of venous valvular endothelium to autotransplantation and in vitro preservation. *Surgery* 1983;94:770-5.

Submitted Jun 4, 2018; accepted Oct 1, 2018.