

Iliofemoral venous configurations from three-dimensional computed tomography venogram and their relevance to stent design

Arjun Jayaraj, MD, and Seshadri Raju, MD, Jackson, MS

ABSTRACT

Objective: Iliofemoral venous stenting has become the standard of care for patients presenting with quality-of-life impairing symptoms of chronic iliofemoral venous obstruction not responding to conservative measures. This has led to an increased use of venous stenting over the last several years. However, iliofemoral venous anatomy in patients requiring such intervention remains poorly elucidated. This study attempts to fill that gap.

Methods: Twenty-two consecutive patients with intravascular ultrasound examination-confirmed chronic iliofemoral venous obstruction underwent three-dimensional reconstruction of their computed tomography venogram images. Relevant angles, tortuosity (tort index-ratio between centerline length, and straight line length), lengths, and diameters were computed and analyzed. We used *t* tests for comparisons between the right and left sides. A *P* value of .05 or less was considered significant.

Results: Of the angles calculated, the median of the angles between the horizontal and common iliac vein (CIV) was 66° on the right and 60° on the left (*P* < .01). The median inferior vena cava-CIV angle was 172° on the right and 165° on the left (*P* < .0001). The CIV-EIV angle was 159° on the right and 151° on the L (*P* = .01). Overall, the median tortuosity was 1.07 on the right and 1.12 on the left (*P* = .007). The median centerline length of the CIV was 42mm on the right and 60mm on the left (*P* < .0001). The median external iliac vein length was 73 mm on the right and 88 mm on the left (*P* < .0001). The overall median iliac vein length was 220 mm on the right and 237 mm on the left (*P* < .01). The median diameters of the inferior vena cava at the ilio caval confluence, 20, 40, and 60 mm cranial to the confluence, were 23, 20, 22, and 23 mm, respectively.

Conclusions: Overall, the left side has steeper angles, greater tortuosity, and longer lengths than the right side. These disparities should be considered during femoroiliocaval stent construction. (*J Vasc Surg Venous Lymphat Disord* 2022;10:1310-7.)

Keywords: Iliac vein stenting; May Thurner syndrome; Post thrombotic syndrome; Non thrombotic iliac vein lesion; Venous stent design; Femoro-ilio-caval stent configurations

Femoroiliocaval venous stenting for the treatment of chronic venous insufficiency arising from iliofemoral venous obstruction has increased tremendously over the last two decades.¹⁻¹⁰ Recent years have witnessed the introduction of dedicated venous stents. However, variation in the angles, tortuosity, lengths, and diameters of the femoroiliocaval system in patients undergoing intervention remain unexplored. Such metrics will help to shed light on the appropriate configuration(s) required of venous stents and are the goal of this study. The authors used three-dimensional (3D) reconstruction of computed

tomography venograms (CTV) of patients who eventually underwent stenting to evaluate these metrics. An additional challenge that often presents itself is stenting across the ilio caval confluence. Currently available, dedicated venous stents are unable to handle the confluence adequately, especially in cases where stents have to be extended well into the inferior vena cava (IVC). The authors, based on data from this study and their extensive experience with femoroiliocaval stenting, suggest a configuration that might have the potential to address the challenge posed by the ilio caval confluence.

METHODS

Study design

Twenty-two consecutive patients with intravascular ultrasound (IVUS) examination-confirmed chronic iliofemoral venous obstruction (CIVO) who had undergone CTV as part of their workup underwent 3D reconstruction of their CTV images. Relevant lengths, angles, tortuosity, and diameters were computed and analyzed. A previous publication involving the same cohort had evaluated the

From The RANE Center for Venous & Lymphatic Diseases, Jackson, MS

Author conflict of interest: none.

Additional material for this article may be found online at www.jvsvenous.org.

Correspondence: Arjun Jayaraj, MD, The RANE Center, 971 Lakeland Dr, Ste #401, Jackson, MS 39216 (e-mail: jayaraj.arjun2015@gmail.com).

The editors and reviewers of this article have no relevant financial relationships to disclose per the Journal policy that requires reviewers to decline review of any manuscript for which they may have a conflict of interest.

2213-333X

Copyright © 2022 by the Society for Vascular Surgery. Published by Elsevier Inc.

<https://doi.org/10.1016/j.jvs.2022.04.021>

role of 3D CTV and found that it enables accurate diagnosis and treatment of patients presenting with symptomatic CIVO.¹¹

Setting

The center is a tertiary center for the management of venous and lymphatic disorders.

Participants

Patients presenting with quality-of-life-impairing symptoms suggestive of CIVO who had failed conservative therapy formed the study cohort. Lower extremity symptoms included pain, heaviness, tiredness, venous claudication, swelling, hyperpigmentation, lipodermatosclerosis, and/or venous leg ulcers. Patients who had stenting performed in the setting of acute iliofemoral deep venous thrombosis or recanalization of chronic total occlusion of the iliofemoral segment were excluded.

Patient consent was obtained for diagnostic testing and intervention. St. Dominic Hospital Institutional Review Board approval was obtained for dissemination of deidentified patient data.

CTV

CTV were performed on the 128-slice Siemens scanner (Siemens Healthineers, Erlangen, Germany) using the Stanford protocol. Five-millimeter slices were obtained and 3D reconstruction was performed and evaluated using M2S software (M2S Inc. West Lebanon, NH).

Stent technique

After appropriate venous access was obtained (femoral vein or popliteal vein, depending on inflow) using ultrasound guidance, a venogram was performed followed by IVUS. Although the venogram was used to assess flow dynamics, IVUS examination was used to confirm the diagnosis. Once the diagnosis was confirmed, predilation and stenting were carried out. Predilation was performed typically using a 16- to 18-mm Atlas Gold angioplasty balloon (Becton, Dickinson and Company, Franklin Lakes, NJ). Stenting was then pursued using a composite Wallstent (Boston Scientific, Marlborough, MA)-Z stent (Cook Medical, Bloomington, IN) configuration (Supplementary Fig, online only). The diameter of the Wallstents used ranged from 14 to 24 mm and that for the Z stent ranged from 20 to 30 mm. The number of stents used depended on the native vein segment length that required coverage. The goal of stenting was to cover all areas of disease from an area of good inflow to an area of good outflow. Post dilation was accomplished using the previously used angioplasty balloon and was followed by a completion venogram and IVUS examination. The details of our stent technique have been described previously.^{8,12,13}

Measurements

Angles. Angles computed included the following (Fig 1):

ARTICLE HIGHLIGHTS

- **Type of Research:** Single-center analysis of prospectively collected data
- **Key Findings:** In the femoroiliocaval segment, the left side has steeper angles, greater tortuosity, and longer lengths than the right side. These factors should be considered when designing and constructing venous stents.
- **Take Home Message:** Femoroiliocaval stent construction should take into account the disparities in the angles, tortuosity, and lengths between the right and left sides.

Angle A1: Angle on the same slice between the horizontal and the centerline through the right common iliac vein (CIV) (Fig 1). The extent of the centerline for this calculation was from the iliocaval confluence to 10 mm below the confluence in the right CIV.

Angle A2: Angle on the same slice between the horizontal and the centerline through the left CIV (Fig 1). The extent of the centerline for this calculation was from the iliocaval confluence to 10 mm below the confluence in the left CIV.

Angle A3: Angle formed by the union of the right and left CIV centerlines drawn as noted (Fig 1).

IVC-CIV angle: This angle was computed as the most severe (steepest) angle on the centerline between the iliac confluence (start of the IVC) and the cranial external/internal iliac venous confluence (start of the CIV) on each side. This angle is likely a compound angle. On the right side, this was the right IVC-CIV angle, and on the left, it was the left IVC-CIV angle (Fig 2).

External iliac vein (EIV) to common femoral vein (CFV) angle: This angle was computed as the most severe (steepest) angle on the centerline between the caudal external/internal iliac venous confluence (cranial end of the EIV) and the cranial femoral vein/profunda femoris vein confluence (start of CFV) on each side. This angle is also likely to be a compound angle. On the right side, this was the right EIV-CFV angle and on the left it was the left EIV-CFV angle (Fig 2).

Tortuosity. Tortuosity was evaluated by comparing the centerline length with the straight-line length. This parameter, termed the tort index, was measured for the common iliac segment and the entire iliac segment on both sides resulting in four tort indices—the right common iliac, left common iliac, right iliac and left iliac segments.

Lengths. Center line lengths (lengths obtained along the central axis of the vessel generated by the use of 3D reconstruction software) were computed for the CIV, EIV, and the entire iliac segment on the right and left sides. Additionally, corresponding straight line lengths (length of the straight line drawn between two points,

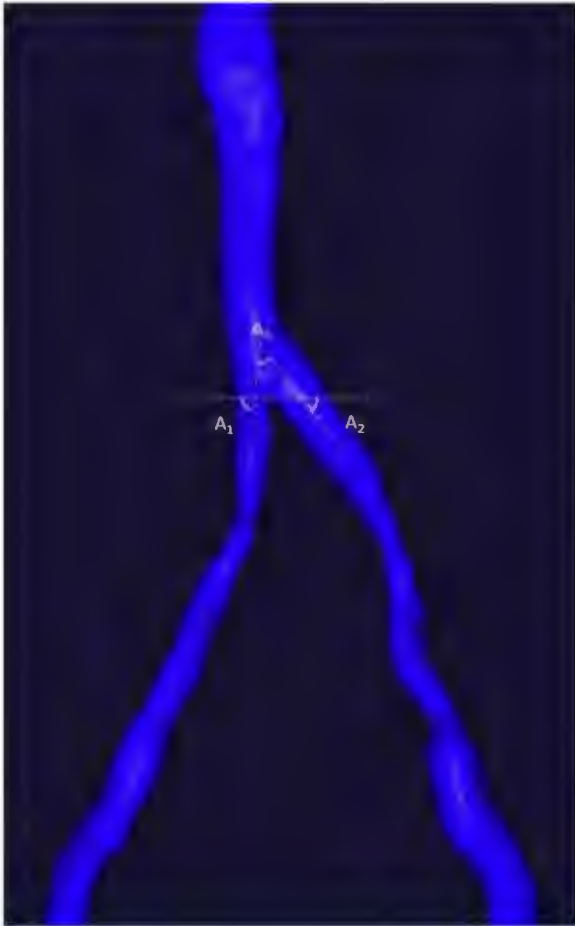


Fig 1. Angle A1. Angle on the same slice between the horizontal and the centerline through the right common iliac vein (CIV). The extent of the centerline for this calculation was from the iliocaval confluence to 10 mm below the confluence in the right CIV. Angle A2. Angle on the same slice between the horizontal and the centerline through the left CIV. The extent of the centerline for this calculation was from the iliocaval confluence to 10 mm below the confluence in the left CIV. Angle A3. Angle formed by the union of the right and left CIV centerlines drawn as noted.

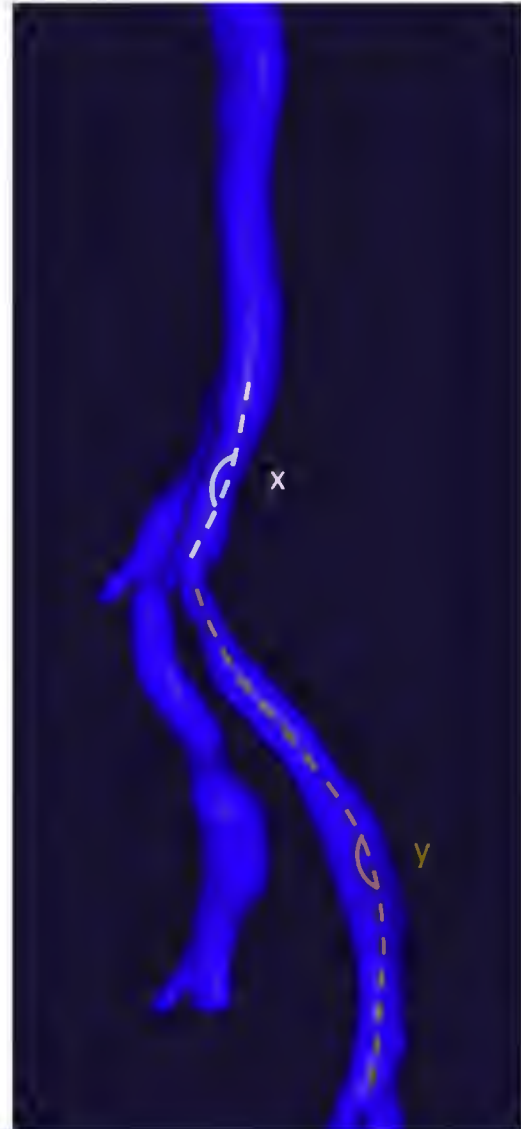


Fig 2. X marks the inferior vena cava (IVC) and common iliac vein (CIV) angle. This angle was computed as the most severe (steepest) angle on the centerline between the iliac confluence (start of the IVC) and the cranial external/internal iliac venous confluence (start of the CIV) on each side. The median of the IVC-right CIV angles was 172°. The median of the corresponding angles on the left side was 165°. Y marks the EIV to the common femoral vein (CFV) angle. This angle was computed as the most severe (steepest) angle on the centerline between the caudal external/internal iliac venous confluence (cranial end of the EIV) and the cranial femoral vein/profunda femoris vein confluence (start of the CFV) on each side. The median of the angles formed between the right CIV and the right EIV was 159°. The median of the corresponding angles on the left was 151°.

one at the start and the second at the end of the vessel segment) were calculated. The length of the iliofemoral Wallstent column after stenting was also determined. This was done using the markings on the IVUS catheter after stent deployment. Another length computed was the distance between the iliocaval confluence and the renal veins. This length was computed from the horizontal line through the inferior most point where the caval walls became parallel to the entry of the lowest renal vein into the IVC.

Diameters. Diameters were computed at multiple levels in the IVC. Diameters were not computed in the CIV, EIV, or CFV because the patient cohort had IVUS-confirmed CIVO and because of the high incidence of bilateral obstruction generally noted in such patients.^{8,14}

Statistical analyses

All statistical analyses were performed using SPSS statistics version 26 (IBM Corp. Armonk, NY). We carried out *t* test comparisons between relevant metrics on the right and left sides. Median values with range have

Table I. Description of iliac vein lengths both centerline and straight line

	Median centerline length, mm (range)			Median straight line length, mm (range)		
	Right	Left	P value	Right	Left	P value
CIV	42 (30-51)	60 (36-84)	<.0001	42 (30-50)	58 (35-83)	<.0001
EIV	73 (57-84)	88 (71-113)	<.0001			
Entire iliac segment	220 (175-257)	237 (179- 264)	.01	205 (167-246)	216 (164-245)	.2

CIV, Common iliac vein; EIV, external iliac vein.

been noted when appropriate. A *P* value of .05 or less was considered significant.

RESULTS

The median age of the cohort was 63 years (range, 34-76 years). There were 7 men (32%) and 15 women (68%). The median body mass index was 39 (range, 27-51). The left leg was treated in 13 (59%) and the right in 9 (41%). Seven limbs (32%) had nonthrombotic iliac vein lesions and 15 (68%) had post-thrombotic syndrome. The distribution of the Clinical (C), Etiological (E), Anatomical (A), and Pathophysiological (P) classification (CEAP) clinical class was 1 C3 (4%), 16 C4 (73%), 2 C5 (9%), and 3 C6 (14%) disease. There were no CEAP clinical class 0 to 2 patients.

Iliocaval angles. A diagrammatic description of the angles is provided in Figs 1 and 2. The median of angles A1 (angle on the same slice between the horizontal and the centerline through the right CIV) was 66° (range, 55°-76°). The median of the corresponding angles on the left side (A2) was 60° (range, 43°-73°) with a significant difference between the two sides (*P* = .01). The median of the angles formed between the centerlines of the right CIV and the left CIV (A3) was 47° (range, 26°-74°).

The median of the IVC-right CIV angles was 172° (range, 164°-177°). The median of the corresponding angles on the left side was 165° (range, 149°-176°) (*P* < .0001). The median of the angles formed between the right CIV and the right EIV was 159° (range, 144°-169°). The median of the corresponding angles on the left was 151° (range, 132°-169°) with a significant difference between the two sides (*P* = .01).

Tortuosity index. The median of the ratio between the centerline length and the straight line length (Tort index) was 1.0 for the right CIV (range, 0.98-1.01) and 1.01 (range, 0.99-1.05) for the left CIV (*P* < .0001). For the entire iliac venous segment, the median of the tort indices on the right was 1.07 (range, 1.01-1.15) and on the left was 1.12 (range, 1.05-1.22) (*P* = .007).

Diameters. The median of the IVC diameters at the ilio-caval confluence in the 22 patients was 23 mm (range, 17-28 mm), 20 mm cranial to the confluence it was 22 mm (range, 17-28 mm), 40 mm cranial to the confluence it

was 22 mm (range, 18-28 mm), and 60 mm cranial to the confluence it was 23 mm (range, 18-30 mm).

Lengths. On the right side the median centerline length of the CIV was 42 mm (range, 30-51 mm) and on the left this length was 60 mm (range, 36-84 mm) (*P* < .0001). On the right side the median straight line length of the CIV was 42 mm (range, 30-50 mm) and on the left this length was 58 mm (range, 35-83 mm) (*P* < .0001). The median centerline length of the EIV on the right was 73 mm (range, 57-84 mm) and on the left was 88 mm (range, 71-113 mm) (*P* < .0001).

Overall, the median centerline length of the entire iliac segment on the right was 220 mm (range, 175-257 mm) and on the left was 237 mm (range, 179-264 mm) (*P* = .01). Overall, the median straight length of the entire iliac segment on the right was 205 mm (range, 167-246 mm) and on the left was 216 mm (range, 164-245 mm) (*P* = .2) (Table I).

The median lengths of the stent column used to treat the 22 patients was 126 mm (range, 70-210 mm). The median length of the IVC from the confluence (parallel caval walls) to the entry of the lowest renal vein into the IVC was 81 mm (range, 58.8-99.2 mm).

DISCUSSION

Iliofemoral venous stenting has become the standard of care for the treatment of CIVO in patients with quality-of-life-impairing symptoms who have failed conservative treatment. Stent technology has progressed from the use of nondedicated stents to dedicated venous stents. Despite these advances, questions persist regarding the ideal configuration of a venous stent in the iliofemoral system and ways to manage the ilio-caval confluence. For these questions to be answered, a careful consideration of the variation in angles, tortuosity, lengths, and diameters of the femoroilio-caval system in patients undergoing intervention needs to be made. In this study, this issue was addressed through use of reconstructed cross-sectional CTV images.

Lengths. The lengths that were considered were that of the common iliac segment, the external iliac segment and the combined (entire) iliac segment. The centerline length of the CIV segment on the right side is shorter than the left side by almost 18 mm (*P* < .0001). This

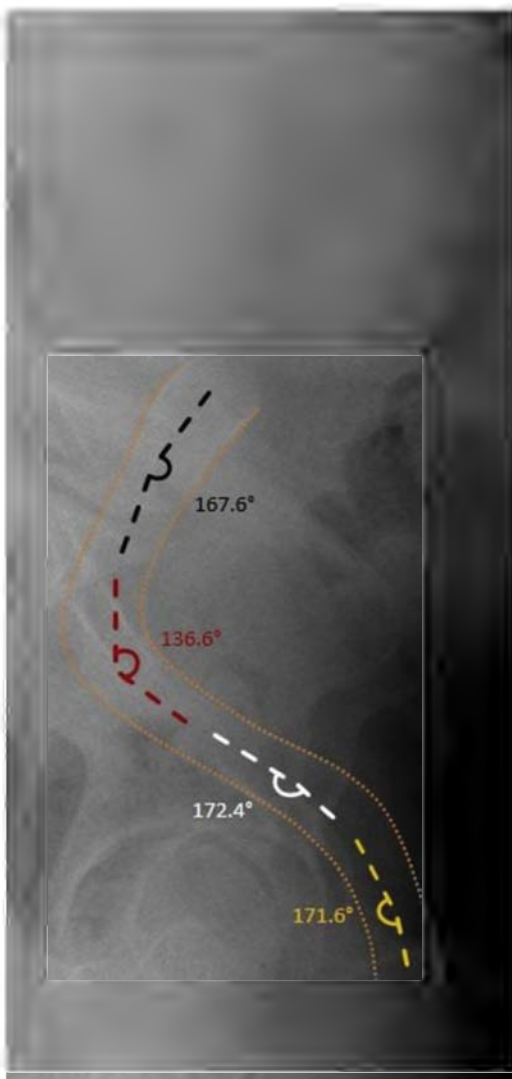


Fig 3. Lateral view radiograph demonstrating the tortuosity of the femoroiliacal segment with depiction of angulation at multiple points following deployment of a self-expanding woven stent (Wallstent).

remained true even when using straight line measurements with the right side shorter by 16 mm ($P < .0001$). This finding is relevant when there is the possibility that the internal iliac may have to be embolized for pelvic venous reflux. Otherwise, coverage of the internal iliac vein is routine during iliofemoral venous stenting and does not result in adverse consequences. The centerline length of the EIV on the right was again shorter than the left by approximately 12 mm ($P < .0001$). Overall, the median centerline length of the entire iliac segment on the right was shorter than the left by approximately 17 mm ($P = .01$). This remained the case when median straight line measurements were compared (11 mm); however, this difference was not statistically significant ($P = .2$). This length discrepancy is reflective of the

increased tortuosity of the iliac segment on the left compared with the right.

Angles. The angles were computed vein on vein (instead of using bony landmarks) because their computation from centerline measurements are less prone to error. When assessed with the horizontal drawn through the iliocaval confluence, the median of angles between this horizontal line and the centerline drawn through the CIV on the right was 66° and, on the left was 60° , with a significant difference between the two sides ($P = .01$). This finding indicates that the left CIV has a more acute union with the IVC than the right. This observation is in concordance with another study that previously reported the angles on the left being more acute.¹⁵ The median of the angles formed between the centerlines of the right CIV and the left CIV was 47° . The absence of severe steepness of this angle is important when configuring stents to traverse the confluence. The union of the two CIV at this angle makes the ostium of the ipsilateral stent (into which the contralateral stent can be placed into) easier to fashion to facilitate entry from the contralateral side.

When the centerlines of the IVC and CIV were used to determine angles, the median of such angles on the right was 172° and on the left side was 165° ($P < .0001$). Although this difference is statistically significant, the small size of the difference (7°) does not add to the complexity of the stent configuration required to handle the confluence. When the centerline angles between the CIV and the EIV were determined, the median of the angles on the right 159° , whereas the median of the corresponding angles on the left was 151° ($P = .01$). Here again, although there is statistical significance, the actual difference is small (8°). Although this latter angle may not impact the confluence, it contributes to the overall angulation in the iliac segment.

Tortuosity. The median of the ratio between the centerline length and the straight line length (Tort index) was 1.0 for the right CIV and 1.01 for the left CIV ($P < .0001$). For the entire iliac venous segment, the tort index on the right was 1.07 and on the left was 1.12 ($P = .007$). This finding indicates increased tortuosity on the left compared with the right and the need for good flexibility in any venous stent. A stent with enough flexibility to handle the left iliofemoral segment should be able to negotiate the less tortuous right segment as well. The tortuosity of the iliac segment can be gauged from a lateral view radiograph of a deployed self-expanding woven stent (Wallstent) (Fig 3).

Diameters. The IVC diameter varied minimally along its course, from 22 mm at the iliocaval confluence to 23 mm at 60 mm cephalad to the confluence. The stent size to be used in the IVC would correspond with these sizes

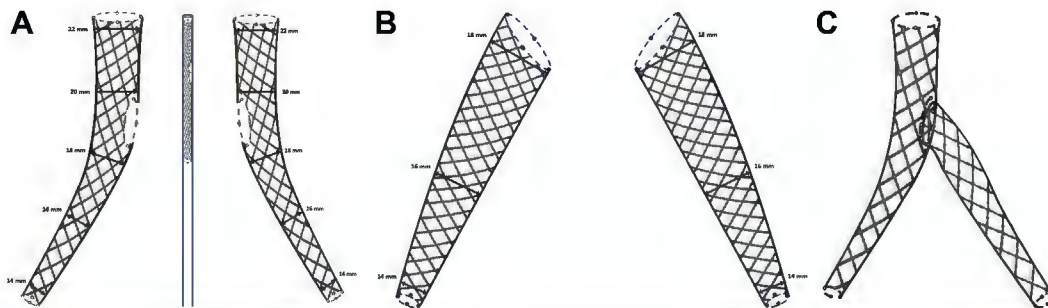


Fig 4. A, Prototype of a self-expanding woven stent design that can handle the ilio caval confluence (patent pending). There is a gradual taper in stent diameter from the inferior vena cava (IVC) to the common femoral vein (CFV). A side orifice that can be identified by radiopaque markers allows for contralateral outflow or contralateral stent deployment thereby reducing risk of development of contralateral symptoms and/or contralateral deep venous thrombosis. The left is a right-sided stent, the middle is the undeployed stent within the delivery system with radiopaque markers identified, and the right is a left-sided stent. **B**, Prototype of a single self-expanding woven daughter stent (patent pending). There is a gradual taper in the stent diameter from the common iliac vein (CIV) to the CFV. The left is a right-sided stent and the right is a left-sided stent. **C**, Iliocaval stent configuration after the deployment of a right-sided self-expanding woven parent ilio caval stent and a left sided self-expanding woven daughter stent (patent pending).

or be slightly larger, depending on the amount of oversizing selected.

Stent design. The ideal venous stent is one that can handle both stenotic and chronic total occlusive pathologies. The authors' experience with regard to the latter has been that a woven stent tends to have better outcomes after recanalization. This type of stent typically does well when it comes to handling stenotic lesions as well.^{1,8,14} This determination is based on the properties of a commonly used woven stent, the Wallstent. This stent, when fixated, has excellent crush resistance in addition to good radial resistive force and good chronic outward force. These properties have been considered by Dabir et al.¹⁶

The authors' conception of a self-expanding woven stent suitable for managing the ilio caval confluence is shown in Fig 4, A. The parent stent will have an orifice that can be identified by radiopaque markers and deployed to provide outflow to the contralateral CIV. If the contralateral side required stenting at the same time or subsequently, this can be accomplished by deploying the single self-expanding woven daughter stent (Fig 4, B) into the orifice with minimal extension (2 mm) across the radiopaque markers into the IVC (Fig 4, C). This way, isolated use of the parent limb does not result in an increased incidence of contralateral deep venous thrombosis or increased requirement of contralateral intervention, which is a problem with Wallstents that extend into the IVC.^{17,18} Additionally, given that the median length of the IVC from the confluence (parallel caval walls) to the entry of the lowest renal vein into the IVC was 81 mm, there is enough length in the IVC for adequate cranial landing zone without jailing the renal veins. The routine use of IVUS examination with

venous stenting should facilitate accurate stent deployment.^{11,14}

With regard to the diameters of such a stent, the authors suggest possible stent configurations in Table II. Fig 5 demonstrates reverse tapering of a Wallstent stent column through the stent sculpting technique (dilation of the cranial Wallstent with an angioplasty balloon larger than the rated stent diameter to overcome residual stent compression and create a widened flow channel) used by one of the authors (A.J.). In the authors' experience, such iatrogenic widening of the stent seems to be maintained months after creation and will help until reverse tapered stents are available commercially. Dedicated venous stents currently available in the United States that use open cell technology are less amenable to such sculpting. The median length of the stents used to treat the 22 patients was 126 mm (range, 70-210 mm). Allowing for a generous 3- to 4-mm extension into the IVC, the median available stent length should be approximately 130 mm. Other potential stent lengths could be 80, 160, and 190 mm. Such lengths would allow the overwhelming majority of patients to be treated with a single stent. This point is important, given the costs associated with the use of multiple stents. In general, owing to the tortuosity of the iliac vein, the greater the length of a given segment (ie, CIV or EIV), the greater the difference between centerline and straight line lengths. Measurement of required vein length to be stented using the IVUS catheter has been found to be very helpful.¹¹ Flexibility is another requisite characteristic given angles and tortuosity considered.

Recent data seem to show that woven stents are better than laser cut stents.^{19,20} Although the woven stent is more flexible, it is less precise when it comes to deployment. Data from Schwein et al¹⁹ show that laser cut

Table II. Possible stent configurations

	Tapered configurations diameter, mm, lower/mid/upper (femoroiliac)	Length, mm	Straight configurations stent extension diameters of 12-22 mm, mm
Type I	12/14/16	80, 130, 160, 190	40, 60, 80
Type II	14/16/18	80, 130, 160, 190	40, 60, 80
Type III	16/18/20	80, 130, 160, 190	40, 60, 80
Type IV	18/20/22	80, 130, 160, 190	40, 60, 80
Type V	20/22/24	80, 130, 160, 190	40, 60, 80
With caval extension	Lower/mid/uppercaval (femoroiliocaval)		
Type VI	14/16/18/20/22	140, 190, 220, 250	40, 60, 80
Type VII	16/18/20/22/24	140, 190, 220, 250	40, 60, 80

Types I-V are tapered configurations for the iliofemoral segment. Types VI-VII have additional caval configurations that allow for contralateral outflow/stenting. Lengths for femoroiliocaval stents (types VI-VII) allow for approximately 20 mm between the end of the stent and the original of the lowest renal vein. Stent extensions enable extending stent coverage in scenarios when the standard stent length comes short.

stents are helpful when more rigidity is required (eg, coronaries) and are less adaptable for implantation into a more compliant low-pressure venous system. Moeri et al²⁰ showed that the use of braided nitinol stents for common femoral venous obstruction had more favorable primary patency at 12 months compared with laser cut nitinol stents. Laser cut stents were particularly susceptible to fracture and stent occlusion,²⁰ demonstrating a greater than 20% incidence of adverse stent outcomes. The overwhelming majority of these were stent

occlusions (almost 20%), significantly higher than that reported with the use of Wallstents alone or a composite Wallstent-Z stent configuration.^{8,14,21} For symptomatic patients undergoing reintervention, Moeri et al²⁰ noted a CFV stent fracture rate of 4%. They concluded that stent fracture was a possible cause for loss of stent patency and that a braided nitinol stent represented a better venous stent option.²⁰ Dabir et al¹⁶ noted that the fixated Wallstent had better chronic outward force and crush resistance than most commercially available

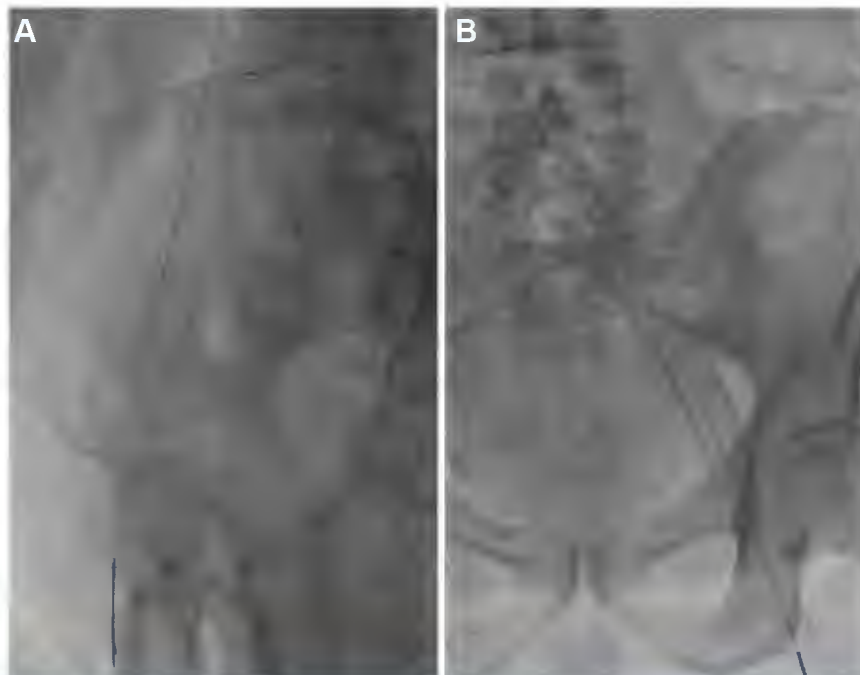


Fig 5. A, Lateral radiograph demonstrating the smooth tapering of a woven stent after deployment (Wallstent). Stent sculpting was carried out with dilation of the common iliac portion of the 20-mm stent with a 24-mm angioplasty balloon to overcome stent compression and create an adequate outflow channel. **B,** Anteroposterior view of another example of stent sculpting. Here a 22-mm Wallstent was angioplastied with a 24-mm angioplasty balloon.

laser cut nitinol venous stents besides good radial resistive force. Taking all these details into consideration, a self-expanding woven stent might, therefore, represent a better option as a suitable venous stent. The currently available Wallstent can be potentially be used as a platform for the construction of a more dedicated venous stent by the introduction of tapering diameters, longer lengths, and a contralateral outflow orifice. Additionally, based on the authors' experience, the precision of deployment could be improved with the use of a thumb-wheel deployment as opposed to a pinch and pull.

The future of venous stenting is likely going to be intertwined with 3D printing. This envisages a scenario when data from cross sectional imaging can be uploaded into a 3D printer and the venous stent printed for that particular patient. Disposable delivery systems will allow for sheathing of the stent on a delivery mandrel and subsequent deployment into the patient.

Limitations of the study includes its small sample size. Additionally, true stent behavior can only be gauged after in vivo deployment. Nevertheless, an ideal venous stent must take into account considerations accruing from femoroiliocaval anatomy.

CONCLUSIONS

Overall, the left iliofemoral venous segment has steeper angles, greater tortuosity, and longer lengths than the right side. These properties should be considered during venous stent construction, with an additional focus on the ability to manage the ilio caval confluence. A self-expanding woven stent with gradually increasing diameters from the femoral to the caval segment with an aperture to allow for contralateral outflow and/or deployment of the contralateral stent may best address these issues and also help to tackle the ilio caval confluence. Further research is required in this direction.

AUTHOR CONTRIBUTIONS

Conception and design: AJ

Analysis and interpretation: AJ, SR

Data collection: AJ

Writing the article: AJ

Critical revision of the article: AJ, SR

Final approval of the article: AJ, SR

Statistical analysis: AJ

Obtained funding: Not applicable

Overall responsibility: AJ

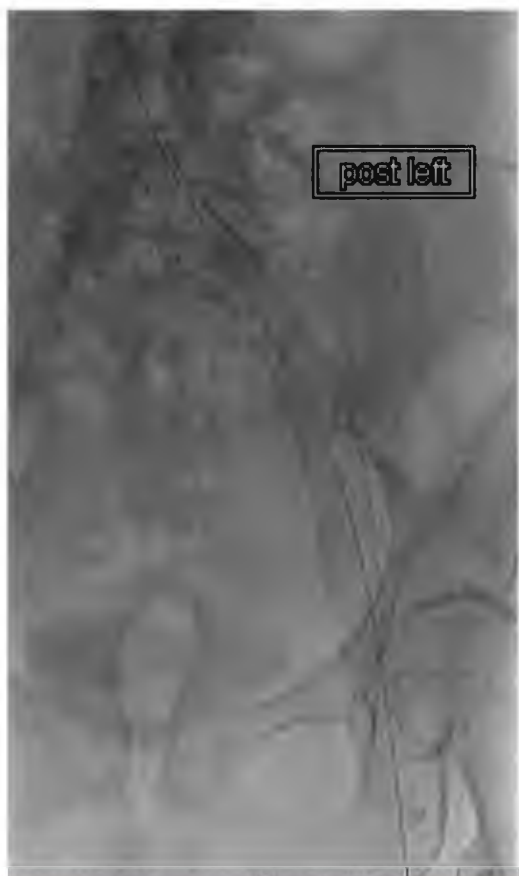REFERENCES

1. Hartung O, Loundou AD, Barthelemy P, Arnoux D, Boufi M, Alimi YS. Endovascular management of chronic disabling ilio-caval obstructive lesions: long-term results. *Eur J Vasc Endovasc Surg* 2009;38:118-24.
2. Cutzeit A, Zollikofer Ch L, Dettling-Pizzolato M, Graf N, Largiader J, Binkert CA. Endovascular stent treatment for symptomatic benign iliofemoral venous occlusive disease: long-term results 1987-2009. *Cardiovasc Intervent Radiol* 2011;34:542-9.

3. Ye K, Lu X, Li W, Huang Y, Huang X, Lu M, et al. Long-term outcomes of stent placement for symptomatic nonthrombotic iliac vein compression lesions in chronic venous disease. *J Vasc Interv Radiol* 2012;23:497-502.
4. Alhalbouni S, Hingorani A, Shiferson A, Gopal K, Jung D, Novak D, et al. Iliac-femoral venous stenting for lower extremity venous stasis symptoms. *Ann Vasc Surg* 2012;26:185-9.
5. de Wolf MA, de Graaf R, Kurstjens RL, Penninx S, Jalaie H, Wittens CH. Short-term clinical experience with a dedicated venous nitinol stent: initial results with the sinus-venous stent. *Eur J Vasc Endovasc Surg* 2015;50:518-26.
6. Qiu P, Zha B, Xu A, Wang W, Zhan Y, Zhu X, et al. Systematic review and meta-analysis of iliofemoral stenting for post-thrombotic syndrome. *Eur J Vasc Endovasc Surg* 2019;57:407-16.
7. Seager MJ, Busuttill A, Dharmarajah B, Davies AH. Editor's choice- a systematic review of endovenous stenting in chronic venous disease secondary to iliac vein obstruction. *Eur J Vasc Endovasc Surg* 2016;51:100-20.
8. Neglen P, Hollis KC, Olivier J, Raju S. Stenting of the venous outflow in chronic venous disease: long-term stent-related outcome, clinical, and hemodynamic result. *J Vasc Surg* 2007;46:979-90.
9. Jayaraj A, Buck W, Knight A, Johns B, Raju S. Impact of degree of stenosis in May-Thurner syndrome on iliac vein stenting. *J Vasc Surg Venous Lymphat Disord* 2019;7:195-202.
10. Rosales A, Sandbaek G, Jorgensen JJ. Stenting for chronic post-thrombotic vena cava and iliofemoral venous occlusions: mid-term patency and clinical outcome. *Eur J Vasc Endovasc Surg* 2010;40:234-40.
11. Jayaraj A, Raju S. Three-dimensional computed tomography venogram enables accurate diagnosis and treatment of patients presenting with symptomatic chronic iliofemoral venous obstruction. *J Vasc Surg Venous Lymphat Disord* 2021;9:73-80.e1.
12. Jayaraj A, Noel C, Raju S. Contralateral limb improvement after unilateral iliac vein stenting argues against simultaneous bilateral stenting. *J Vasc Surg Venous Lymphat Disord* 2020;8:565-71.
13. Jayaraj A, Powell T, Raju S. Utility of the 50% stenosis criterion in patients undergoing stenting for chronic iliofemoral venous obstruction. *J Vasc Surg Venous Lymphat Disord* 2021;9:1408-15.
14. Jayaraj A, Noel C, Kuykendall R, Raju S. Long-term outcomes following use of a composite Wallstent-Z stent approach to iliofemoral venous stenting. *J Vasc Surg Venous Lymphat Disord* 2021;9:393-400.e2.
15. Song X, Zheng Y, Song X, Wang X, Ye W. An image analysis of the major angles along the pathway of iliac veins involved in endovenous interventions. *J Vasc Surg Venous Lymphat Disord* 2021;9:81-7.
16. Dabir D, Feisst A, Thomas D, Luetkens JA, Meyer C, Kardulovic A, et al. Physical properties of venous stents: an experimental comparison. *Cardiovasc Intervent Radiol* 2018;41:942-50.
17. Murphy EH, Johns B, Varney E, Buck W, Jayaraj A, Raju S. Deep venous thrombosis associated with caval extension of iliac stents. *J Vasc Surg Venous Lymphat Disord* 2017;5:8-17.
18. Khairy SA, Neves RJ, Hartung O, O'Sullivan GJ. Factors associated with contralateral deep venous thrombosis after ilio caval venous stenting. *Eur J Vasc Endovasc Surg* 2017;54:745-51.
19. Schwein A, Georg Y, Lejay A, Nicolini P, Hartung O, Contassot D, et al. Endovascular treatment for venous diseases: where are the venous stents? *Methodist Debakey Cardiovasc J* 2018;14:208-13.
20. Moeri L, Lichtenberg M, Gnanapiragasam S, Barco S, Sebastian T. Braided or laser-cut self-expanding nitinol stents for the common femoral vein in patients with post-thrombotic syndrome. *J Vasc Surg Venous Lymphat Disord* 2021;9:760-9.
21. Jayaraj A, Crim W, Knight A, Raju S. Characteristics and outcomes of stent occlusion after ilio caval stenting. *J Vasc Surg Venous Lymphat Disord* 2019;7:56-64.

Submitted Jan 9, 2022; accepted Apr 27, 2022.

Additional material for this article may be found online at www.jvsvenous.org.



Supplementary Fig (online only). Composite Wallstent-Z stent configuration for symptomatic chronic iliofemoral venous obstruction (CIVO).