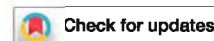

Grading venous stenosis is different from arterial lesions

Ghassan Kassab, PhD,^a and Seshadri Raju, MD, FACS,^b San Diego, Calif; and Jackson, Miss

Venous stenting is increasingly used to correct symptomatic iliac vein stenosis in chronic venous disease. A key unresolved issue is the assessment of stenosis severity and the degree of iliac stenosis that might merit stent correction. A 50% stenosis is commonly used as the threshold to indicate stenosis severity. This appears to be an arbitrarily chosen threshold as no explanation of its basis can be found in the literature.

VENOUS STENOSIS

The major difference between venous and arterial stenosis is that the flow direction is reversed. The point of interest is still the abnormalities in peripheral (tissue) perfusion. Flow and pressure *upstream* of the venous stenosis are the salient elements. Tissue perfusion is generally not compromised in chronic venous stenosis as venous collaterals are more abundant than in arteries.¹ However, conductance of the collaterals is often not enough to normalize elevated venous pressure, which is the basis of disease manifestations.^{2,3} There is a continuous gradual pressure increase upstream of a venous stenosis in experimental venous models.^{3,4} The curve is nonlinear without a clear inflection point, that is, there is no “critical” venous stenosis such as is seen in arterial stenosis. This difference is because the peripheral arterial bed exhibits powerful compensatory vasodilation in response to a flow-limiting arterial stenosis, whereas compensatory responses in the venous bed to outflow stenosis are weak or absent.

Peripheral venous pressure in the lower limb is influenced by many factors other than iliac stenosis, such as right atrial pressure, intra-abdominal pressure, and post-thrombotic changes that affect venous compliance. In case of heart failure or morbid obesity, these mechanisms may be important in peripheral venous hypertension. Iliac vein stenosis is usually the dominant pressure influence when it is present.⁵

How, then, can we assess the severity of iliac vein stenosis? Pressure gradients as used in arterial stenosis have proved useless to grade venous lesions.² Many authors use stenotic diameter (venography) or area measured by intravascular ultrasound (IVUS) to calculate percentage stenosis with adjacent “normal” lumen as a comparator. The problem with this approach is that there is no assurance that the normal lumen is indeed normal. Long diffuse stenosis without focal clues (Rokitansky stenosis) is a unique feature of iliac venous stenosis.⁵ Venographic appearance of such lesions can be deceptively normal; the presence of severe long stenosis comes to light only on IVUS planimetry. A more dependable method is to calculate percentage area stenosis on the basis of expected normal lumen size. Such an “optimal” lumen size for the various iliac-femoral vein segments can be calculated from flow equations using known normal values for flow and pressure.⁶ Calculated optimal areas closely correspond to IVUS-observed areas in non-stenotic normal iliac segments and comply with Young’s scaling rule. The optimal segmental calibers are the *minimum* necessary to maintain normal venous pressure. The concept of optimal outflow caliber to balance inflow and to maintain normal peripheral pressure can be shown in experimental flow models.³

ARTERIAL STENOSIS

Percentage area stenosis is the standard in assessing severity in arterial lesions. A clinician wants to know whether the stenosis is below or above the critical threshold to dictate treatment. Distal perfusion pressure remains largely unaffected until critical stenosis threshold is reached (Fig. A).¹ At the critical stenosis, there is a sudden drop in flow volume and pressure that will cause ischemia in the perfused territory. Flow and pressure drops are proportionally related through Poiseuille’s equation for a given flow resistance. For most arteries of clinical interest, the critical threshold centers around $\approx 70\% \pm 10\%$ area stenosis. There is some variation of the critical threshold because of differences in regional resistance and flow. The critical threshold as an empirical fact is well known, but the underlying reason for this phenomenon lies in the microvasculature.

The nonlinear flow-stenosis curves are due to *autoregulation* of the peripheral circulation. When there is increasing stenosis of the regional artery, there is corresponding compensatory relaxation of peripheral arterioles (in the perfusion bed of the regional artery) that lowers peripheral resistance. This compensatory mechanism offsets the effects of proximal stenosis, keeping flow across the stenosis relatively constant. This distal

From the California Medical Innovations Institute, San Diego^a; and The Rane Center at St. Dominic Hospital, Jackson.^b

Author conflict of interest: S.R. holds U.S. patents in intravascular ultrasound diagnostics and venous stent design and receives stock/royalty from Veniti.

Correspondence: Seshadri Raju, MD, FACS, The Rane Center at St. Dominic Hospital, 971 Lakeland Dr, Ste 401, Jackson, MS 39216 (e-mail: rajumd@earthlink.net).

The editors and reviewers of this article have no relevant financial relationships to disclose per the Journal policy that requires reviewers to decline review of any manuscript for which they may have a conflict of interest.

J Vasc Surg: Venous and Lym Dis 2019;7:151-2

2213-333X

Copyright © 2018 by the Society for Vascular Surgery. Published by Elsevier Inc. <https://doi.org/10.1016/j.jvsv.2018.07.020>

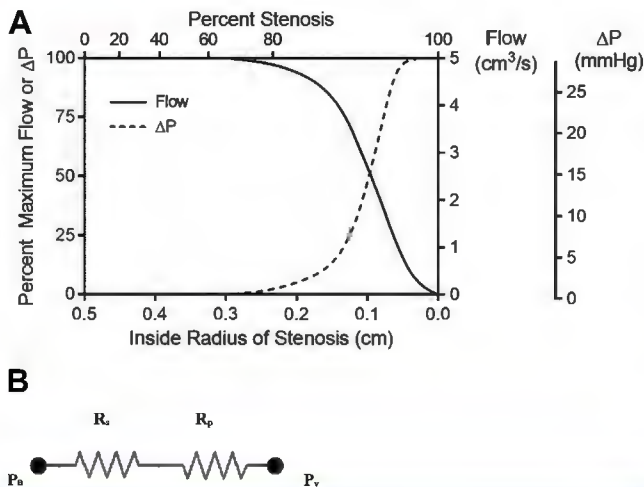


Fig. A. Relation between flow and pressure drop and percentage stenosis. For percentage stenosis <70%, the flow or pressure drop remains fairly constant. Further stenosis can yield significant drop in flow or pressure with a critical zone where the pressure drop or flow can be reduced to 0 at 100% stenosis. (Adapted from Strandness DE, Sumner DS. Hemodynamics for surgeons. New York: Grune & Stratton; 1975.) **B.** Ohm's law, electrical analogue for Poiseuille's equation is $P_a - P_v = Q(R_s + R_p)$, where Q = flow, P_a and P_v are arterial and venous pressures, and R_s and R_p are stenosis and peripheral arteriolar resistances, respectively. Normally, $R_s \ll R_p$ and hence any changes in R_s for percentage stenosis <70% do not affect the sum of the two resistors because R_p is very much higher than R_s . At the point at which R_s becomes similar to R_p , the sum of the two resistors can be changed by further increases in R_s and hence can lead to a reduction in Q because $Q = (P_a - P_v)/(R_s + R_p)$. In venous flow (not shown), resistances are low throughout, and there is no arteriolar resistance equivalent. A central venous stenosis can therefore significantly raise resistance and pressure without the lag leading up to criticality shown in (A).

vasodilation is "maxed out" at the critical threshold; that is, the resistance of the stenosis approaches that of dilated distal vasculature. Further increase of the stenosis results in flow loss and parallel pressure fall across the stenosis. It is important to remember that the pressure loss at issue is *downstream* of the stenosis affecting the perfused tissue. There is, of course, pressure change upstream, but it is buffered by baroreceptor and other reflexes and is generally well tolerated.

An easy way to understand the origin of the critical threshold is to view peripheral vascular resistance as a stenosis in aggregate. The reduction in mean arterial pressure from 100 mm Hg to 30 mm Hg across the peripheral arterioles (ΔP of 70%) represents a high-grade terminal stenosis in the artery. Any proximal tandem stenosis in the artery will have to be greater ($\geq 60\%$ -70%) to diminish perfusion further.

The phenomenon of critical threshold can be represented mathematically by the classic electrical theory analogue of arterial stenosis shown in Fig. B.

RECOMMENDATIONS

Most iliac vein stenoses are asymptomatic because of compensatory mechanisms such as collateralization, increase in lymph flow (up to 50 times), low tissue compliance, and other factors. There is no justification to correct these lesions in the absence of severe symptoms; that is, there is no role for prophylactic correction as in arterial lesions that threaten important regional perfusion. Leg swelling can occur in a variety of systemic diseases, but typical venous pain and skin changes are rarely present. Careful clinical assessment can usually confirm, or rule out, venous disease and narrow the differential diagnosis. In clinical series, median caliber reduction in iliac venous stenosis is in the range of 60% to 70%, but milder venous lesions occur in 10% to 15% of cases.^{7,8} This is probably because factors such as lesion length and poor compliance of the venous bed contribute to venous hypertension in addition to stenosis caliber. In limbs with extensive post-thrombotic changes, there is currently no reliable way to assess the relative importance of a coexisting central (iliac) stenosis separately from peripheral changes. Because only the central lesion is correctible, the best strategy is to ensure that an adequate (optimal) iliac outflow caliber is restored in such cases.⁹

REFERENCES

1. Strandness DE, Sumner DS. Hemodynamics for surgeons. New York: Grune & Stratton; 1975.
2. Neglen P, Raju S. Intravascular ultrasound scan evaluation of the obstructed vein. *J Vasc Surg* 2002;35:694-700.
3. Raju S, Crim W, Buck W. Factors influencing peripheral venous pressure in an experimental model. *J Vasc Surg Venous Lymphat Disord* 2017;5:864-74.
4. Raju S, Kirk O, Davis M, Olivier J. Hemodynamics of "critical" venous stenosis and stent treatment. *J Vasc Surg Venous Lymphat Disord* 2014;2:52-9.
5. Raju S, Davis M. Anomalous features of iliac vein stenosis that affect diagnosis and treatment. *J Vasc Surg Venous Lymphat Disord* 2014;2:260-7.
6. Raju S, Buck WJ, Crim W, Jayaraj A. Optimal sizing of iliac vein stents. *Phlebology* 2018;33:451-7.
7. Raju S. Best management options for chronic iliac vein stenosis and occlusion. *J Vasc Surg* 2013;57:1163-9.
8. Raju S, Oglesbee M, Neglen P. Iliac vein stenting in postmenopausal leg swelling. *J Vasc Surg* 2011;53:123-30.
9. Raju S, Ward M Jr, Davis M. Relative importance of iliac vein obstruction in patients with post-thrombotic femoral vein occlusion. *J Vasc Surg Venous Lymphat Disord* 2015;3:161-7.

Submitted Jun 12, 2018; accepted Jul 7, 2018.