

Clinical tolerance of untreated reflux after iliac vein stent placement

Taimur Saleem, MBBS, FACS, Michael Lucas, MS, David Thaggard, BS, Hunter Peebles, MS, Cooper Luke, MS, and Seshadri Raju, MD, FACS, Jackson, MS

ABSTRACT

Background: We have recently demonstrated in a large patient cohort that the prevalence and severity of reflux will improve in most limbs after stenting and that most limbs will not develop new-onset reflux. In the present report, we have focused on the long-term clinical outcomes associated with untreated reflux in the same patient cohort who had undergone iliofemoral venous stenting without correction of residual reflux.

Methods: The clinical outcomes data from 1379 limbs treated with only iliac vein stenting without correction of superficial or deep reflux from 1997 to 2018 were analyzed (23-year follow-up period). Of the 1379 limbs, 632 (46%) had had pre-existing reflux before stenting and 747 (54%) had did not. The reflux data (reflux segmental score, air plethysmography, ambulatory venous pressure) for these patients have been previously reported in detail. The subsets were compared perioperatively with each other using the following variables: grade of swelling, visual analog scale for pain score, venous clinical severity score, venous stasis dermatitis, ulceration, and quality of life measures.

Results: Both groups demonstrated improvements in the venous clinical severity score, grade of swelling, visual analog scale score, and quality of life. No differences were found in ulcer healing (5% vs 3% for limbs with and without pre-stent reflux, respectively) and resolution of dermatitis (6% vs 5% for limbs with and without pre-stent reflux, respectively) between the two groups. Of the 632 limbs with pre-existing reflux, 218 (34%) had had axial reflux and 414 had had nonaxial reflux (66%). The clinical outcomes were similar between the two groups. Using a multisegment reflux score, the limbs with pre-stent reflux ($n = 632$) were divided into two groups. A segmental score of ≥ 3 indicated severe reflux and a score of < 3 indicated moderate reflux. Of these 632 limbs, 161 (25%) had severe reflux and 471 (75%) had moderate reflux. The two groups demonstrated similar outcomes for most clinical parameters. The post-thrombotic limbs and nonthrombotic limbs also showed similar outcomes.

Conclusions: The long-term follow-up of patients after iliac vein stenting showed that uncorrected reflux is well tolerated by most patients across most clinical measures. (*J Vasc Surg Venous Lymphat Disord* 2022; ■:1-8.)

Keywords: Axial; Dermatitis; Iliac vein stenting; Reflux; Ulcer

Peripheral venous hypertension (PVH) can occur as a consequence of obstruction, reflux, or, less often, high arterial inflow. Many patients with chronic venous insufficiency will have a combination of obstruction and reflux.¹ Obstruction appears to be the dominant factor in PVH, with reflux playing a smaller role. Iliofemoral vein stenting reduces PVH by relieving the venous obstruction. However, the relationship between iliofemoral venous obstruction,

correction of such obstruction, and its effects on valvular reflux has remained unclear.²⁻⁵

It has been speculated that iliofemoral venous stenting might worsen the reflux parameters and that iliofemoral venous obstruction might actually be protective against reflux by acting as a "buffer."⁶ One prior study showed a worsening of the reflux parameters in a small subset of post-thrombotic limbs after iliac venous stenting.⁷ However, our prior experience, and that of other groups, did not show worsening of venous reflux hemodynamics after correction of iliac obstruction.⁸⁻¹⁰ More recently, we have demonstrated in a large patient cohort that the prevalence and severity of reflux will improve in most limbs after stenting and most limbs will not develop new-onset reflux after stenting. The reflux had completely resolved after stenting in 23% of the limbs with reflux before stenting, as measured using the reflux multisegment score.⁶ New-onset reflux developed infrequently, with a median incidence of 7% for all segments at risk.⁶

To the best of our knowledge, the long-term clinical outcomes associated with the correction of chronic

From The RANE Center for Venous and Lymphatic Diseases.

Author conflict of interest: S.R. has U.S. patent for IVUS (intravascular ultrasound) diagnostics and U.S. patent for iliac vein stent design. T.S., M.L., D.T., H.P., and C.L. have no conflicts of interest.

Additional material for this article may be found online at www.jvsvenous.org.

Correspondence: Taimur Saleem, MBBS, FACS, The RANE Center for Venous and Lymphatic Diseases, 971 Lakeland Dr, Ste 401, Jackson, MS 39216 (e-mail: taimur@gmail.com).

The editors and reviewers of this article have no relevant financial relationships to disclose per the Journal policy that requires reviewers to decline review of any manuscript for which they may have a conflict of interest.

2213-333X

Copyright © 2022 by the Society for Vascular Surgery. Published by Elsevier Inc.

<https://doi.org/10.1016/j.jvs.2022.09.009>

iliofemoral venous obstruction in the presence of uncorrected reflux have not been studied in detail in a larger patient cohort for whom reflux testing data (reflux segment score, air plethysmography and ambulatory venous pressure) were also available. These reflux testing data have been recently reported.⁶ In the present report, we have focused on the long-term clinical outcomes in a large patient cohort who had undergone iliofemoral venous stenting without correction of any type of reflux.

METHODS

Setting and patients. We performed a retrospective analysis at a tertiary care venous center. The institutional review board approved the report of de-identified data. From 1997 to 2018 (21-year period), 3532 patients (3637 limbs) had undergone endovenous stenting for CIVO. Patients with stent occlusion (n = 103), patients who had undergone superficial, deep, or perforator venous intervention before or after stent placement (n = 1512), and those with missing reflux measurements (n = 635) were excluded.⁶ After the exclusions, 1379 limbs with objective reflux data available, which have been previously reported,⁶ were included in the present study.

Reflux assessment. Duplex ultrasound, reflux thresholds, and functional tests of reflux (air plethysmography and ambulatory venous pressure) have been previously described in detail.⁶

Patient subsets. Stratified by the presence or absence of reflux before stenting, two groups were compared: limbs with preexisting reflux (n = 632; 46%) and limbs without preexisting reflux (n = 747; 54%). After stenting, four subsets of limbs were available for comparison: (1) limbs with complete resolution of reflux after stenting (n = 148); (2) limbs with partial resolution or improvement of reflux after stenting (n = 131); (3) limbs without resolution of reflux or worsening of reflux after stenting (n = 353); and (4) limbs with development of new-onset reflux after stenting (n = 167).

Iliac vein stenting. Iliac vein stenting was the only procedure performed in the present patient cohort. Superficial and deep reflux were not corrected. The indications, technique, clinical follow-up, and stent surveillance protocols have been previously described in detail.^{6,11-13} Once available, intravascular ultrasound, which is more sensitive than venography, was used to guide all venous interventions.¹⁴⁻¹⁶

Clinical variables. The subsets were compared perioperatively for the following clinical variables: grade of swelling (GOS), visual analog scale (VAS) for pain, venous clinical severity score (VCSS), venous stasis dermatitis, ulceration, and quality of life (QOL) measures. GOS was classified as follows: grade 0, absent; grade 1, pitting but overall not obvious; grade 2, visible ankle edema; grade 3, involving

ARTICLE HIGHLIGHTS

- **Type of Research:** A single-center, retrospective analysis of prospectively collected longitudinal study
- **Key Findings:** The clinical outcomes for 1379 limbs treated with iliac vein stenting during a 23-year follow-up period were analyzed. No significant differences were found in the clinical outcomes across most clinical parameters between the limbs with (n = 632) and without (n = 747) preexistent reflux.
- **Take Home Message:** Long-term follow-up of patients after iliac vein stenting showed that uncorrected reflux is well tolerated by most patients across most clinical measures.

the leg below the knee; and grade 4, involving the whole limb. Pain was assessed using the VAS, with a score of 0 to 10, with 0 indicating no pain and 10 indicative of the most severe pain. QOL was assessed using the CIVIQ (chronic venous insufficiency questionnaire).^{8,17} An ulcer was considered healed only if complete epithelialization (100%) had occurred. Ulcers with any breakdown after healing were ulcer recurrences. The distinction between post-thrombotic and nonthrombotic lesions was determined using intravascular ultrasound.

Other variables. The reflux segment score is computed by the presence of reflux in the vein segments, with one point each assigned to the great saphenous vein, small saphenous vein, perforator vein, femoral vein, deep femoral vein, popliteal vein, and posterior tibial vein. A score of 0 was indicative of no reflux and a score of 7 indicated reflux in all seven segments. The grade of reflux using reflux segment scoring has been shown to correlate with clinical severity.^{4,8,18,19} A reflux multisegment score of ≥ 3 was considered indicative of severe reflux and a score of < 3 indicative of moderate reflux.⁸ The presence of reflux in the great saphenous vein above and below the knee or in the femoral vein to the popliteal vein below the knee was considered axial reflux.²⁰

Statistical analysis. The χ^2 test and *t* test were used for comparison of the proportions and continuous variables, respectively. Analysis of variance was used as appropriate. Ulcer healing and dermatitis resolution were further shown in Kaplan-Meier survival curves. All curves were truncated when the standard error of the mean had exceeded 10%. An event was defined as ulcer healing or dermatitis resolution. A grace period of 4 months was allowed for ulcer healing and dermatitis resolution, at which point, unhealed ulcers and continued dermatitis were censored. Commercially available software, Prism 5 (GraphPad Software Inc, San Diego, CA), was used for statistical analyses. *P* < .05 was considered significant for the associations.

Table I. Clinical outcomes observed for various clinical parameters stratified by prestant reflux

Prestant reflux	Before stenting	After stenting	P value
No (n = 747)			
VCSS	5 ± 3.2	4 ± 3	<.0001
GOS	2 ± 1.1	2 ± 1.3	<.0001
VAS score	5 ± 3.4	2 ± 2.8	<.0001
QOL	61 ± 23.7	49 ± 26.3	<.0001
Ulcers	48 (6)	25 (3%)	.005
Dermatitis	77 (10)	36 (5%)	.0002
Yes (n = 632)			
VCSS	7 ± 3.6	5 ± 2.9	<.0001
GOS	2 ± 1.1	1 ± 1.1	<.0001
VAS score	4 ± 3.3	2 ± 2.6	<.0001
QOL	62 ± 23.2	52 ± 26.8	.0002
Ulcers	85 (13)	32 (5%)	<.0001
Dermatitis	94 (15)	41 (6%)	<.0001

GOS, Grade of swelling; QOL, quality of life; VAS, visual analog scale; VCSS, venous clinical severity score.
Data presented as mean ± standard deviation or number (%).
Boldface P values represent statistical significance.

RESULTS

The follow-up range for the cohort was 1 to 23 years. The median follow-up was 4 years. The demographics of the stented limbs (n = 1379) have been previously described in detail.⁶

Clinical parameters and clinical, etiologic, anatomic, pathophysiologic clinical class. As described, stratified by the presence of reflux before stenting, two groups were available for comparison. Of the 632 patients with prestant reflux, 106 patients (17%) had had CEAP (clinical, etiologic, anatomic, pathophysiologic) class ≥C5. Of the 747 patients without prestant reflux, 57 (8%) had had CEAP class ≥C5. Ulcers were seen more frequently at presentation in the group with prestant reflux (n = 85; 13%) than in those without prestant reflux (n = 48; 6%; $P < .0001$). Similarly, venous stasis dermatitis was more frequently observed among the patients with prestant reflux (n = 94; 15%) than among those without prestant reflux (n = 77; 10%; $P = .004$). Within each of the two groups, significant improvements were observed across all clinical parameters, including the VCSS, GOS, VAS score, QOL, ulcer healing, and resolution of stasis dermatitis (Table I). At the baseline presentation (before stenting), a comparison of the two groups showed some differences (Table II). In addition to the incidence of ulcers and dermatitis, patients with prestant reflux had had higher VCSSs ($P < .0001$) and VAS scores ($P = .003$) than those without prestant reflux. However, when the outcomes after stenting were compared between the two groups, only the VCSS ($P = .01$) and GOS ($P = .01$) showed statistically significant differences between the two groups (Table II). The two groups had similar

outcomes in the improvements in the VAS, QOL, ulcer healing, and dermatitis resolution.

Axial vs nonaxial reflux. Among the 632 limbs with pre-existing reflux, 218 (34%) had axial reflux and 414 had nonaxial reflux (66%). At baseline (Table III), the patients with axial reflux had higher VCSSs (8 ± 4 vs 6 ± 3 ; $P < .0001$) and a greater incidence of ulcers (18% vs 11%; $P = .01$) compared with those with nonaxial reflux. After stenting, the groups were similar for most clinical outcomes, including ulcer healing (9% vs 6%; $P = .1$) and dermatitis resolution (5% vs 8%; $P = .1$).

Multisegment reflux score. Using the multisegment reflux score, the 632 limbs with prestant reflux were divided into two groups. A segmental score of ≥3 indicated severe reflux and a score of <3 indicated moderate reflux. Of the 632 limbs, 161 (25%) had had severe reflux and 471 (75%) had had moderate reflux (Table IV). At baseline, the patients with severe reflux had had a greater incidence of active ulceration (25%) compared with those with moderate reflux (10%; $P < .0001$). After stenting, the two groups were similar for most clinical outcomes, except for ulcer healing. The limbs with severe reflux had more nonhealing ulcers than the moderate reflux group (16% vs 4%; $P < .0001$).

Post-thrombotic vs nonthrombotic limbs. A comparison between the post-thrombotic limbs (n = 687; 50%) and nonthrombotic limbs (n = 692; 50%) showed statistically significant differences (Table V) between the two groups in the presence of ulcers at baseline (11% vs 8%; $P = .02$) and the subsequent healing of ulcers after stenting (5% vs 3%; $P = .03$).

Table II. Comparison of clinical outcomes stratified by prestenit reflux

Clinical parameter	Before stenting	<i>P</i> value	After stenting	<i>P</i> value
VCSS		<.0001		.01
Prestent reflux				
Yes	7 ± 3.6		4 ± 2.9	
No	5 ± 3.2		4 ± 3	
GOS		.1		.01
Prestent reflux				
Yes	2 ± 1.1		1 ± 1.1	
No	2 ± 1.1		2 ± 1.3	
VAS score		.003		.2
Prestent reflux				
Yes	4 ± 3.4		2 ± 2.6	
No	5 ± 3.4		2 ± 2.8	
QOL		.7		.1
Prestent reflux				
Yes	62 ± 23.2		52 ± 26.8	
No	61 ± 23.7		49 ± 26.3	
Ulcers		<.0001		.05
Prestent reflux				
Yes	85 (13)		32 (5)	
No	48 (6)		25 (3)	
Dermatitis		.004		.4
Prestent reflux				
Yes	94 (15)		41 (6)	
No	77 (10)		36 (5)	

GOS, Grade of swelling; QOL, quality of life; VAS, visual analog scale; VCSS, venous clinical severity score. Data presented as mean ± standard deviation or number (%). Boldface *P* values represent statistical significance.

Other post-stent groups. We also compared four other groups stratified by reflux status after stenting. After stenting, four subsets of limbs were available for comparison: group 1, limbs with complete resolution of reflux after stenting ($n = 148$); group 2, limbs with partial resolution or improvement of reflux after stenting ($n = 131$); group 3, limbs without resolution of reflux or worsening of reflux after stenting ($n = 353$); and group 4, limbs with the development of new-onset reflux after stenting ($n = 167$). These groups were compared by the clinical parameters at baseline (Supplementary Table I, online only) and after stenting (Supplementary Table II, online only). The clinical outcomes after stenting were similar among the four groups.

Ulcer healing and dermatitis resolution. Overall, the rate of ulcer healing and dermatitis resolution for the entire cohort (patients with and without prestenit reflux) was >60%. The cumulative rates of ulcer-free limbs and dermatitis-free limbs are shown in Supplementary Figs 1 and 2 (online only).

DISCUSSION

The results from the present study have demonstrated that the clinical outcomes will not differ significantly between the limbs with and without reflux before stenting across most clinical measures for most patients. As a stand-alone procedure, stenting will produce satisfactory clinical outcomes even in the presence of uncorrected reflux. Therefore, in the long term, the correction of superficial or deep reflux might be required less frequently. In addition, initial stent treatment will not prohibit later correction of reflux in the rare cases of stent failure, including for patients with active venous ulceration (CEAP class C6).²¹ The treatment of superficial reflux is minimally invasive and low risk and can be easily undertaken if stenting has failed to produce the desired clinical outcome, which has been rare for patients who have been appropriately and rigorously selected for endovenous stenting. We have previously described methods of quantifying saphenous reflux in detail.²² Detailed guidelines have been provided by the Society

Table III. Comparison of clinical outcomes for those with axial reflux (n = 218) and nonaxial reflux (n = 414)

Clinical parameter	Before stenting	<i>P</i> value	After stenting	<i>P</i> value
VCSS		<.0001		.3
Axial reflux	8 ± 4		5 ± 3	
Nonaxial reflux	6 ± 3		4 ± 3	
GOS		.03		.003
Axial reflux	2 ± 1		1 ± 1	
Nonaxial reflux	2 ± 1		1 ± 1	
VAS score		.6		.8
Axial reflux	5 ± 3		1 ± 2	
Nonaxial reflux	4 ± 3		2 ± 3	
QOL		.6		.7
Axial reflux	64 ± 21		53 ± 27	
Nonaxial reflux	61 ± 24		52 ± 27	
Ulcers		.01		.1
Axial reflux	40/218 (18)		19/218 (9)	
Nonaxial reflux	45/414 (11)		26/414 (6)	
Dermatitis		.3		.1
Axial reflux	36/218 (17)		10/218 (5)	
Nonaxial reflux	59/414 (14)		32/414 (8)	

GOS, Grade of swelling; QOL, quality of life; VAS, visual analog scale; VCSS, venous clinical severity score.
Data presented as mean ± standard deviation or number/total (%).
Boldface *P* values represent statistical significance.

for Vascular Surgery/American Venous Forum regarding the thresholds for saphenous vein reflux treatment.²³ Deep reflux still requires open correction for satisfactory

resolution of the reflux, and, at present, there are no widely available and satisfactory endovenous options for the correction of deep reflux. Also, a steady

Table IV. Comparison of clinical outcomes for patients with moderate (n = 471) and severe (n = 161) reflux^a

Clinical parameter	Before stenting	<i>P</i> value	After stenting	<i>P</i> value
VCSS		<.0001		.0007
Severe reflux	8 ± 4		5 ± 3	
Moderate reflux	6 ± 3		4 ± 3	
GOS		.1		.4
Severe reflux	2 ± 1		1 ± 1	
Moderate reflux	2 ± 1		1 ± 1	
VAS score		.6		.8
Severe reflux	4 ± 3		1 ± 2	
Moderate reflux	5 ± 3		2 ± 3	
QOL		.2		.8
Severe reflux	58 ± 23		52 ± 28	
Moderate reflux	64 ± 23		52 ± 26	
Ulcers		<.0001		<.0001
Severe reflux	40/161 (25)		25/161 (16)	
Moderate reflux	45/471 (10)		18/471 (4)	
Dermatitis		.1		.6
Severe reflux	30/161 (19)		9/161 (6)	
Moderate reflux	64/471 (14)		32/471 (7)	

GOS, Grade of swelling; QOL, quality of life; VAS, visual analog scale; VCSS, venous clinical severity score.
Data presented as mean ± standard deviation or number/total (%).
Boldface *P* values represent statistical significance.
^aSegmental score ≥3 indicated severe reflux and a score of <3 indicated moderate reflux.

Table V. Comparison of clinical outcomes between post-thrombotic (n = 687) and nonthrombotic limbs (n = 692)

Clinical parameter	Before stenting	P value	After stenting	P value
VCSS		.9		.07
PTL	6 ± 4		4 ± 3	
NTL	6 ± 3		4 ± 3	
GOS		.3		.9
PTL	2 ± 1		1 ± 1	
NTL	2 ± 1		1 ± 1	
VAS score		.8		.3
PTL	5 ± 3		2 ± 3	
NTL	5 ± 4		2 ± 3	
QOL		.0002		.8
PTL	66 ± 22		51 ± 27	
NTL	56 ± 24		50 ± 27	
Ulcers		.02		.03
PTL	79/687 (11)		36/687 (5)	
NTL	54/692 (8)		21/692 (3)	
Dermatitis		.1		.07
PTL	94/687 (14)		46/687 (7)	
NTL	77/692 (11)		31/692 (4)	

GOS, Grade of swelling; QOL, quality of life; VAS, visual analog scale; VCSS, venous clinical severity score.
Data presented as mean ± standard deviation or number/total (%).
Boldface P values represent statistical significance.

deterioration of reflux will occur after open correction of deep reflux²⁴—this has not been seen as frequently after stenting in limbs with reflux.⁶

The relationship between obstruction and reflux is probably complex. Obstruction likely produces PVH at the macrovascular level, and reflux exerts its effects at the microvascular level. Previous reports have shown that for patients with concomitant deep and superficial reflux, treatment of the saphenous vein reflux alone will lead to resolution of the deep reflux in one third of the patients.²⁵ Therefore, treating one pathology in the venous system appears to affect the hemodynamics of the other components in the system. In most limbs, reflux will improve after stenting.⁶ Thus, correction of macrovascular PVH secondary to chronic iliofemoral venous obstruction can obviate the need for correction of reflux. This has important clinical implications, because it could reduce the number of procedures most patients will need to undergo to achieve adequate clinical outcomes.

In our prior report, reflux severity was graded using one of three methods: (1) a reflux segmental score; (2) air plethysmography (venous filling index); and (3) ambulatory venous pressure (venous filling time).⁶ Different venous segments exhibited different frequencies of pre-stent reflux involvement—from a low of 7% for the deep femoral segment to a high of 51% for the popliteal vein segment. After stent placement, resolution of reflux had also varied in the various venous segments. This

included 21% resolution of reflux at the femoral vein to 58% at the perforator segments. In addition, 44% of the limbs showed improvement in reflux severity, 19% showed worsening, and 37% had remained stable. Overall, complete resolution of reflux occurred in 23% of patients. The Kaplan-Meier curve showed that the prevalence of reflux had declined from 100% to 42% of limbs at 14 years after stenting. The improvement in reflux was most rapid during the first year after intervention.⁶

In a smaller retrospective study, the clinical outcomes after stenting (resolution of pain and swelling) did not differ among patients with severe reflux (reflux multisegment score, ≥3) and those with moderate reflux (reflux multisegment score, <3). Also, the clinical outcomes after stenting did not differ significantly between the limbs with axial reflux and nonaxial reflux.⁸ Our study has also demonstrated that these groups had similar outcomes for most clinical measures. In smaller reports, ulcer healing did not differ significantly between the patients with and without reflux after endovenous stenting.^{26,27} In several other smaller studies, residual or uncorrected reflux did not affect clinical improvement or ulcer recurrence.²⁸⁻³²

In one prior study, bilateral iliac vein stenting was noted to produce a significant improvement in reflux in the great and small saphenous veins.³³ However, unilateral stenting did not produce the same result. In our cohort, bilateral stenting was rarely performed. We have shown

that correction of only ipsilateral obstruction with iliofemoral stenting will also produce symptom improvement in the contralateral limb.³⁴ Therefore, most patients will not require bilateral stenting.

We have also previously described the safety and feasibility of combined saphenous vein ablation and iliac stent placement for complex severe chronic venous disease.³⁵ This has also been described by other groups.^{36,37} However, given the clinical improvement with stenting alone, correction of any type of reflux (deep or superficial) does not appear to be necessary for many patients (including patients with CEAP class C6), because patients appear to clinically tolerate residual reflux well.

Several explanations for reflux improvement after stent placement have been discussed previously.⁶ In brief, stenting will reduce PVH, which leads to a reduction in the caliber of the vein and, subsequently, the valve station distal to the stent. Also, the load on the valve station will be less after relief of the obstructive pathology.⁶

CONCLUSIONS

Our long-term follow-up of limbs after iliac vein stenting alone showed that stenting will produce adequate clinical outcomes across most clinical measures in most limbs. Uncorrected reflux will be well tolerated by most limbs.

Statistical consultation for the analysis of data was provided by Dr Jennifer Stafford, PhD, Professor, Mississippi College, Clinton MS.

AUTHOR CONTRIBUTIONS

Conception and design: TS, SR
Analysis and interpretation: TS, ML, DT, HP, CL, SR
Data collection: ML, DT, HP, CL
Writing the article: TS, ML, DT, HP, CL, SR
Critical revision of the article: TS, SR
Final approval of the article: TS, ML, DT, HP, CL, SR
Statistical analysis: ML, DT, HP, CL
Obtained funding: Not applicable
Overall responsibility: TS

REFERENCES

1. Wahlgren CM, Wahlberg E, Olofsson P. Endovascular treatment in postthrombotic syndrome. *Vasc Endovascular Surg* 2010;44:356-60.
2. Raju S, Knight A, Lamanilao L, Pace N, Jones T. Peripheral venous hypertension in chronic venous disease. *J Vasc Surg Venous Lymphat Disord* 2019;7:706-14.
3. Kassab G, Raju S. Grading venous stenosis is different from arterial lesions. *J Vasc Surg Venous Lymphat Disord* 2019;7:151-2.
4. Saleem T, Raju S. Pressure dynamics in chronic venous disease. *J Theor Appl Vasc Res* 2019;4:25-32.
5. Neglén P. Chronic deep venous obstruction: definition, prevalence, diagnosis, management. *Phlebology* 2008;23:149-57.
6. Raju S, Lucas M, Luke C, Peeples H, Saleem T, Jayaraj A. Long-term improvement of limb reflux prevalence and severity after iliac vein stent placement. *J Vasc Surg Venous Lymphat Disord* 2022;10:640-5.e1.
7. Delis KT, Bjarnason H, Wennberg PW, Rooke TW, Gloviczki P. Successful iliac vein and inferior vena cava stenting ameliorates venous claudication and improve venous outflow, calf muscle pump function and clinical status in post-thrombotic syndrome. *Ann Surg* 2007;245:130-9.
8. Raju S, Darcey R, Neglén P. Unexpected major role for venous stenting in deep reflux disease. *J Vasc Surg* 2010;51:401-8; discussion: 408.
9. Neglén P, Thrasher TL, Raju S. Venous outflow obstruction: an underestimated contributor to chronic venous disease. *J Vasc Surg* 2003;38:879-85.
10. Yin M, Shi H, Ye K, Lu X, Li W, Huang X, et al. Clinical assessment of endovascular stenting compared with compression therapy alone in post-thrombotic patients with iliofemoral obstruction. *Eur J Vasc Endovasc Surg* 2015;50:101-7.
11. Saleem T, Powell T, Raju S. Iliofemoral venous stenting in patients with central neuromuscular disorders. *J Vasc Surg Venous Lymphat Disord* 2022;10:626-32.
12. Saleem T, Knight A, Raju S. Diagnostic yield of intravascular ultrasound in patients with clinical signs and symptoms of lower extremity venous disease. *J Vasc Surg Venous Lymphat Disord* 2020;8:634-9.
13. Saleem T, Knight A, Raju S. Effect of iliofemoral-caval venous intervention on lower extremity compartment pressure in patients with chronic venous insufficiency. *J Vasc Surg Venous Lymphat Disord* 2020;8:769-74.
14. Saleem T, Raju S. Comparison of intravascular ultrasound and multidimensional contrast imaging modalities for characterization of chronic occlusive iliofemoral venous disease: a systematic review. *J Vasc Surg Venous Lymphat Disord* 2021;9:1545-56.e2.
15. Saleem T, Lucas M, Raju S. Comparison of intravascular ultrasound and magnetic resonance venography in the diagnosis of chronic iliac venous disease. *J Vasc Surg Venous Lymphat Disord* 2022;10:1066-71.e2.
16. Saleem T. Accurate and appropriate selection of patients for iliofemoral endovenous intervention: are we there yet? *Eur J Vasc Endovasc Surg* 2022;64:135-6.
17. Launois R, Reboul-Marty J, Henry B. Construction and validation of a quality of life questionnaire in chronic lower limb venous insufficiency (CIVIQ). *Qual Life Res* 1996;5:539-54.
18. Neglén P, Raju S. A rational approach to detection of significant reflux with duplex Doppler scanning and air plethysmography. *J Vasc Surg* 1993;17:590-5.
19. Raju S, Knepper J, May C, Knight A, Pace N, Jayaraj A. Ambulatory venous pressure, air plethysmography, and the role of calf venous pump in chronic venous disease. *J Vasc Surg Venous Lymphat Disord* 2019;7:428-40.
20. Danielsson G, Eklof B, Grandinetti A, Lurie F, Kistner RL. Deep axial reflux, an important contributor to skin changes or ulcer in chronic venous disease. *J Vasc Surg* 2003;38:1336-41.
21. Raju S. Treatment of iliac-caval outflow obstruction. *Semin Vasc Surg* 2015;28:47-53.
22. Raju S, Ward M Jr, Jones TL. Quantifying saphenous reflux. *J Vasc Surg Venous Lymphat Disord* 2015;3:8-17.
23. Gloviczki P, Comerota AJ, Dalsing MC, Eklof BC, Gillespie DL, Gloviczki ML, et al. The care of patients with varicose veins and associated chronic venous diseases: clinical practice guidelines of the Society for Vascular Surgery and the American Venous Forum. *J Vasc Surg* 2011;53(Suppl):2S-48S.
24. Raju S, Berry MA, Neglén P. Transcommissural valvuloplasty: technique and results. *J Vasc Surg* 2000;32:969-76.
25. Puggioni A, Lurie F, Kistner RL, Eklof B. How often is deep venous reflux eliminated after saphenous vein ablation? *J Vasc Surg* 2003;38:517-21.
26. Raju S, Kirk OK, Jones TL. Endovenous management of venous leg ulcers. *J Vasc Surg Venous Lymphat Disord* 2013;1:165-72.
27. Raju S, Owen S Jr, Neglén P. The clinical impact of iliac venous stents in the management of chronic venous insufficiency. *J Vasc Surg* 2002;35:8-15.
28. Neglén P, Hollis KC, Olivier J, Raju S. Stenting of the venous outflow in chronic venous disease: long-term stent-related outcome, clinical and hemodynamic result. *J Vasc Surg* 2007;46:979-90.
29. Blanch Alerany M, Izquierdo Lamoca LM, Ramirez Ortega M, Lago Rivas I, Zotta Desboeufs R, Stefanov Kiuri S. Endovascular treatment of iliofemoral chronic post-thrombotic venous flow obstruction. *J Vasc Surg Venous Lymphat Disord* 2014;2:2-7.

30. Hartung O, Otero A, Boufi M, De Caridi G, Barthelemy P, Juhan C, et al. Mid-term results of endovascular treatment for symptomatic chronic nonmalignant ilio caval venous occlusive disease. *J Vasc Surg* 2005;42:1138-44; discussion: 1144.
31. Raju S, Neglen P. High prevalence of nonthrombotic iliac vein lesions in chronic venous disease: a permissive role in pathogenicity. *J Vasc Surg* 2006;44:136-43; discussion: 144.
32. Kulkarni SR, Barwell JR, Gohel MS, Bulbulia RA, Whyman MR, Poskitt KR. Residual venous reflux after superficial venous surgery does not predict ulcer recurrence. *Eur J Vasc Endovasc Surg* 2007;34:107-11.
33. Chait J, Kibrik P, Kenney K, Alsheekh A, Ostrozhynskyy Y, Marks N, et al. Bilateral iliac vein stenting reduces great and small saphenous venous reflux. *Vascular* 2019;27:623-7.
34. Jayaraj A, Noel C, Raju S. Contralateral limb improvement after unilateral iliac vein stenting argues against simultaneous bilateral stenting. *J Vasc Surg Venous Lymphat Disord* 2020;8:565-71.
35. Neglén P, Hollis KC, Raju S. Combined saphenous ablation and iliac stent placement for complex severe chronic venous disease. *J Vasc Surg* 2006;44:828-33.
36. Yang L, Liu J, Cai H, Liu Y. The clinical outcome of a one-stop procedure for patients with iliac vein compression combined with varicose veins. *J Vasc Surg Venous Lymphat Disord* 2018;6:696-701.
37. Guo Z, Li X, Wang T, Liu J, Chen B, Fan L. Effectiveness of iliac vein stenting combined with high ligation/endovenous laser treatment of great saphenous veins in patients with clinical, etiology, anatomy, pathophysiology class 4 to 6 chronic venous disease. *J Vasc Surg Venous Lymphat Disord* 2020;8:74-83.

Submitted Jul 12, 2022; accepted Sep 1, 2022.

Additional material for this article may be found online at www.jvsvenous.org.

Supplementary Table I (online only). Comparison of baseline clinical parameters for four limb groups^a

Outcome	Group 1 (n = 148; 11%)	Group 2 (n = 131; 10%)	Group 3 (n = 353; 26%)	Group 4 (n = 167; 12%)	P value
VCSS	5.8 ± 3	7.7 ± 4.3	6.4 ± 3.7	6 ± 3.6	.0006
GOS	2.4 ± 1.1	2.1 ± 1.3	2.2 ± 1.2	2.1 ± 1.2	.2
VAS	4.8 ± 3.4	4.5 ± 3.3	4.4 ± 3.4	4.4 ± 3.6	.4
QOL	65 ± 25	56 ± 23	63 ± 23	61 ± 23	.5

GOS, Grade of swelling; QOL, quality of life; VAS, visual analog scale; VCSS, venous clinical severity score.

Data presented as mean ± standard deviation.

Boldface P values represent statistical significance.

^aGroup 1, reflux completely resolved; group 2, reflux partially resolved or improved; group 3, reflux worsened; and group 4, development of new-onset reflux.

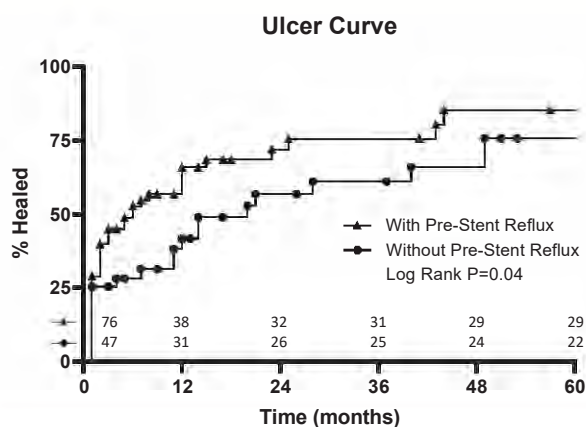
Supplementary Table II (online only). Comparison of clinical parameters after stenting among four groups of limbs stratified by residual reflux status^a

Outcome	Group 1 (n = 148; 11%)	Group 2 (n = 131; 10%)	Group 3 (n = 353; 26%)	Group 4 (n = 167; 12%)	P value
VCSS	4.2 ± 2.8	4.5 ± 3.2	4.5 ± 3	4.2 ± 3.2	.5
GOS	1.5 ± 1.2	1.2 ± 1.1	1.4 ± 1.2	1.5 ± 1.3	.1
VAS	1.7 ± 2.8	1.4 ± 2.5	1.6 ± 2.7	1.4 ± 2.5	.6
QOL	54 ± 26	49 ± 27	52 ± 27	49 ± 24	.4

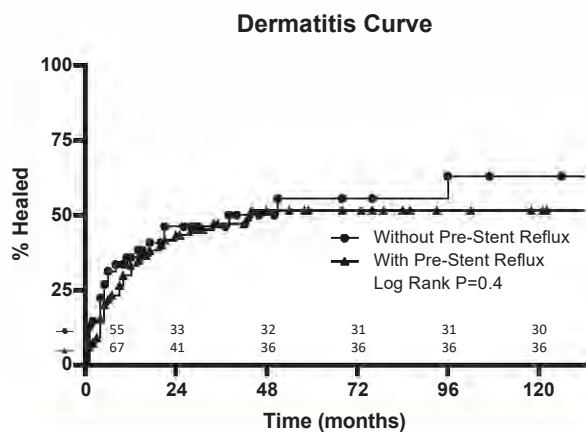
GOS, Grade of swelling; QOL, quality of life; VAS, visual analog scale; VCSS, venous clinical severity score.

Data presented as mean ± standard deviation.

^aGroup 1, reflux completely resolved; group 2, reflux partially resolved or improved; group 3, reflux worsened; and group 4, development of new-onset reflux.



Supplementary Fig 1 (online only). Kaplan-Meier curves demonstrating ulcer healing in patients with and without pre-stent reflux. Standard error of the mean <10%. A grace period of 4 months for healing of active ulcers was allowed before the limbs with unhealed ulcers were censored.



Supplementary Fig 2 (online only). Kaplan-Meier curves demonstrating resolution of dermatitis in patients with and without pre-stent reflux. Standard error of the mean <10%. A 4-month grace period was allowed for dermatitis to heal before the limbs with continued dermatitis were censored.