

# A Modification of Iliac Vein Stent Technique

Seshadri Raju, Mark Ward Jr, and Orla Kirk, Jackson, Mississippi

**Background:** Iliac vein stenting has emerged as a promising new technology to address a wide spectrum of advanced chronic venous disease. Wallstent™ has been the commonest stent type used in reported experience. It has excellent long-term patency with good clinical outcome, but is prone to compression/migration of the upper end of the stent requiring reinterventions. Extension of the stent into the vena cava to avoid this problem may render subsequent contralateral stenting technically difficult and possibly contribute to partial jailing of contralateral flow. A technical modification in which a Gianturco Z stent™ is added to the upper end of the Wallstent stack that may ameliorate some of these concerns is described.

**Methods:** The details of technique, complications, patency, and reinterventional rate of the Z stent modification in 217 limbs followed up to 24 months are reported.

**Results:** Cumulative primary and secondary patency (24 months) were 69% and 93%, respectively. Eight stents were occluded and lysis restored patency in 6 patients. There was no mortality. Deep venous thrombosis (<30 day) occurred in 4% of patients similar to the incidence in native disease. Reinterventions were required in 11% of patients over the follow-up period to correct stent malfunction. Most of these (23/25) were related to the Wallstent tail of the combination stent stack. The Z stent modification provides increased radial strength at the iliac–caval junction which is a choke point. The Z stent modifications greatly facilitate staged or sequential bilateral stenting technique and may reduce the incidence of reinterventions related to retraction or compression of the upper end commonly seen with prior Wallstent experience.

**Conclusion:** The Z stent modification appears to improve functionality of the stent stack at the upper end and greatly facilitates simultaneous or staged bilateral stenting technique.

## BACKGROUND

The importance of iliac vein obstruction in primary as well as postthrombotic disease has received greater attention with the advent of venous stent technology. A wide spectrum of patients with CEAP class 3–6 chronic venous disease appears to benefit even despite the presence of associated reflux.<sup>1–3</sup> Iliac vein stenting appears to have

excellent long-term patency, minimal morbidity, and satisfactory durable clinical outcome. Wallstents™ (Boston Scientific, Nantick, MA) have been nearly exclusively used in reported experience because they are available in large sizes desired for venous use.<sup>4</sup> The stent is of braided construction from stainless steel strands. This imparts necessary flexibility to its structure, but stent length will vary with constrained diameter reducing deployment accuracy. When compressed near the ends, the cylindrical form transforms into a cone with narrowed ostia. This is a set-up for local migration and the lesion can squeeze the stent away spontaneously or during postdilatation with recurrence of stenosis.<sup>5</sup> These stent “end effects” are particularly common when treating lesions at or near the iliac–caval junction and the stent is attempted to be placed “precisely” at the junction to avoid stent encroachment of vena cava proper. Both primary and postthrombotic lesions occur frequently at this location.<sup>6,7</sup> Constriction of the stent diameter by as

Presented at 25th Annual Meeting of the American Venous Forum, Phoenix, AZ, February 2013.

The Rane Center at St. Dominic, Jackson, MS.

Correspondence to: Seshadri Raju, MD, FACS, The Rane Center, 971 Lakeland Drive, East Tower, Suite 401, Jackson, MS 39216, USA; E-mail: rajumd@earthlink.net

Ann Vasc Surg 2014; 28: 1485–1492

<http://dx.doi.org/10.1016/j.avsg.2014.02.026>

© 2014 Elsevier Inc. All rights reserved.

Manuscript received: November 12, 2013; manuscript accepted: February 26, 2014; published online: March 12, 2014.

much as 20–30% can occur because of recoil in some tight lesions despite adequate predilatation, leading to unpredictable stent length after deployment. Precise stent placement across this lesion is difficult, because of the variability of the lesion length, and also the anatomic variability of the arterial and venous bifurcations in this location.<sup>6,8</sup> Furthermore, venography is a poor guide to assess these variabilities.<sup>8,9</sup> We have advocated extension of the Wallstent for 3–5 cm into the inferior vena cava to avoid these placement difficulties.<sup>10</sup> This recommendation is often not adopted because of concerns related to jailing of contralateral iliac flow. In our own experience, acute jailing is rare.<sup>1</sup> It is difficult to determine if chronic or subacute jailing occurs when coverage of the upper end of the stent with tissue occurs over time, decreasing its porosity and cross flow. About 20% of stented patients undergo subsequent contralateral iliac stenting because the disease is often bilateral. Whether contralateral symptoms are hastened or precipitated by chronic outflow restriction is an open question. The caval stent extension also poses technical difficulties in sequential bilateral stenting and may be occasionally impossible because a fenestrum could not be created to join the stents. The fenestrum itself is a source of stent malfunction as well, requiring reinterventions.<sup>11,12</sup>

A technical modification in which a Gianturco Z stent tops the Wallstent stack at the upper end appears to contribute greater radial strength to withstand the tight constricting lesion at the iliac–caval junction, reduces the chance of “jailing” contralateral iliac vein, and greatly improves the technical ease of simultaneous or sequential bilateral iliac vein stenting. The technique and results are described below.

## PATIENTS AND METHODS

The Z stent modification was introduced in March 2011. The results in 217 consecutive limbs with this technical modification (Z modification) performed over a 24-month period are reported.

### Technique

Preliminary steps were the same as previously described.<sup>7,13</sup> The procedure was carried out under Intravascular Ultrasound (IVUS) guidance through an antegrade mid-thigh approach (11F sheath). The stenotic lesions were identified and dilated with a 16-mm balloon to 16 atmosphere (units). It is important to identify the iliac–caval junction with IVUS and mark its location relative to adjacent

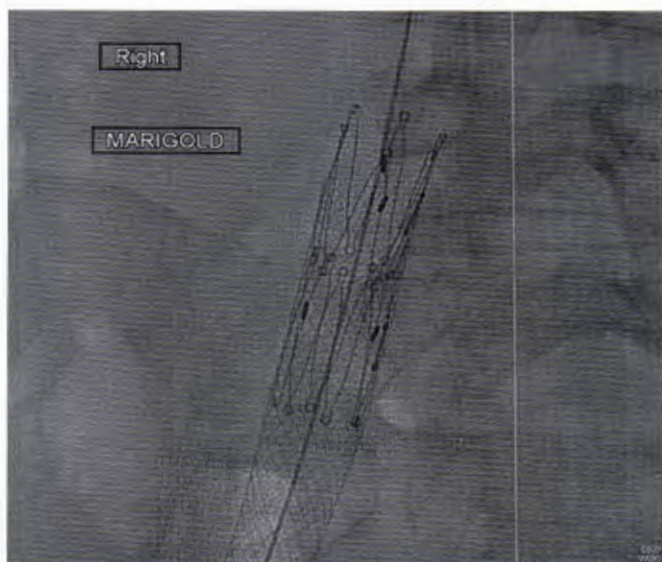
bony landmark on fluoroscopy. On the left side, this commonly lies at the level of L5 vertebral spine. On the right side, the transverse process of L5 is the most frequent landmark. In about 30% of patients, the venous junction is higher at L4 or occasionally even at L3 level. Wallstents 18-mm diameter (Boston Scientific) are deployed with the upper end starting at the iliac–caval junction and ending in the common femoral vein below the inguinal ligament. Minor or major lesions identifiable by IVUS or balloon waisting are so frequently present at various choke points<sup>7</sup> in the iliac–femoral segment that extension of the stent to the common femoral vein is now routine to minimize reinterventions.<sup>5</sup> Postdilatation of the Wallstent stack is deferred until a 20-mm Z stent (Gianturco stent; Cook Medical, Bloomington, IN) is deployed through a 16F sheath at the upper end of the Wallstent stack. It is not uncommon to see the upper end of the Wallstent “squeezed” downward after deployment by a tight lesion and retract  $\approx$  1–2 cm. This is manageable by adjusting the overlap of the Z stent. Premature postdilatation of the Wallstent stack before Z stent deployment often resulted in even greater distal retraction which requires placement of a 6-cm long add-on Wallstent at the upper end to restore the stack length.

The Z stent is deployed such that the upper Z petals are extended about 2 cm into the inferior vena cava and the remainder of the Z stent safely deployed within the confines of the Wallstent stack (Fig. 1). This overlap provides additional radial strength and fixation against the iliac–caval choke point. The widely spaced Z struts at the upper end allow outflow from the contralateral iliac vein without constraint. It is important to oversize the Z stent relative to the Wallstent, otherwise embolization of the Z stent is a risk. Postdilatation of the Wallstent section (not necessary and not recommended for the Z component) can now be carried out with a 16-mm balloon through a 11F sheath. The slight oversizing of the Wallstent (18 mm) relative to ballooned diameter (16 mm) allows later over-dilatation if required during reinterventions.


### Bilateral Deployment

Side-by-side (double barrel) configuration of the relatively stiff Z stent is not desirable as the combined diameter (40 mm) of the 2 stents greatly exceeds the diameter of the vena cava (20–24 mm) posing the risk of erosion.

The Z stent is composed of 2 sequential cylinders of Z struts mated together and held into a cylindrical shape by a series of 3 synthetic sutures, 1 on either

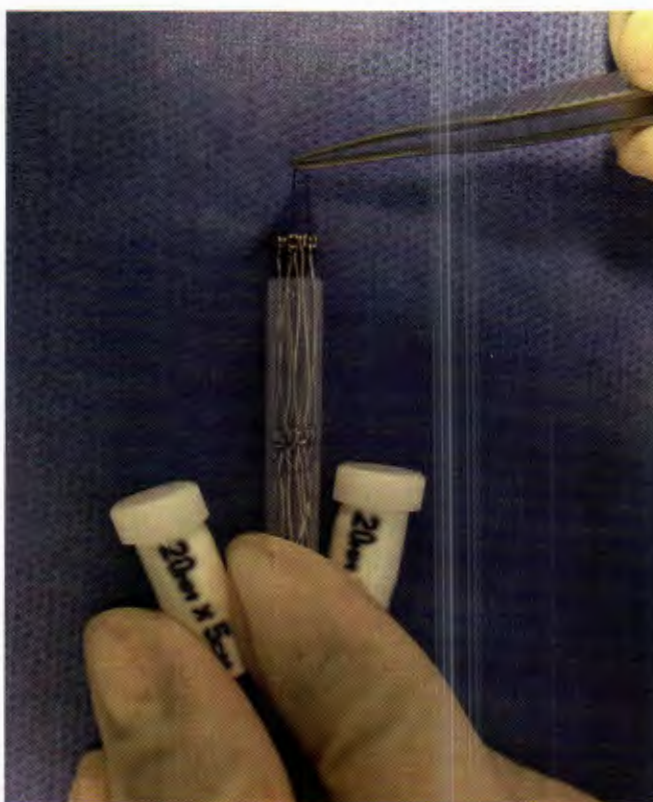


**Fig. 1.** Z stent is deployed within the upper end of the Wallstent stack to provide radial strength. The wide strut structure allows free outflow from the opposite iliac vein.

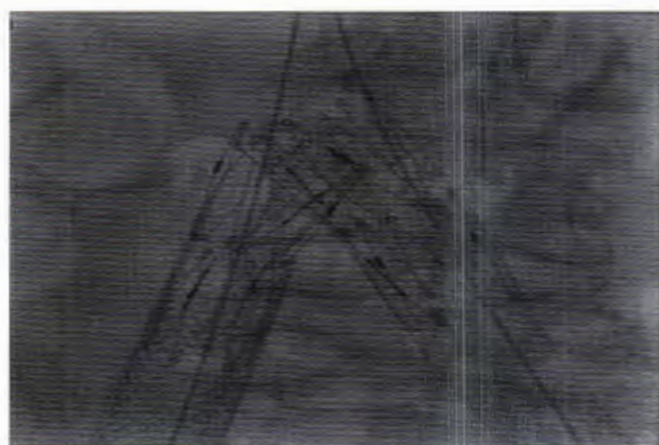


**Fig. 2.** Z stents. Z stent on the *left* has all 3 synthetic sutures intact. Z stent on the *right* has had the suture on the top end removed and has "bloomed."

end of the module and 1 at the waist (Fig. 2). There are 4 sharp hooks, 2 for each set of Z ring cylinders situated midway in the body of the stent for peripheral fixation. If the suture at the top end is removed, the Z stent module will bloom after deployment with full eversion of the Z petals (not desirable) unless constrained by the overlapping Wallstent. The uppermost suture can be removed by extruding the stent partially from the plastic capsule without exposing the sharp hooks and then pushing the stent back into its capsule (Fig. 3). For unilateral deployment, removal of the suture is not necessary. For sequential or bilateral deployment, removal of the suture at least in the second deployment allows interdigitation of the Z struts, which is impeded



**Fig. 3.** For bilateral deployment, the upper suture in the Z stent should be removed for interdigitation (see text). The Z stent is pushed out from the capsule, without exposing the hooks, for removal of the suture as shown. The suture is looped around the strut rings. After careful complete removal of the suture, the stent can be pushed back into the capsule.



**Fig. 4.** Interdigitation of bilateral Z stents prevents overdistension of the inferior vena cava.

when the suture is in place. The interdigitation keeps the overall diameter of the mating stents within bounds without unduly stretching the inferior vena cava (Fig. 4).

Long-term anticoagulation was determined by standard indications (thrombophilia, recurrent thrombosis, unprovoked thrombosis) independent of the stent procedure. In others, low-molecular-weight heparin was used for a short term (up to 6 weeks) followed by aspirin for long-term use.

Follow-up consisted of duplex scan of the stent the day after the procedure and then at 4–6 weeks, 3 months, and at 6-month intervals with concomitant clinical assessment as previously described.

## RESULTS

The demographics of the Z stent group are shown in Table I.

Deployment details of the Z stent are shown in Table II. When the inferior vena cava itself has to be stented for disease, the Z stent is an ideal bridge at the iliac confluence; the large strut spaces allow free flow from both iliac veins without impediment (Fig. 5). The strong radial strength of the stent allows end-to-side joint through a fenestrum with a previously resident Wallstent in the distal inferior vena cava (Fig. 6). In a small number of cases, the Z stent was used inside a previously deployed Wallstent assembly to correct fenestral stenosis or stent compression from outside at the iliac–caval choke point.

There was no mortality. Embolization of the Z stent to the suprarenal vena cava below the diaphragm occurred in 2 cases (1 intraoperative and 1 delayed) in our early experience when 15-mm Z stents were deployed at the upper end of the Wallstent stack. In both cases, the migrant Z stent was fixed in the infradiaphragmatic position by deploying a large (24-mm diameter) Wallstent inside and overlapping the Z stent. Both patients are without symptoms. No embolizations have occurred because of using 20-mm Z stents, oversizing them relative to the 18-mm Wallstent stack (balloon dilated only to 16 mm) and deploying the Z stent with substantial overlap within the Wallstent stack as described. Stent erosion did not occur; stent struts were confined to the flow channel by duplex scan.

Modest self-limiting back pain occurred in about 25% of patients; none required admission for pain control. Deep venous thrombosis occurred in 4% (<30 days) and 1% (>30 day), respectively. Thrombosis of the entire stent stack occurred in 8 limbs, 6 of which were successfully reopened by thrombolysis.

Twenty-four month primary and secondary cumulative patency curves are shown in Figure 7.

**Table I.** Demographics of case material

Criteria	Z modification ( <i>n</i> = 217)
Median age (range)	58 (17–96)
Male:Female	1:2
Right limb:Left limb	1:1
Primary:Postthrombotic <sup>a</sup>	1:3
CEAP class (%)	
2	2
3	34
4a	28
4b	16
5	7
6	13

<sup>a</sup>Nine recanalizations.

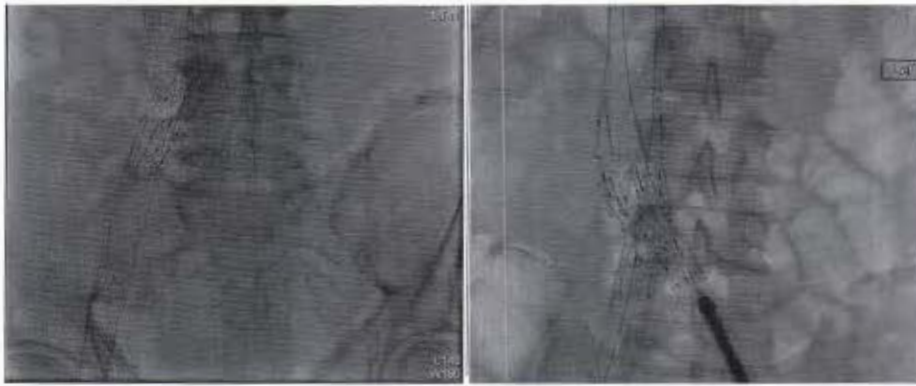
**Table II.** Z stent deployment details

Deployment method	Number of limbs ( <i>n</i> = 217)
Unilateral stenting	133
Simultaneous bilateral method	44
Staged sequential bilateral method	22
Fenestration of a preexisting contralateral stent	18

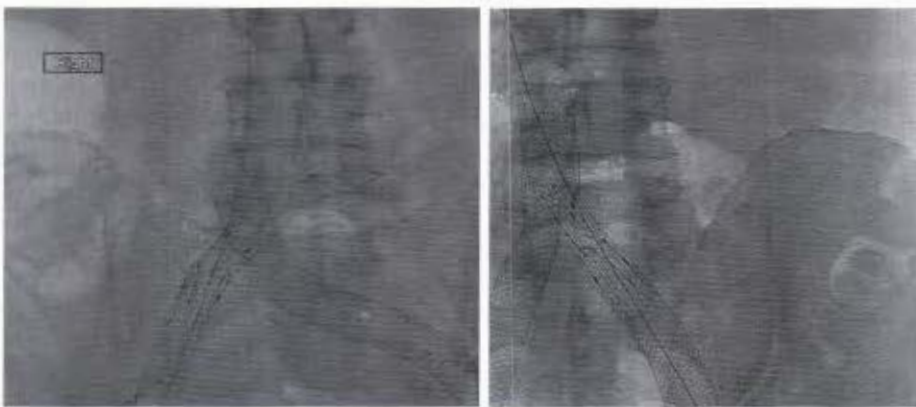
Reinterventions for persistent or residual symptoms were required in 25 limbs (11%) over the 24-month period. The Z component of the stent stack was at fault in 2 of these: in one, compression of even the Z stent by a tight postthrombotic lesion and in the other, the stenosis was not fully crossed by the Z stent at original deployment. The Wallstent component of the stack was the primary source of stent malfunction (instent restenosis/stent compression) in the remaining 23 limbs.

## DISCUSSION

Iliac vein stenting for chronic venous disease appears to be safe and effective—necessary attributes for treating a disease which seldom threatens limb or life. Wallstent has been utilized for this application in most of the reported experience<sup>4</sup>. It has excellent long-term patency and crossability across the inguinal crease<sup>14</sup> without the risk of fractures and erosions unlike in arterial use. Cumulative secondary patency for correction of nonocclusive stenoses in postthrombotic and nonthrombotic disease were 86% and 100%, respectively, at 6 years.<sup>1</sup> Similar results have been reported by other centers.<sup>4</sup> However, the various stent patency rates (primary,



**Fig. 5.** Inferior vena cava—iliac vein stent reconstruction with Z stent at the confluence to allow cross flow. Unilateral (*left*) and bilateral (*right*).



**Fig. 6.** Fenestration of Z stent with previously deployed Wallstent in the distal inferior vena cava (*left*). Fenestral stenosis corrected by a Z stent within the Wallstent (*right*).

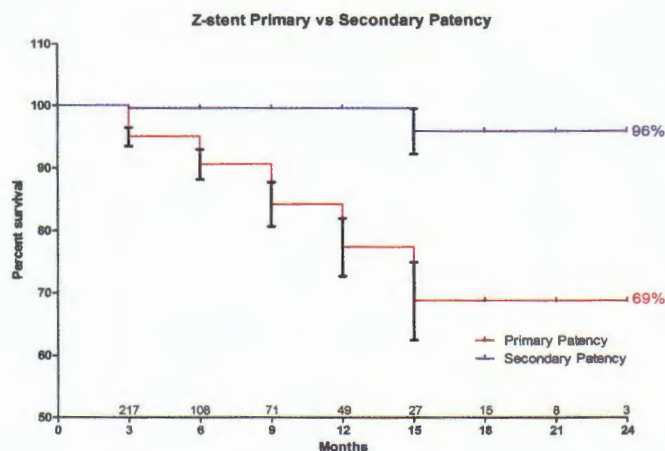
primary assisted, and secondary) differ among thrombotic stenosis, nonthrombotic stenosis, and chronic total occlusions (CTO), respectively.

Stent thrombosis and in-stent restenosis are much lower than generally seen in arterial applications. Most of the stent thrombosis is confined to post-thrombotic limbs particularly after recanalization of CTO.<sup>1,4,7,15</sup> Remarkably, stent thrombosis is extremely rare in primary cases. Even so, stent functionality can be improved further in some respects. About 20% of iliac vein Wallstents require reinterventions over time to correct problems with the upper or lower ends of the stent or within the stent stack itself. In-stent restenosis/thrombus layering within the stent often occur because of inflow/outflow problems at either end of the stent stack. Problems with the upper end (stent compression, distal migration) alone or in combination with others account for half or more of the interventions undertaken in the past.<sup>5</sup> The addition of Z stent to the upper end of the Wallstent stack provides additional radial strength at the critical iliac—caval choke

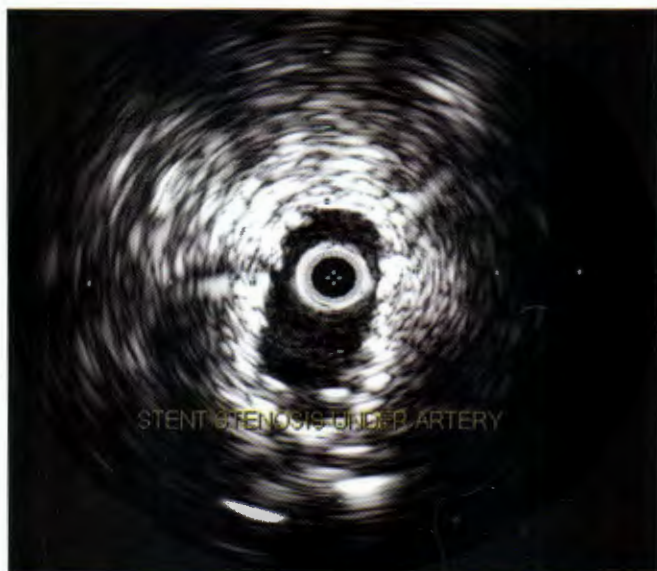point and may result in a reduction of reinterventions related to stent malfunction at the upper end. Longer term follow-up of the Z stent modification will show whether stent functionality and patency are in fact improved in the various disease subsets.

It is nearly impossible to precisely place the Wallstent at the iliac—caval junction even with IVUS guidance without risking stent retraction and recurrence. Nitinol stents with less tendency to migrate in such a fashion are nevertheless susceptible to compression at this location causing stenosis and symptom recurrence (Fig. 8) in addition to not being available in 16-mm sizes heretofore in the United States.

The braided Wallstent structure has generous interspaces and opposite iliac flow can be seen to flow through and around the stent on contrast venograms. We have, however, observed that passing a guidewire through the side of the braided structure may be difficult in some cases and occasionally impossible, suggesting that the interspaces between braided strands become filled with tissue over time.



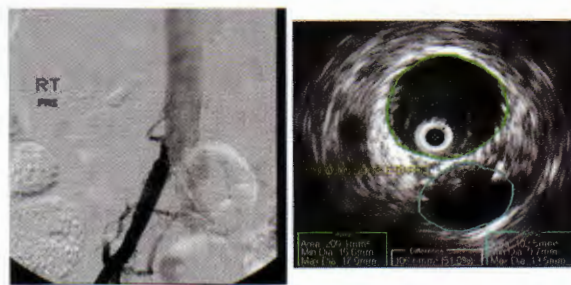
**Fig. 7.** Primary and secondary patency curves are shown for the Z modification. Eight stents were occluded, 6 of which were successfully reopened and 2 were lost.



**Fig. 8.** “Fish-mouthing” of Nitinol stent from compression at the iliac–caval choke point.

In that case, subacute jailing of flow may occur resulting in new onset or worsening of preexisting symptoms requiring a contralateral stent. The Z stent technique with very large inter-strut spaces should be immune to this problem.

With prior Wallstent technique, bilateral iliac vein stenting often involved compromises and resulted in reinterventions for stent malfunction after bilateral deployment (Fig. 9).<sup>11</sup> The end-to-side “kissing” or apposition technique without fenestration is clearly unsatisfactory as it leads to obstruction at the apposition point. The double-barrel technique is relatively free of problems, but cannot be used sequentially as the older barrel tends to compress the newly introduced barrel (Fig. 10).

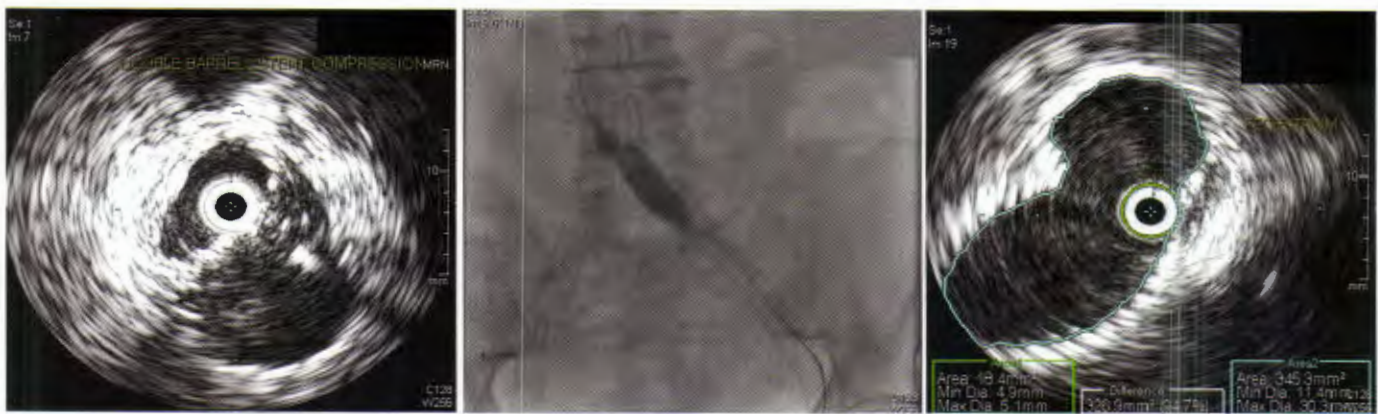

**Fig. 9.** Current bilateral deployment technique is problem-prone (see text). Stenosis at contact point between the stents with apposition technique (left) and compression of one barrel of double-barrel technique (right).

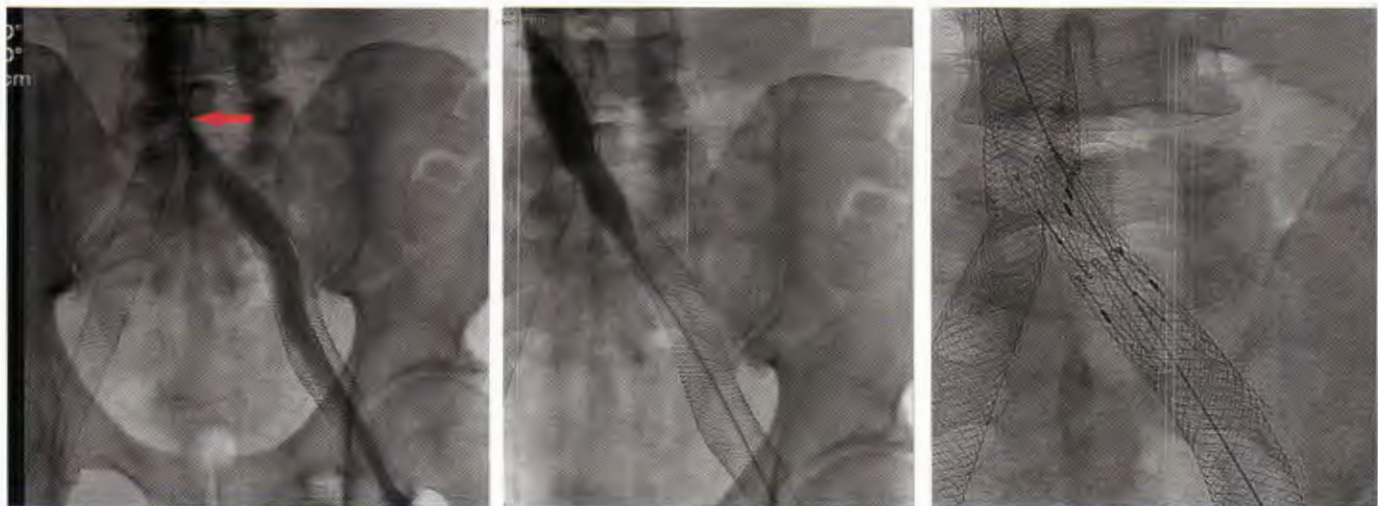Even in simultaneous bilateral deployment, compression of one of the barrels occurs in some instances. Even without such compressive effects, we have observed that each barrel constricts down to about 10- to 12-mm diameter over time within the inferior vena cava (24 mm). This may cause relative iliac outflow stenosis (normal diameter 16 mm) if the porosity is lost with tissue coverage. Inter-barrel fenestration has been required to relieve residual symptoms in a few cases with this problem.

Because contralateral symptoms have been observed to improve in some patients after unilateral stenting (presumably because of offloading of collaterals), simultaneous bilateral stenting may be premature in some instances. Sequential stenting with an interval for observation is the more cautious approach. The fenestration technique was clearly the choice in most cases needing bilateral stenting, but is afflicted with an increased need for reinterventions from a variety of stent malfunctions associated with it (Fig. 11).<sup>11</sup> The Z stent technique described herein is fast and easy in simultaneous or staged bilateral deployments and is virtually free of aforementioned technical difficulties. The technique has now become the standard.

All stents currently in use in the iliac veins in the United States are “off label” having originated for use elsewhere. An “ideal” stent for iliac–caval–femoral application will have unique requirements to meet the anatomic and pathologic characteristics specific for this location. It should be large, approximating the iliac vein size to decompress the periphery, flexible to accommodate the complex anatomical three-dimensional curvature but rigid at various choke points at the iliac–caval junction, at the hypogastric cross-over point and behind the inguinal ligament, yet be free of any tendency for fracture and erosions; it should accommodate



**Fig. 10.** Double-barrel deployment with severe compression of one of the barrels (*left*). This was corrected by an inter-barrel fenestration (*middle*). IVUS appearance of interbarrel fenestration (*right*).



**Fig. 11.** Fenestral stenosis (*arrow*) (*left*). It was corrected by balloon dilatation (*middle*) and Z stent deployment across the stenosis (*right*). Prior fenestration techniques

can also lead to jailing of contralateral stent flow by the stent passing through the fenestrum.

contralateral iliac flow without restriction and be easily deployable in bilateral applications. The Wall-stent fulfills many but not all these requirements and the Z stent modification improves on some of the deficiencies.

#### REFERENCES

1. Neglen P, Hollis KC, Olivier J, et al. Stenting of the venous outflow in chronic venous disease: long-term stent-related outcome, clinical, and hemodynamic result. *J Vasc Surg* 2007;46:979–90.
2. Raju S, Kirk O, Jones T. Endovenous management of venous leg ulcers. *J Vasc Surg* 2013;1:165–73.
3. Raju S, Darcey R, Neglen P. Unexpected major role for venous stenting in deep reflux disease. *J Vasc Surg* 2010;51:401–8. discussion, 408.
4. Raju S. Best management options for chronic iliac vein stenosis and occlusion. *J Vasc Surg* 2013;57:1163–9.
5. Raju S, Tackett P Jr, Neglen P. Reinterventions for nonocclusive iliofemoral venous stent malfunctions. *J Vasc Surg* 2009;49:511–8.
6. Negus D, Fletcher EW, Cockett FB, et al. Compression and band formation at the mouth of the left common iliac vein. *Br J Surg* 1968;55:369–74.
7. Raju S, Neglen P. Percutaneous recanalization of total occlusions of the iliac vein. *J Vasc Surg* 2009;50:360–8.
8. Raju S, Neglen P. High prevalence of nonthrombotic iliac vein lesions in chronic venous disease: a permissive role in pathogenicity. *J Vasc Surg* 2006;44:136–43. discussion, 144.
9. Neglen P, Raju S. Intravascular ultrasound scan evaluation of the obstructed vein. *J Vasc Surg* 2002;35:694–700.
10. Neglen P, Raju S. Balloon dilation and stenting of chronic iliac vein obstruction: technical aspects and early clinical outcome. *J Endovasc Ther* 2000;7:79–91.

11. Neglen P, Darcey R, Olivier J, et al. Bilateral stenting at the iliocaval confluence. *J Vasc Surg* 2010;51:1457–66.
12. Raju S, Owen S Jr, Neglen P. The clinical impact of iliac venous stents in the management of chronic venous insufficiency. *J Vasc Surg* 2002;35:8–15.
13. Neglen P, Berry MA, Raju S. Endovascular surgery in the treatment of chronic primary and post-thrombotic iliac vein obstruction. *Eur J Vasc Endovasc Surg* 2000;20:560–71.
14. Neglen P, Tackett TP Jr, Raju S. Venous stenting across the inguinal ligament. *J Vasc Surg* 2008;48:1255–61.
15. Kolbel T, Lindh M, Akesson M, et al. Chronic iliac vein occlusion: midterm results of endovascular recanalization. *J Endovasc Ther* 2009;16:483–91.