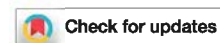

# A comparison between intravascular ultrasound and venography in identifying key parameters essential for iliac vein stenting



Myriam L. Montminy, MD, James D. Thomasson, MD, Guillermo J. Tanaka, MD, Lara M. Lamanilao, BS, William Crim, MS, and Seshadri Raju, MD, FACS, *Jackson, Miss*

## ABSTRACT

**Objective:** Deep venous stenting has become the primary treatment option for obstructive venous disease. Precise identification and quantification of the disease as well as localization of optimal landing zones are key elements to success. Compared with venography (anteroposterior projection), intravascular ultrasound (IVUS) seems to be more sensitive in determining those parameters. This study was a blinded comparison of the relative accuracy of venography compared with IVUS in determining key parameters essential for iliac vein stenting.

**Methods:** Between October 2013 and November 2015, there were 155 limbs (152 patients) that underwent an endovascular intervention for chronic iliofemoral vein stenosis. Venography and IVUS data were reviewed by vascular surgeons and radiologists, respectively, each blinded to the other to identify location and severity of maximal stenosis, location of iliac-caval confluence, and optimal distal landing zone. Data from venography were compared with data from IVUS. Maximal stenosis was defined as the most severe stenosis found among the four segments—common iliac vein, external iliac vein, common femoral vein, and infrarenal vena cava. IVUS was the “gold standard” for comparisons.

**Results:** Venography failed to identify lesion existence in 19% of limbs. The median maximal area stenosis was significantly higher with IVUS than with venography (69% vs 52%;  $P < .0001$ ). Furthermore, venographic correlation with IVUS for the anatomic location of maximal stenosis was present in only 32% of the limbs; venography missed the location of maximal stenosis in more than two-thirds of limbs. The iliac-caval confluence location on venography correlated with IVUS findings in only 15% of patients. In 74%, it was located higher with IVUS than with venography. The mean difference was one vertebral body. Agreement between venography and IVUS on location of the distal landing zone was only 26%. The distal landing zone defined with IVUS was lower than with venography in 64% of limbs.

**Conclusions:** Compared with IVUS, venography substantially and significantly misses stenotic lesions—their location and severity; venography also misidentifies the location of the iliac-caval confluence and the distal landing zone in the majority of limbs. Those differences between IVUS and venography suggest that IVUS is the better diagnostic and procedural tool in iliac-caval stenting. (*J Vasc Surg: Venous and Lym Dis* 2019;7:801-7.)

**Keywords:** IVUS; Venogram; Iliac vein stenosis; May-Thurner syndrome

Deep venous stenting is being increasingly used in the treatment of obstructive chronic venous disease (CVD). Adequate assessment of the location and degree of stenosis and delineation of venous anatomy for optimal landing zones are key elements in the success of those interventions.

The iliac-caval bifurcation must be identified to prevent undertreatment of proximal lesions while avoiding jailing of the contralateral iliac vein. Studies have shown a low

but significant rate of contralateral iliac vein occlusion ranging from 2% to 4% in patients with a stent extended into the inferior vena cava (IVC) to ensure full coverage of the proximal lesion.<sup>1-4</sup> An adequate distal landing zone must also be determined to prevent missed distal lesions that can lead to in-stent restenosis or occlusion.<sup>5</sup>

Venography is more accessible and less expensive to perform than intravascular ultrasound (IVUS). However, an increasing number of publications show that IVUS is significantly more sensitive than venography in identifying stenotic lesions in the iliac-caval segments even if multiplanar views are used.<sup>6-8</sup> Analysis of the Venogram vs IVUS for Diagnosing Iliac vein Obstruction (VIDIO) study data showed that clinical improvement after stenting is best predicted by IVUS measurement of area stenosis than by venographic measurement.<sup>9</sup> Evaluation of venography before the advent of venous stenting was limited to its sensitivity as a diagnostic tool in iliac vein stenosis. In the stent era, venography and increasingly IVUS are being used as procedural tools. In this capacity, much more than diagnostic sensitivity is required of the two imaging modalities.

From The RANE Center, St. Dominic's Memorial Hospital.

Author conflict of interest: S.R. holds U.S. patents in intravascular ultrasound diagnostics and venous stent design and receives stock/royalty from Veniti Inc.

Correspondence: Seshadri Raju, MD, FACS, The RANE Center, St. Dominic's Memorial Hospital, 971 Lakeland Dr, Ste 401, Jackson, MS 39216 (e-mail: [rajumd@earthlink.net](mailto:rajumd@earthlink.net)).

The editors and reviewers of this article have no relevant financial relationships to disclose per the Journal policy that requires reviewers to decline review of any manuscript for which they may have a conflict of interest.

2213-333X

Copyright © 2019 The Authors. Published by Elsevier Inc. on behalf of the Society for Vascular Surgery. This is an open access article under the CC BY-NC-ND license (<http://creativecommons.org/licenses/by-nc-nd/4.0/>).

<https://doi.org/10.1016/j.jvs.2019.03.015>

The aim of this study was to compare differences between venography and IVUS in identifying key parameters required to guide stent placement. These are localization and quantification of maximal stenosis, localization of iliac-caval confluence, and identification of optimal distal landing zone. IVUS is used as the "gold standard" for this comparison. This means that venography can never be better than IVUS but can be equal to or worse than IVUS.

## METHODS

Procedural data contemporaneously entered into an electronic medical records database were retrospectively reviewed for all new iliac vein stent placements (n = 210 limbs) for CVD between October 2013 and November 2015. All had IVUS-guided stent placement. There were 155 limbs in 152 patients that also had intraprocedural venography through the access sheath and are the subject of retrospective analysis. In the excluded stented limbs (55/210), intraoperative venography was not performed because of either allergy to contrast material/renal dysfunction or availability of recent venograms. The latter were not part of the study analysis because of variable technique and image quality; high inguinal access with poor inflow detail was a frequent shortcoming of preoperative venograms.

Some limbs had to be excluded from individual analysis. This is reflected in different number values displayed in relevant tables, and the reasons for exclusion are listed. IVUS data were used as the gold standard for all comparisons.

This is a single-center study and the procedures followed a prospectively set protocol. Informed consent of the patients was obtained. Institutional Review Board permission was granted for this study.

**Intraoperative venography.** Each patient underwent venography as the first step of intervention after venous access with an 11F sheath was obtained. The large size allows easy maneuverability of the large IVUS catheter (8.2F) and other instrumentation necessary for stenting if it is chosen on the basis of IVUS findings. Access complications have been very low despite the large sheath size and deep access location.<sup>3</sup> A midhigh access of the femoral vein was obtained, and its tip was placed below the lesser trochanter level to visualize the femoral-deep femoral confluence and the segments of interest above: common femoral vein (CFV), external iliac vein (EIV), common iliac vein (CIV), and adjacent IVC; 20 to 40 mL of contrast material was used as needed to obtain adequate delineation of the venous tree. Dynamic views (cine) with subtraction in the anteroposterior projection were recorded; rotational views (oblique, lateral) were not obtained. Magnification was optimized to include venous segments of interest and related bone landmarks. These cine images were reviewed retrospectively

## ARTICLE HIGHLIGHTS

- **Type of Research:** Single-center retrospective cohort study
- **Key Findings:** A blinded comparison of venography and intravascular ultrasound in 155 limbs undergoing stent placement to correct iliac vein stenosis found that venography missed a lesion or its location in 51% of the limbs ( $P < .0001$ ). The location of iliac vein confluence and the optimal distal landing zone were significantly different between the two techniques.
- **Take Home Message:** Intravascular ultrasound is superior to venography for procedural guidance during iliac vein stent placement.

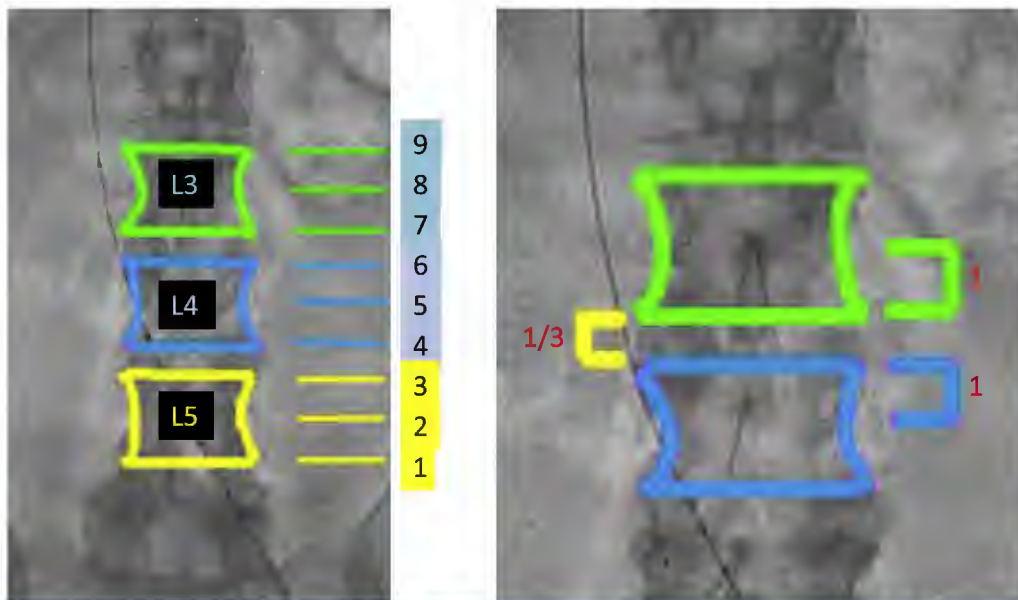
several months later by two vascular interventional radiologists with venous experience who were not involved in the procedure and were blinded to IVUS findings. The radiologists were provided a template of bone landmarks for determining the level of iliac confluence and distal landing zones. Percentage diameter stenosis per venogram was calculated by comparing the diameter at the level of maximal stenosis with the diameter of the nearest normal vein in the same segment. Diameter stenosis measurements were converted to area ( $\pi r^2$ ) for comparison with IVUS area stenosis data.

**IVUS.** IVUS was performed before balloon dilation and stent placement. A digital IVUS catheter with large-caliber vision (Visions EP .035; Volcano Corp, San Diego, Calif) with integrated planimetry software was used. Planimetry cross-sectional images (no video loop) of the smallest area (highest stenosis) in the CFV, EIV, CIV, and adjacent IVC were recaptured and stored. They were indexed to normal-caliber data for the vein segments as previously described.<sup>10</sup> The normal caliber of the CIV, EIV, and CFV have been determined to be 200 mm<sup>2</sup>, 150 mm<sup>2</sup>, and 125 mm<sup>2</sup>, respectively. These were obtained by IVUS observation of normal iliac vein segments, calculation based on Poiseuille's equation from known normal flow and pressure data and Young's scaling ratios. The adjacent "normal" segment was not used as a comparator as in venography (see later).

Based on percentage stenosis calculations present in each of the four vein segments, the site of maximal stenosis per the two techniques was determined.

The location of the iliac-caval confluence and the ideal distal landing zone identified by IVUS and venography were related to adjacent bone landmarks (Figs 1 and 2). In either case, it was based on the optimal zone free of disease, beyond the diseased segments. The landing zones per IVUS under fluoroscopy were used for actual stent placement. The landing zones per venography were identified months later by the interpreting

### Level of Iliac Confluence



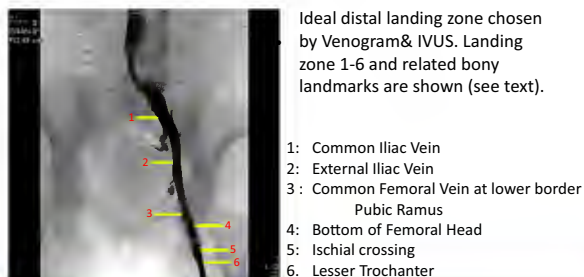
**Fig 1.** Location of the iliac-caval confluence on venography and intravascular ultrasound (IVUS) was recorded according to its vertebral body location from the bottom of L5 to the top of L3 with numerical identification of zones. Confluence location was related to the top, mid, or lower border of the vertebra (*left*). To quantify the difference in location between each imaging technique, a value of 1 point was accorded to each half of the vertebral body, and  $\frac{1}{3}$  point was accorded to each vertebral disk (*right*).

radiologists who are coauthors and were blinded to IVUS findings. This was based on venographic cine images with bone overlay.

The location of the iliac-caval confluence on venography and IVUS was recorded according to its reference bone location from the bottom of L5 to the top of L3. To quantify the difference in location between each imaging technique, a value of 1 point was accorded to each half of the vertebral body, and  $\frac{1}{3}$  point was accorded to each vertebral disk.

The ideal location of the distal landing zone on venography and IVUS was recorded according to the venous segment (CIV, EIV, CFV). Six numbered landing zones were identified, with zone 1 and zone 2 in the CIV and EIV, respectively. For the CFV, four zones numbered 3 to 6 were established: lower border of pubic ramus, bottom of femoral head, ischium, and upper border of lesser trochanter, respectively.

**Statistics.** A commercially available statistics program (Prism software; GraphPad Software Inc, La Jolla, Calif) was used for analysis. Independent samples *t*-test was used for continuous variables (percentage stenosis). Spearman  $\rho$  test and  $\chi^2$  test were used for categorical variables and ordinal data (level of confluence and landing zones). A multivariate analysis of variance was used for analysis of interval and ratio data. Significance was determined from *P* values with *t* distribution and *F* distribution tables. A *P* value  $<.05$  was considered significant.



Ideal distal landing zone chosen by Venogram & IVUS. Landing zone 1-6 and related bony landmarks are shown (see text).

- 1: Common Iliac Vein
- 2: External Iliac Vein
- 3: Common Femoral Vein at lower border Pubic Ramus
- 4: Bottom of Femoral Head
- 5: Ischial crossing
- 6: Lesser Trochanter

**Fig 2.** Location of distal landing zone on venography and intravascular ultrasound (IVUS) was recorded according to the venous segment (common iliac vein [CIV], external iliac vein [EIV], common femoral vein [CFV]). Six numbered landing zones were identified, with zone 1 and zone 2 in the CIV and EIV, respectively. For the CFV, four zones numbered 3 to 6 were established: lower border of pubic ramus, bottom of femoral head, where the vein crosses the ischium, and lesser trochanter, respectively.

### RESULTS

The study included 155 limbs in 152 patients. The maximal stenosis analysis included 115 limbs; confluence analysis, 128 limbs; and distal landing zone analysis, 99 limbs. Demographic details are shown in Table 1. CVD was post-thrombotic in 72% and nonthrombotic in 28% of the limbs, respectively.

**Table I.** Demographics of 152 patients (155 limbs) in comparison of venography and intravascular ultrasound (IVUS)

Age, years, mean (SD)	59 (13)
Male	45 (30)
White	87 (63)
Left leg	95 (61)
Right leg	57 (37)
Both legs	3 (2)
Nonthrombotic CVD	42 <sup>a</sup> (28)
Post-thrombotic CVD	107 <sup>a</sup> (72)

CVD, Chronic venous disease; SD, standard deviation.  
Values are reported as number (%) unless otherwise indicated.  
<sup>a</sup>Data missing in six limbs.

**Maximal stenosis.** Venography was unable to identify lesion existence in 19% of the limbs (that is, no lesion was visible; Table II). The mean area stenosis, when it was identified on venography, was significantly less than with IVUS (52% vs 69%, respectively;  $P < .0001$ ). However, venographic localization (segment) of maximal stenosis significantly differed from IVUS, rendering the disparity even greater; agreement was present in only 32% of the limbs and was off in 68% of the limbs.

IVUS identified the CIV as the location of maximal stenosis in 78%. On venography, the CIV was the location of maximal stenosis in only 34%, the EIV in 36%, and the CFV in 29%. Most of the discordance between venography and IVUS was related to CIV stenosis. IVUS could detect the presence of a lesion but could image it only partially in 23 limbs because of the absence of a

**Table II.** Maximal stenosis<sup>a</sup> on venography vs intravascular ultrasound (IVUS; N = 115 limbs<sup>b</sup>)

	Maximal area stenosis, %	P value	
Venography	52 (0-100)	<.0001	
IVUS	69 (50-90)		
IVUS stenosis invisible on venography		27 (19)	
Segment location agreement, venography vs IVUS, for maximal stenosis		46 (32)	
Location of stenosis			
	Venography <sup>c</sup>	IVUS <sup>c</sup>	
		P value	
CFV	34 (29)	8 (6)	<.0001
EIV	42 (36)	23 (16)	
CIV	40 (34)	112 (78)	
IVC	0	1 (1)	

EIV, External iliac vein; CFV, common femoral vein; CIV, common iliac vein; IVC, inferior vena cava.

Categorical variables are presented as number (%). Continuous variables are presented as median (range).

<sup>a</sup>The most severe of the stenoses present among the four iliac-caval-femoral segments. Only visible venographic stenoses were included for area stenosis calculation.

<sup>b</sup>Of 155 limbs, 40 were excluded from analysis because stenosis detail was poor on venography (17 limbs) or IVUS (23 limbs); see text.

<sup>c</sup>More than one lesion was found per venogram or IVUS image.

centering mechanism. The presence of the lesion was confirmed by waisting of the balloon. These limbs had to be excluded from maximal stenosis calculations because of incomplete imaging.

**Iliac-caval confluence.** Venography could not definitively identify the confluence level in 17 limbs (13%). The level of iliac-caval confluence identified on venography agreed with IVUS in only 15% of the limbs (Table III). The confluence was located higher on IVUS than with venography in 74% and lower in 11% of limbs. The average difference was one vertebral body. Of note, IVUS confluence level was unexpectedly high, as high as L3, in 12 (11%) of the limbs.

**Distal landing zone.** Agreement on location of the distal landing zone between venography and IVUS was present in only 26% of the limbs (Table IV). When there was no agreement, the distal landing zone was higher in 64% with venography compared with IVUS. The most common distal landing zone identified with IVUS was zone 4 in 58% (bottom of femoral head); with venography, zone 3 (pubic ramus) was the most common landing zone in 34%. A suprainguinal landing zone (zone 2) was chosen in 17% on venography but in only 3% on IVUS.

## DISCUSSION

**Venography vs IVUS.** Venography is the older method, having been in use for nearly a century. Its shortcomings were recognized even in early studies, in which its sensitivity to iliac-caval lesions was estimated to be only  $\approx 50\%$  compared with surgical findings.<sup>11,12</sup> Both technique and technology have vastly improved since. Even

**Table III.** Iliac-caval confluence, venography vs intravascular ultrasound (IVUS; N = 128 limbs<sup>a</sup>)

Confluence location	IVUS	Venography
Lower L5 (1)	10	37
Middle L5	15	23
Upper L5	17	37
Lower L4	37	27
Middle L4	31	4
Upper L4	6	0
Lower L3	10	0
Middle L3	2	0
Upper L3 (9)	0	0

### Location agreement, venography vs IVUS

Iliac-caval confluence location	%
Agreement on location	15
Location higher on IVUS	74
Location lower on IVUS	11

<sup>a</sup>Of 155 limbs, 27 were excluded from analysis because a contralateral stent was present in 4 limbs, venography could not definitively identify the confluence level in 17 limbs, and data were missing in 6 limbs.

**Table IV.** Optimal distal landing zone, venography vs intravascular ultrasound (IVUS; N = 99 limbs<sup>a</sup>)

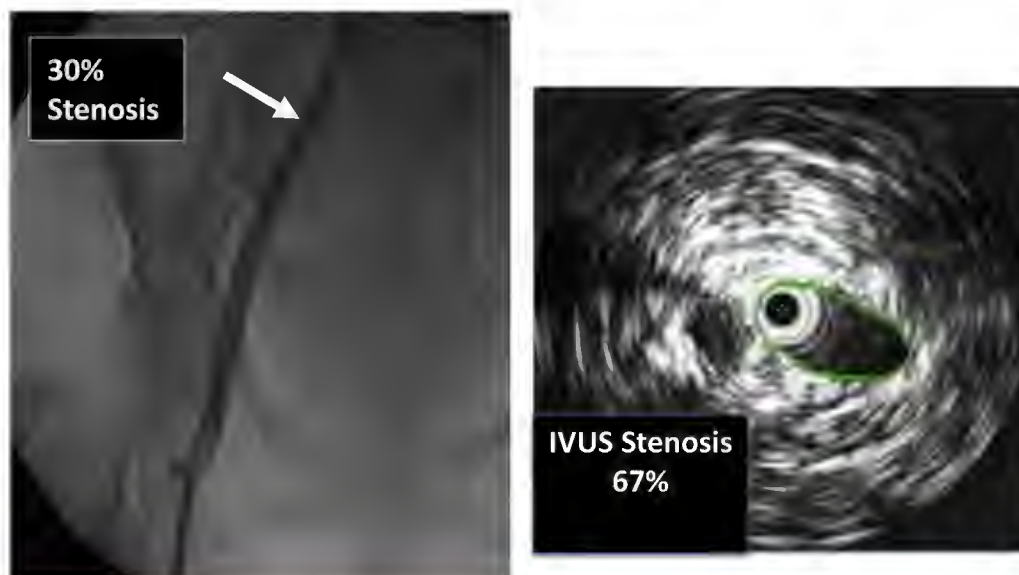Mean landing zone level		P value	
Venography	3.55	.3098	
IVUS	3.93		
Distal landing zone location		%	
Agreement on location		26	
Location higher on IVUS		36	
Location lower on IVUS		63	
Location of distal landing zone, No. (%)			
	Venography	IVUS	P value
2	17 (17)	3 (3)	.0006
3	34 (34)	23 (23)	
4	31 (31)	57 (58)	
5	11 (11)	10 (10)	
6	6 (6)	6 (6)	

<sup>a</sup>Of 155 venograms, 36 were excluded from analysis because venographic stenosis was invisible in 28 limbs and showed <30% area stenosis in eight limbs.

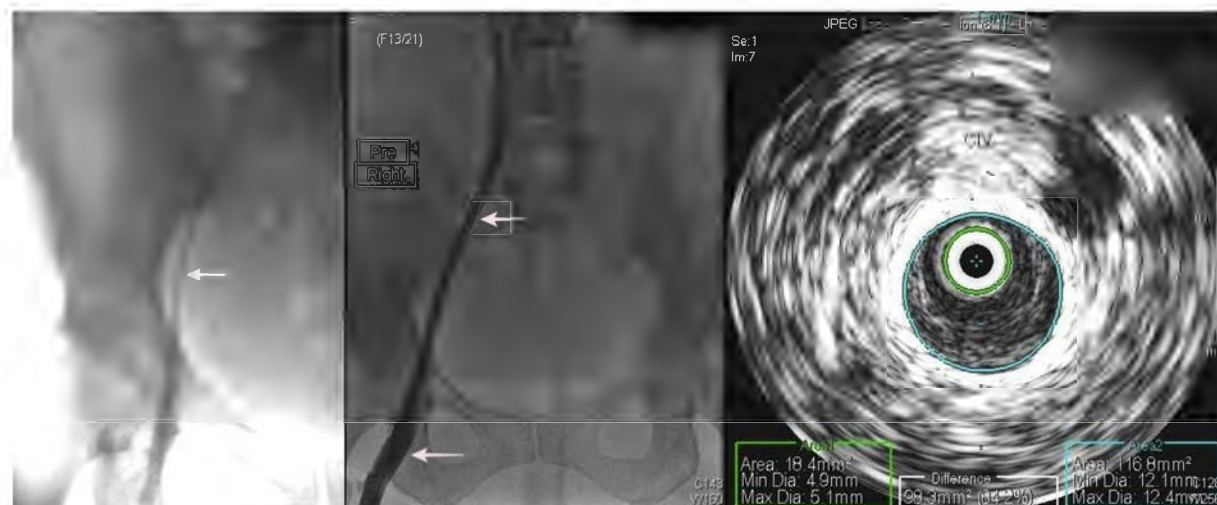
so, adequate delineation of lesions requires good concentration of contrast material, meaning that a transfemoral injection is required and traditional ascending venography with foot injection is not satisfactory. Too much or too little contrast material can result in masking of lesions. In the era of venous stenting, much more

detail than mere identification of lesions is demanded of venography to provide guidance during stent placement. Both major and minor lesions have to be identified to place the stent without skipping lesions. Preferably, the degree of stenosis of individual lesions has to be measured. These factors will determine the proper landing zones for stent placement. This study highlights that venography compared with IVUS is likely to be deficient in many of these desirable attributes; the correct location of maximal stenosis on venographic interpretation was discordant from IVUS in the majority of limbs. Nearly 20% of IVUS-identified lesions were missed altogether. Most of these errors occurred at the confluence at the proximal arterial crossover point. The lesion is coronal, not sagittal. The anteroposterior compression of the vein at the lesion site results in venographic signs that are subtle (broadening, contrast translucency, or minor stenosis in frontal profile) that are easily missed.<sup>13</sup> The lesion extends to a variable distance into the vena cava; intraluminal webs and strands often render the lesion more severe than it may seem on frontal images. The contrast material becomes diluted at the confluence from contralateral flow that tends to mask these finer details. Contrast-related imaging difficulties result in misidentification of proper distal landing zone both proximal and distal. This may potentially result in inadequate stenting and persistent or recurrent symptoms requiring reinterventional correction.<sup>5</sup>

## Location and Degree of Stenosis



**Fig 3.** Disparity between venography and intravascular ultrasound (IVUS) in estimating maximal stenosis. In the example shown, the common iliac vein (CIV) was identified as the site of maximal stenosis with an estimated diameter stenosis (53% area stenosis) as shown (left). IVUS area stenosis at the same location was higher at 67% area stenosis (right). The major disparity between the two techniques, however, was in identifying the segment of maximal stenosis. The two techniques identified different segments as the site of maximal stenosis in more than two-thirds of limbs. See text.



**Fig 4.** Extreme examples of Rokitansky stenosis are easily recognized (*left*). Milder examples are less obvious (*middle*). A subtle sign is the smaller caliber of the iliac vein compared with the common femoral vein (CFV; *arrows*). On intravascular ultrasound (IVUS) examination, the common iliac vein (CIV) measured 116 mm<sup>2</sup>, a 42% area of stenosis (*right*).

The substantial discrepancy (biased toward a lower level than actual) in venographic identification of the iliac confluence level is striking. There is merging of contrast-delineated iliac vein contours for some distance (one vertebral body per this analysis) below the actual level of the ostia. In some limbs, the confluence may encompass a divider or septum of some length rather than two clearly separated ostia coming together at an angle. Even with the advantages of IVUS imaging, the confluence remains a difficult yet unsolved technical challenge in iliac vein stenting.<sup>14</sup> The imaging problems with venography also carry over to completion venography, in which incomplete apposition of stent members at overlaps is less visible than with IVUS. Besides these imaging difficulties, the main disadvantage of venography is lack of an internal scale for precise caliber metrics (Fig 3). As a result, long diffuse stenosis unique to the iliac veins may be missed altogether except in extreme cases (Fig 4). The noted significant difference between venography and IVUS in percentage stenosis estimations is in part due to the different reference index used. Venographic stenosis is indexed to the adjacent normal segment; IVUS is indexed to predetermined normal caliber for the segment. Measurements of pre-stent and poststent caliber appear to be important in diagnosis and outcomes of iliac vein stenosis.<sup>10,15</sup> Venography is still a desirable adjunct in iliac vein stenting. It provides a panoramic view of the pathologic process, including collaterals. Its roadmapping capabilities are a distinct asset, particularly in recanalization of chronic total occlusions. In our view, IVUS is distinctly inferior in these aspects. IVUS may miss or provide only a partial image of certain lesions situated at the hypogastric-iliac and iliac-caval confluences.<sup>16</sup> This derives from the

absence of a centering mechanism for the device. This resulted in exclusion of 23 limbs (Table II) for which IVUS could not provide a full image of the lesion to allow accurate measurement.

The resolution of the IVUS catheter is 350  $\mu$ m according to the manufacturer. There are no published data on this score for contrast venography, a legacy technique. Findings in this analysis suggest that venographic resolution is inferior. Besides superior imaging properties and caliber metrics, IVUS has the advantage of minimal radiation risk (from brief fluoroscopy) even with repeated use necessary during the stenting procedure. In patients with contraindications to use of contrast material, it is the only practical guidance tool currently available for iliac vein stenting. An estimated 15% of limbs in our current stent practice undergo interventional or reinterventional procedures solely with use of IVUS and fluoroscopy.

**Iliac-caval confluence.** Anatomic texts place the location of the iliac venous confluence at the level of the fifth lumbar vertebral body. Early literature describing necropsy findings in May-Thurner syndrome attributed the prominence of the L5 vertebral body as a component of the compressive disease.<sup>11,17</sup> The confluence was located by IVUS at this location in only a third of the limbs in this series, with the majority situated at L4 level; 9% were surprisingly even higher at the L3 vertebral body level. We hypothesize that post-thrombotic longitudinal contraction of the vena cava results in pulling up of the confluence cephalad. The normal IVC has considerable “slack” to accommodate an accordion-like shortening and lengthening with respiratory movements. The liver and diaphragm to which it is attached move down by as

much as 3 to 4 cm (a vertebral body) during inspiration. We have noticed that higher confluence level drops down in some cases after balloon dilation, occasionally by the length of a full vertebral body.

The VIDIO study showed that IVUS planimetry of iliac vein stenosis had better correlation with clinical outcome compared with venography.<sup>9</sup> There are additional advantages with IVUS in choice of optimal landing zones as described.

**Study limitations.** The study is limited to a comparison between venography and IVUS as a procedural tool during iliac vein stenting. It is unknown whether these translate into differences in primary or secondary patency rates. This will require follow-up information on patient cohorts stented with each of the two imaging modalities.

## CONCLUSIONS

Venography and IVUS were compared by their utility in guiding iliac vein stent placement for CVD. A key element in accomplishing the procedure is to identify the stenosis—its location and severity; the upper landing zone at the iliac confluence and the lower landing zone at a disease-free segment below have to be identified for proper stent placement. Venography was found to be inferior to IVUS in all of these key parameters. The relative inadequacy of venography at its root is related to contrast-related imaging deficiency and lack of internal scale for caliber metrics. IVUS is comparatively superior and the better tool to guide iliac vein stenting. It is unknown whether these differences would result in different clinical outcomes.

A preliminary analysis of these data was presented by Erin Murphy, MD, at the 2016 Vascular Annual Meeting of the Society for Vascular Surgery, National Harbor, Md, June 8-11, 2016. Professional statistical consultation was provided by Jennifer Stafford, PhD.

## AUTHOR CONTRIBUTIONS

Conception and design: SR

Analysis and interpretation: MM, JT, GT, SR

Data collection: MM, JT, GT, LL, WC, SR

Writing the article: MM, LL, WC, SR

Critical revision of the article: MM, JT, GT, SR

Final approval of the article: MM, JT, GT, LL, WC, SR

Statistical analysis: MM, LL, WC, SR

Obtained funding: Not applicable

Overall responsibility: SR

## REFERENCES

1. Khairy SA, Neves RJ, Hartung O, O'Sullivan GJ. Factors associated with contralateral deep venous thrombosis after ilioacaval venous stenting. *Eur J Vasc Endovasc Surg* 2017;54:745-51.
2. Murphy EH, Johns B, Varney E, Buck W, Jayaraj A, Raju S. Deep venous thrombosis associated with caval extension of iliac stents. *J Vasc Surg Venous Lymphat Disord* 2017;5:8-17.
3. Neglen P, Hollis KC, Olivier J, Raju S. Stenting of the venous outflow in chronic venous disease: long-term stent-related outcome, clinical, and hemodynamic result. *J Vasc Surg* 2007;46:979-90.
4. Raju S, Neglen P. Percutaneous recanalization of total occlusions of the iliac vein. *J Vasc Surg* 2009;50:360-8.
5. Raju S, Tackett P Jr, Neglen P. Reinterventions for non-occlusive iliofemoral venous stent malfunctions. *J Vasc Surg* 2009;49:511-8.
6. Gagne PJ, Tahara RW, Fastabend CP, Dzieciuchowicz L, Marston W, Vedantham S, et al. Venography versus intravascular ultrasound for diagnosing and treating iliofemoral vein obstruction. *J Vasc Surg Venous Lymphat Disord* 2017;5:678-87.
7. Neglen P, Berry MA, Raju S. Endovascular surgery in the treatment of chronic primary and post-thrombotic iliac vein obstruction. *Eur J Vasc Endovasc Surg* 2000;20:560-71.
8. Neglen P, Raju S. Intravascular ultrasound scan evaluation of the obstructed vein. *J Vasc Surg* 2002;35:694-700.
9. Gagne PJ, Gasparis A, Black S, Thorpe P, Passman M, Vedantham S, et al. Analysis of threshold stenosis by multiplanar venogram and intravascular ultrasound examination for predicting clinical improvement after iliofemoral vein stenting in the VIDIO trial. *J Vasc Surg Venous Lymphat Disord* 2018;6:48-56.e1.
10. Raju S, Buck WJ, Crim W, Jayaraj A. Optimal sizing of iliac vein stents. *Phlebology* 2018;33:451-7.
11. Negus D, Fletcher EW, Cockett FB, Thomas ML. Compression and band formation at the mouth of the left common iliac vein. *Br J Surg* 1968;55:369-74.
12. Thomas ML, Fletcher EW, Cockett FB, Negus D. Venous collaterals in external and common iliac vein obstruction. *Clin Radiol* 1967;18:403-11.
13. Raju S, Neglen P. High prevalence of nonthrombotic iliac vein lesions in chronic venous disease: a permissive role in pathogenicity. *J Vasc Surg* 2006;44:136-43; discussion: 144.
14. van Vuuren T, Doganci S, Wittens CH. Patency rates and clinical outcomes in a cohort of 200 patients treated with a dedicated venous stent. *J Vasc Surg Venous Lymphat Disord* 2018;6:321-9.
15. Raju S, Crim W, Buck W. Factors influencing peripheral venous pressure in an experimental model. *J Vasc Surg Venous Lymphat Disord* 2017;5:864-74.
16. Raju S, Davis M. Anomalous features of iliac vein stenosis that affect diagnosis and treatment. *J Vasc Surg Venous Lymphat Disord* 2014;2:260-7.
17. May R, Thurner J. The cause of the predominantly sinistral occurrence of thrombosis of the pelvic veins. *Angiology* 1957;8:419-27.

Submitted Jul 30, 2018; accepted Mar 19, 2019.