

# Endovascular management of chronic total occlusions of the inferior vena cava and iliac veins



Erin H. Murphy, MD, Blake Johns, BS, Elliot Varney, BS, and Seshadri Raju, MD, Jackson, Miss

## ABSTRACT

**Objective:** Percutaneous recanalization and stenting is currently the standard of care for symptomatic chronic total occlusions (CTOs) of the iliofemoral veins. CTO lesions involving the inferior vena cava (IVC) present a more complex patient subset. In this series we describe our single-center experience with endovascular recanalization of symptomatic occlusions of the IVC.

**Methods:** Patients were evaluated with duplex ultrasound imaging, venous function tests, and venography before intervention. Occluded segments were recanalized, balloon dilated, and stented. The basic stent technique modified over time to accommodate the ilio caval junction, presence of IVC filters, and lesions extending to the renal veins and atrium.

**Results:** Between November 2000 and August 2015, 71 patients (41 men [58%]) underwent IVC endovascular recanalization procedures for symptomatic chronic IVC occlusions. Patients were an average age of 51 years (range, 23-77 years). Underlying contributing factors for venous occlusion included IVC filter occlusion in 38 (54%), caval ligation/clipping in 4 (6%), and hypercoagulable disorder in 27 (38%). The technical success rate was 85% (n = 60). The proximal extent of the stents were infrarenal in 40 (67%), suprarenal in 11 (18%), or intrathoracic in 9 (15%). There was minimal perioperative morbidity (2 hematomas, 1 renal failure) and no postoperative mortality. Average follow-up was  $48.0 \pm 43.3$  months (range, 6-172 months). Primary, primary assisted, and secondary patency rates at 60 months were 52%, 85%, and 93%, respectively. Significant improvement in pain and swelling was seen in 91% and 83%, respectively; and complete cumulative relief of pain and swelling was 66% and 41% respectively. Ulcers were present in 18 patients and healed completely without recurrence in 14 (78%) after recanalization. The Venous Clinical Severity Score was  $8.4 \pm 5.1$  (range, 4-27) before the intervention and  $3.9 \pm 3.2$  (range, 0-14) after the intervention ( $P < .001$ ).

**Conclusions:** Endovascular recanalization of chronic total IVC occlusions can be performed with minimal morbidity and mortality. When successful, symptoms can be substantially improved, with excellent patency. (J Vasc Surg: Venous and Lym Dis 2017;5:47-59.)

Chronic total occlusion (CTO) of the inferior vena cava (IVC) can have a varied presentation, ranging from asymptomatic disease to severe debilitating lower extremity edema, hyperpigmentation, and painful ulceration. Anticoagulation is essential to prevent further loss of collaterals but is not an effective isolated treatment for patients with symptomatic occlusions. Open reconstruction for femoral and ilio caval occlusion with femorocaval bypass is associated with significant early morbidity

and low patency rates.<sup>1</sup> Similarly, angioplasty does not provide effective or durable results.<sup>2</sup> Endovascular reconstruction with iliofemoral stents has become the first-line intervention for symptomatic iliofemoral occlusions and has now been reported for IVC CTOs. In this series, we describe our single-center experience with endovascular recanalization and stenting for symptomatic IVC CTOs with midterm outcomes.

## METHODS

**Patients.** Records were reviewed for all patients who underwent an endovascular intervention for a symptomatic chronic (>30 day) IVC occlusion at our institution between November 2000 and August 2015. The analysis included 71 patients. Data were captured prospectively and reviewed retrospectively. Institutional Review Board Approval was obtained, with informed consent waived secondary to the retrospective nature of the medical record review. Preoperative details collected and reviewed included demographics, clinical history, and details of the clinical examination, laboratory results, and diagnostic testing.

CEAP and Venous Clinical Severity Score (VCSS) scores were recorded. Pain was assessed using a visual analog

---

From the RANE Center for Venous and Lymphatic Diseases at St Dominic's Memorial Hospital.

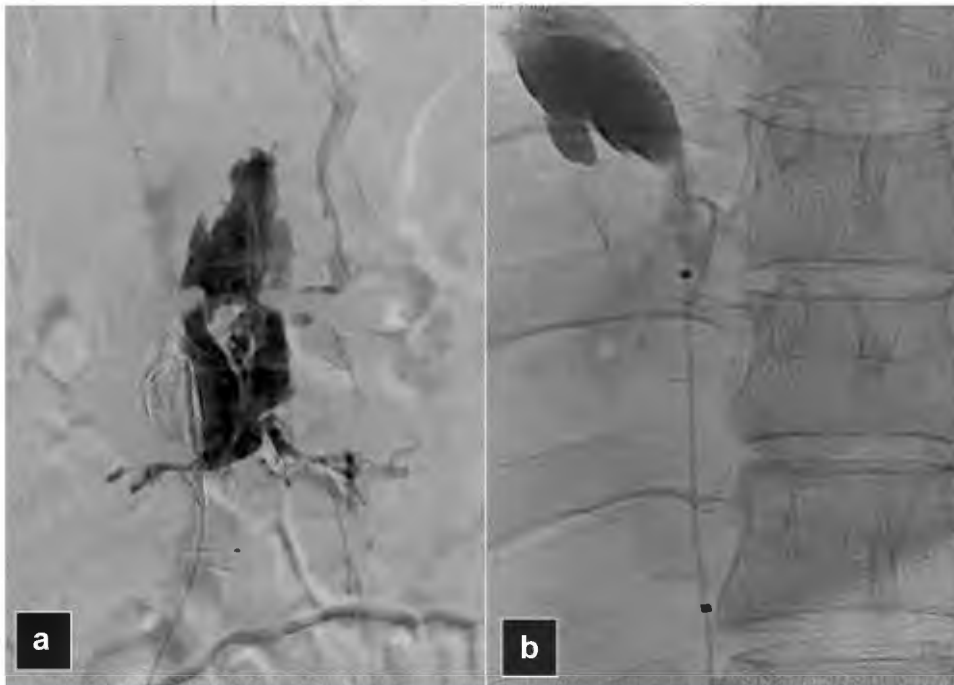Author conflict of interest: S.R. holds a United States patent regarding intravascular ultrasound diagnostics of cerebrovascular disease and stock in Veniti, Inc. E.H.M. is a consultant and National Primary Investigator for Medtronic. Presented at the Fortieth Annual Meeting of the Southern Association for Vascular Surgery, Cancun, Mexico, January 20-23, 2016.

Correspondence: Erin H. Murphy, MD, The RANE Center at St Dominic's Memorial Hospital, 971 Lakeland Dr, Ste 401, Jackson, MS 39216 (e-mail: [erinmurphy79@gmail.com](mailto:erinmurphy79@gmail.com)).

The editors and reviewers of this article have no relevant financial relationships to disclose per the Journal policy that requires reviewers to decline review of any manuscript for which they may have a conflict of interest.

2213-333X

Copyright © 2016 by the Society for Vascular Surgery. Published by Elsevier Inc. <http://dx.doi.org/10.1016/j.jvsv.2016.07.005>



**Fig 1. a and b,** Perforations during recanalization are innocuous and not a reason for aborting the procedure. If the recanalization is unsuccessful, these will not have flow to sustain them. Alternatively, if the recanalization is successful, the venous pressure is low enough that flow will continue through the path of least resistance, the now open stent, and the perforation will seal.

scale graded from 0 to 10, with 10 being most severe. Swelling was assessed as grade 0, absent; grade 1, nonobvious pitting; grade 2, visible ankle edema; grade 3, visible swelling to the knee; and grade 4, massive, involving the entire limb. Swelling was further qualified by time to maximum swelling after standing up as A (>8 hours), B (3-4 hours), C ( $\leq$ 1 hour), and D (persistent).

**Initial evaluation.** Suspicion for chronic venous obstruction was based on clinical history and findings of lower extremity pain with edema, hyperpigmentation, lipodermatosclerosis, or venous ulceration, or a combination of these. A diagnosis of IVC and iliofemoral venous occlusion was made with duplex ultrasound imaging and venography. All patients underwent evaluation for thrombophilia: protein C, protein S, and anti-thrombin III deficiency, lupus anticoagulant, anti-cardiolipin antibody, anti-B2 glycoprotein antibody, anti-phosphatidyl serine antibody, factor V Leiden mutation, prothrombin G20210A mutation, factor VII activity, factor XI activity, and homocysteine level.

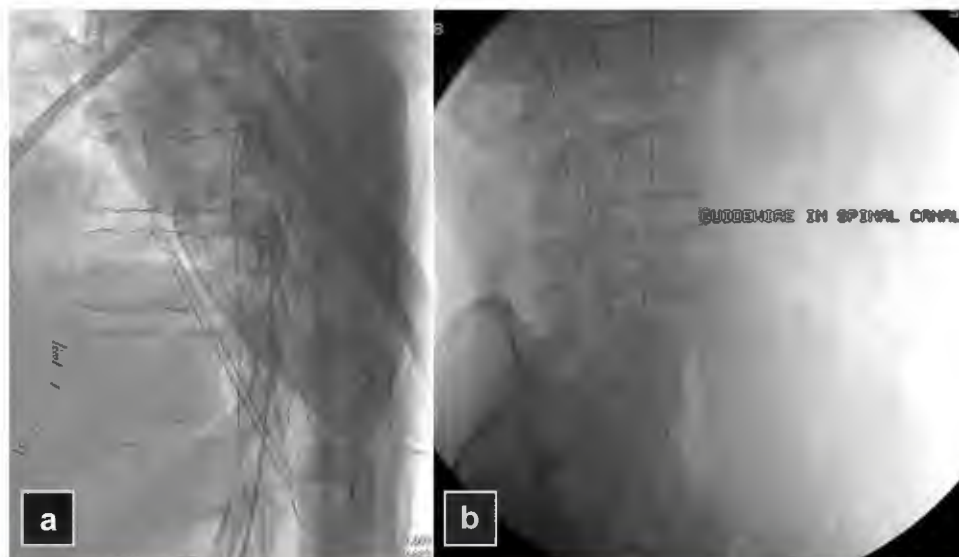
**Endovascular intervention.** The techniques described are modified from previously described CTO recanalization techniques.<sup>3-5</sup> Procedures were performed in the endovascular suite with the patient supine and general anesthesia. Ultrasound-guided percutaneous access was obtained in the ipsilateral femoral or profunda vein in the middle to upper thigh. Patients were procedurally

anticoagulated with bivalirudin (75 mg) or unfractionated heparin (5000 units).

An initial venogram was used to guide the procedure. Visualization of contrast, often appearing as a string sign within the trabeculated vein, was targeted when seen. CTO crossing was performed with a 0.035-inch Glidewire (Terumo, Somerset, NJ) and support catheter. A straight Glidewire without a loop often works well for traversing trabeculated vein. Support with long 6F or 7F sheaths was used during recanalization.

Perforations are common, innocuous, and are not a cause to abort the procedure (Fig 1). The wire is expected to advance lateral to the vertebral column on the patient's right side. Tracking along the center of the vertebral column suggests wire entry into the spinal plexus (Fig 2). Lateral views can provide additional orientation, but contrast injection is rarely used, often confusing operators and leading unnecessarily to procedure termination. If perforation is suspected, catheter/wire is simply withdrawn and redirected.

Entry into the IVC is characterized by easy advancement of the wire into the right atrium, which usually lies along the tenth rib. Venography and intravascular ultrasound (IVUS) imaging were used to confirm IVC and iliofemoral occlusion, determine lesion extent, and confirm re-entry. Proximal and distal landing zones for stent placement were determined by IVUS imaging in venous segments with the least occlusive disease.



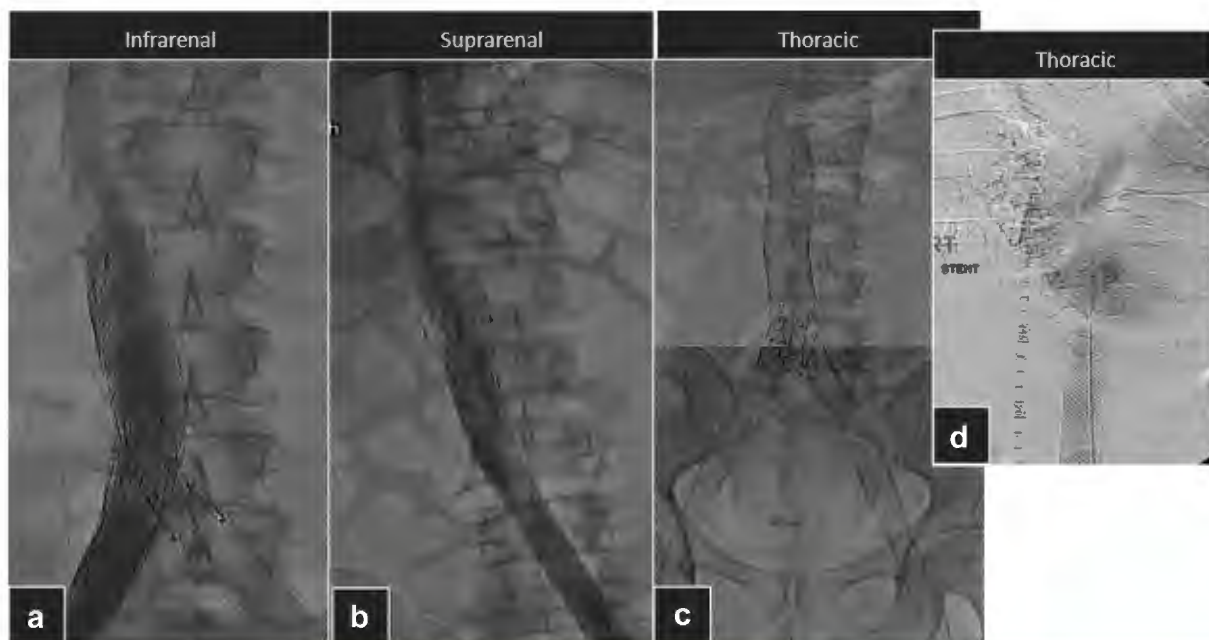
**Fig 2.** Glidewire (Terumo, Somerset, NJ) passage along the center of the vertebral column is consistent with passage within the spinal plexus. **a** and **b**, Lateral views may help to clarify wire location.

The proximal landing zone was infrarenal in 40 patients, suprarenal in 11, or intrathoracic in 9 (Fig 3). Stents were placed across the renal or hepatic vein entry, or both, as necessary. Intrathoracic stents may be taken to the level of the atrium but not into the atrium. The common femoral vein was the distal landing target in all but two patients, with stents extending across the inguinal ligament; the remaining two limbs were extended only into the external iliac vein.

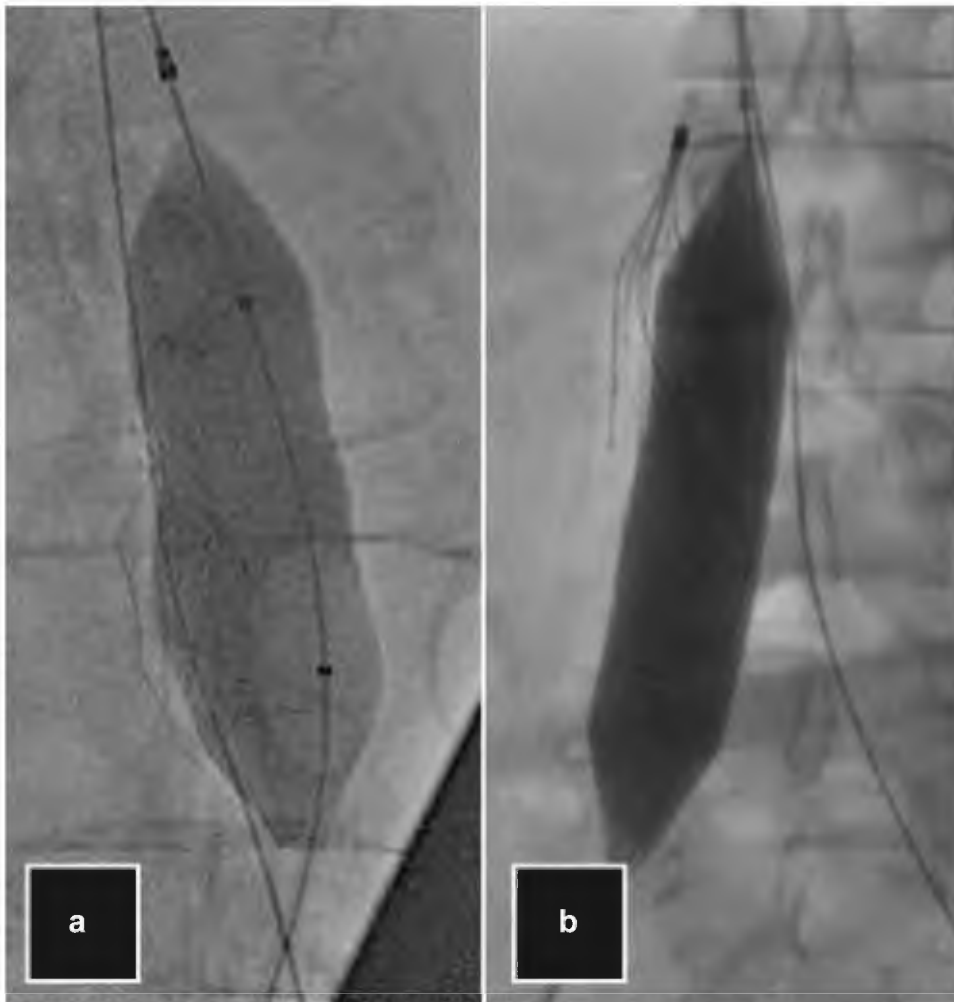
Predilation with balloon angioplasty was performed with large (16- to 24-mm) noncompliant balloons, routinely

inflated to high pressure (16-18 atm), in all occluded segments before stenting. Serial dilation is generally not necessary. On occasion, a smaller balloon may be needed to facilitate initial passage of the IVUS catheter.

IVC filters (IVCF) were incorporated in the occlusion in 38 patients. When occluded filters were successfully crossed, they were crushed and displaced laterally during angioplasty (n = 33). In attempt to minimize complications, filters were displaced to the right of the abdomen, away from the aorta and duodenum when feasible (Fig 4).



**Fig 3.** Proximal stent landing zones were determined by the least diseased venous segment on intravascular ultrasound (IVUS) imaging. Stents were landed **(a)** infrarenal, **(b)** suprarenal, or **(c)** intrathoracic, and **(d)** sometimes as high as the right atrium.



**Fig 4.** When feasible, inferior vena cava filters (IVCFs) are crushed laterally to the right side of the abdomen to avoid jailing struts near the duodenum and aorta. Here you can see an **(a)** Optease (Cordis, Miami Lakes, Fla) and **(b)** Günther Tulip (Cook Medical Inc, Bloomington, Ind) filter crushed during balloon angioplasty with right lateral displacement.

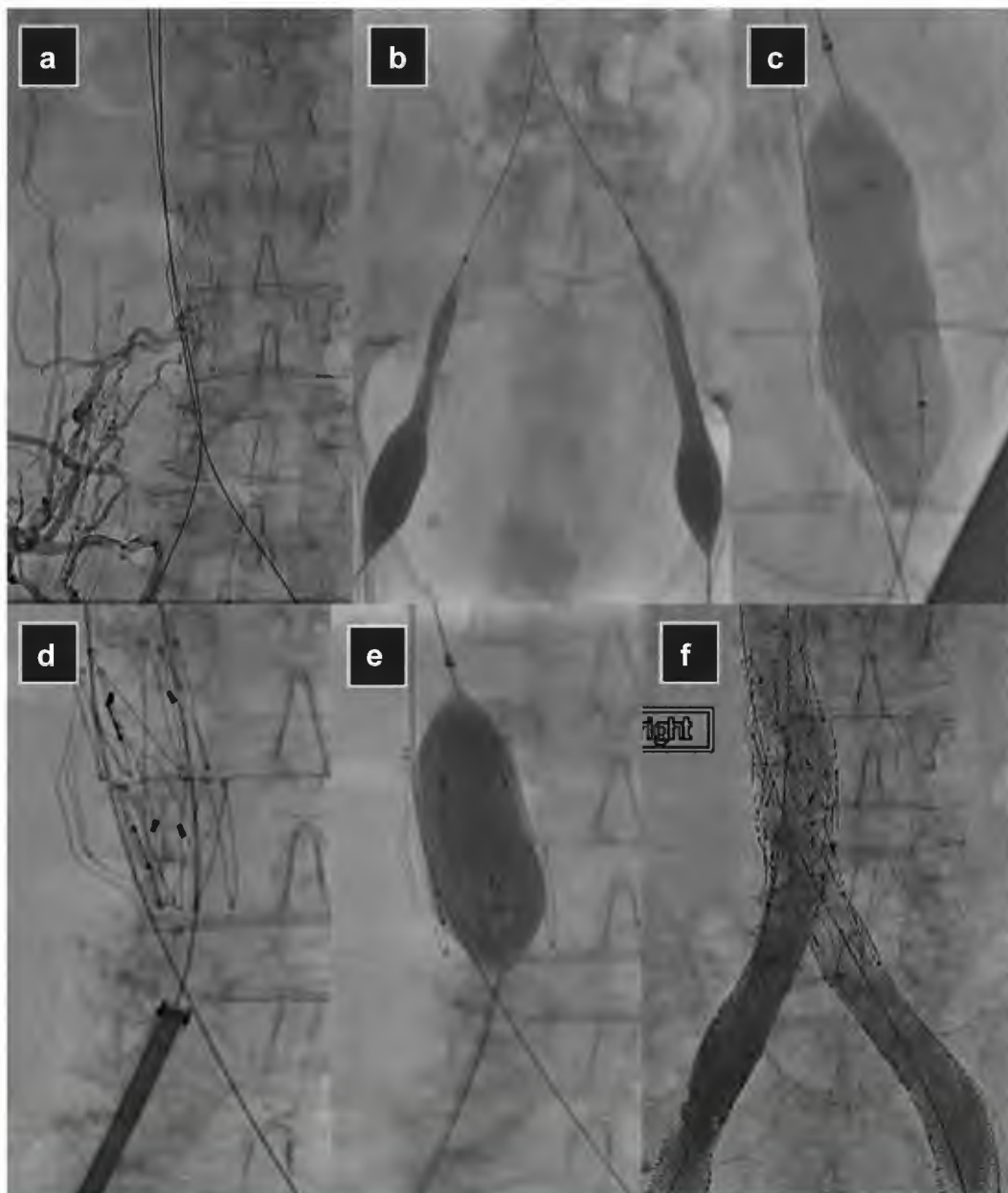
Self-expanding braided stainless steel Wallstents (Boston Scientific, Marlborough, Mass) with a minimum overlap of 20 mm were used in all patients. Gianturco Z-stents (Cook Medical Inc, Bloomington, Ind) were used to aid in reconstructing the bifurcation in 17 patients. In these patients, Wallstents were placed in the IVC and bilateral iliac veins to within 1 cm of the confluence. Effort was made to ensure that the Wallstents did not cross the confluence. The Z-stents were then deployed from the bilateral iliac veins to bridge the confluence. The Z-stents were oversized by 10% to 20% relative to the iliac vein Wallstents to prevent stent embolization. An overview of procedural steps is seen in Fig 5.

Initial successful reconstructions were unilateral in 44 patients. Unilateral stenting was performed preferentially before 2014 because of surgeon preference for staging bilateral stenting procedures. After 2014, indications for unilateral stenting included failed recanalization

from the opposite side at the initial setting, the presence of only unilateral symptoms, or surgeon preference, depending on the difficulty or duration of the procedure. Overall, 20 patients (28%) had unilateral leg symptoms (left in 15, right in 5). Most of the patients with bilateral symptoms were more symptomatic in one leg than in other (left in 24, right in 17, equal in 10).

When stenting was done unilaterally in patients with bilateral symptoms, the intervention was performed in the more symptomatic leg first. Unilaterally stented patients were treated with continuous Wallstents from the IVC extending into the unilateral iliofemoral vein ( $n = 39$ ) or with a Wallstent stack interrupted by a Z-stent to span the iliac confluence ( $n = 5$ ; Fig 6). The larger interstices of the Z-stent allow greater contralateral flow from the opposite limb and simplify potential future contralateral stenting by allowing easier cannulation and stenting. Ten patients with persistent contralateral symptoms were eventually converted from unilateral stents to





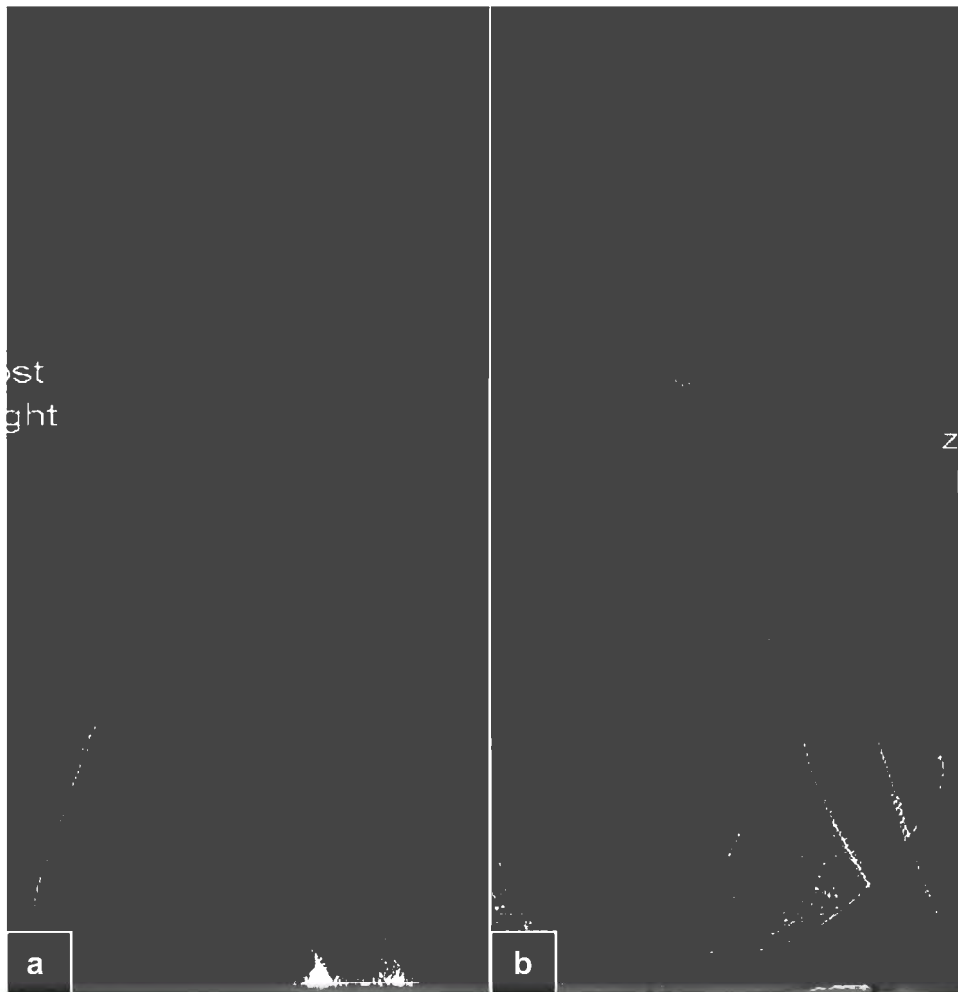
**Fig 5.** Inferior vena cava (IVC) chronic total occlusion (CTO) is confirmed with initial venogram. **a**, An occluded IVC filter (IVCF) is incorporated within the occlusion. **b**, After initial bilateral recanalization, bilateral iliofemoral balloon venoplasty is performed. The incorporated filter is also **(c)** balloon crushed, **(d)** stented across, **(e)** and postdilated. **f**, After remaining stenting is performed, completion venogram shows brisk flow without remaining obstruction.

bilateral stents in a staged fashion with the Wallstent ( $n = 4$ ) or the Gianturco Z-stent- supported Y configurations ( $n = 6$ ). The average time between staging procedures was 9.8 months (range, 1-47 months).

Before 2014, single setting bilateral stents were placed in only five patients for severe bilateral symptoms. One of these patients underwent double-barrel reconstruction and four underwent Y fenestration of the contralateral stent using Wallstents. Since 2014, patients with bilateral symptoms have been treated preferentially in

a single setting. In these cases, Gianturco Z-stents were used to reconstruct the bifurcation ( $n = 11$ ; Fig 7).

**Postoperative care and follow-up.** Patients were prescribed full anticoagulation and antiplatelet therapy postoperatively. Antiplatelet therapy was continued for life. Lifelong anticoagulation was used in patients with unprovoked deep vein thrombosis (DVT), recurrent DVT, diagnosed thrombophilia, or suprarenal stents, with 51 of the 60 patients (85%) meeting at least one criteria for lifelong anticoagulation. A few patients (9 of 60)



**Fig 6.** Unilateral stent configurations were in the form of **(a)** a continuous wall stack from the distal to proximal landing zone or **(b)** as a wall stent stack interrupted at the bifurcation by a Gianturco Z-stent (Cook Medical Inc, Bloomington, Ind) to promote contralateral flow and potential future contralateral stenting.

with provoked DVT and no thrombophilia were treated with only 6 months of anticoagulation. Compression stockings were recommended in all patients, although nearly 50% (28 [47%]) abandoned their use.

Clinical examination and duplex ultrasound were performed at 1, 3, 6, and 12 months and then annually. At each visit, pain and swelling were rated against the preoperative assessment, and VCSS scores were calculated. Ulcers were monitored for healing (100% epithelialization) and recurrence. Transfemoral venography was reserved for patients undergoing reintervention for symptom recurrence as part of the work-up for operative planning or intraoperatively.

Reintervention was performed for symptom recurrence (pain, swelling, ulcer) with evidence of stent malfunction on duplex or venography. Type and frequency of reinterventions were noted.


**Statistics.** Continuous variables were analyzed with the Student *t*-test, and the Fisher exact test was used for categorical data. The Mann-Whitney test for nonparametric

data was used to compare pre-VCSS and post-VCSS scores. A *P* value of  $<.05$  was considered significant. Patency rates and clinical outcomes were calculated using survival analysis with Kaplan-Meier survival curve method. The log-rank test was used to compare curves.

## RESULTS

Demographics are presented in Table 1. There was a male predominance of patients (ratio 2:1). Mean age was  $51 \pm 13.8$  years (range, 23-77 years). All patients, with one exception, were clinical CEAP grade  $\geq 3$  despite anticoagulation and use of compression. The exception was a CEAP 2 patient presenting with multiple life-threatening bleeding episodes from large scrotal varices secondary to occluded IVC and iliac veins. Four patients had pronounced abdominal wall varices, but all were clinical CEAP  $\geq 3$  as well. Mean and median VCSS scores preoperatively were  $8.38 \pm 5.1$  (range, 4-27) and 6, respectively.

Contributing factors for caval occlusion were identified in most patients. A thrombophilia was diagnosed in 27 patients. More than one thrombophilia was discovered



**Fig 7.** Bilateral stent configurations were (a) bilateral Wallstents (Boston Scientific, Marlborough, Mass) in a double barrel, (b) bilateral Wallstents via creation of a Y fenestration, (c) Y fenestration of the ipsilateral Wallstent stack by a contralateral Z-stent, or (d) Wallstent stacks interrupted at the bifurcation by two Gianturco Z-stents (Cook Medical Inc, Bloomington, Ind) to recreate a bifurcation.

during work-up in eight patients. Distribution of hypercoagulable disorders is reported in Table II. More than half of the patients had long-term indwelling IVCFs, and four had surgical clipping or ligation of the IVC. Other factors that likely contributed to the initial DVT included recent surgery in 16 (23%), trauma in 8 (11%), paraplegia in 6 (9%), cancer in 4 (6%), and pregnancy/oral contraceptive use in 2 (3%). Five patients with a known clotting disorder were on anticoagulation for DVT and developed caval occlusion when anticoagulation was stopped secondary to a major gastrointestinal bleed ( $n = 3$ ), trauma ( $n = 1$ ), or head bleed ( $n = 1$ ). A distinct contributing event was not identified in 17 patients (24%).

All patients were classified as type IV according to the anatomic venous classification scheme, with multilevel segmental or continuous occlusion.<sup>6</sup> Mean occlusion duration was  $97 \pm 110$  months (range, 2-468 months) with 19 patients (27%) having occlusions older than 10 years. Median duration of occlusion was 48 months.

Successful recanalization was achieved in 85% (60 of 71) of patients, with 77% (55 of 71) recanalized during the initial attempt. A second attempt was offered to all 16 initial failures, and 11 patients chose to proceed at an average of 41 days (range, 14-62 days) after the initial surgery. Five of 11 additional patients (45%) were opened during the second attempt. There was no difference in the mean duration of occlusion between successful and unsuccessful recanalizations ( $P = .26$ ).

Thirty-eight patients had an occluded IVCF. Filter types were identified in 34 patients (Table III). Recanalization

with balloon crushing and stenting of the filters was possible in 33 patients. All filter types have been amendable to balloon crushing and stenting (Fig 8), with the exception of the Mobin-Uddin umbrella filter. Failure to crush this filter has been previously described, and these patients were not included in this series.<sup>1</sup> Mean duration of occlusion for IVCF patients was  $43 \pm 53$  months (range, 2-240 months) compared with  $147 \pm 127$  months (range, 3-468 months) in nonfilter patients ( $P < .002$ ). Despite the difference in length of occlusion time, there was no difference in recanalization success between patients with or without IVC filters, with five failures in the filter group (13%) and six in the nonfilter group (18%;  $P = .57$ ). Overall, failures in both groups were the result of generalized failure to cross the occluded venous segments. No failures in the filter group were specifically related to difficulty traversing the filter.

Four patients had surgically ligated ( $n = 2$ ) or clipped ( $n = 2$ ) IVCs. Successful recanalization was possible in both patients with IVC clips. Both clips appeared to be the Adams DeWeese variety according to preoperative cross-sectional imaging with computed tomography venography.<sup>7</sup> We were able to successfully recanalize only one of the two patients that had undergone surgical ligation of the IVC. In the remaining patient, we were unable to cross the occlusion.

The 11 failures, including the one mentioned above after IVC ligation, were attributed to failure to cross the occlusions. The average duration of occlusion was  $92 \pm 106$  months in patients in whom recanalization was

**Table I.** Patient characteristics

Demographics	Patients (N = 71)
Age, mean $\pm$ SD (range), years	51 $\pm$ 13.8 (23-79)
Male, No. (%)	41 (58)
CEAP classification, No. (%)	
C <sub>2</sub> (pain)	1 (2)
C <sub>3</sub>	40 (56)
C <sub>4</sub>	8 (11)
C <sub>5</sub>	4 (6)
C <sub>6</sub>	
VCSS score, mean $\pm$ SD (range)	8.4 $\pm$ 5.1 (4-27)
Accessory factors for IVC occlusion, No. (%)	
IVC surgical interruption	4 (6)
IVCF occlusion	38 (54)
Hypercoagulable disorder	27 (38)
Recent surgery	16 (23)
Trauma	8 (11)
Paraplegia	6 (9)
Cancer	4 (6)
Pregnancy/oral contraceptive use	2 (3)
DVT off anticoagulation	5 (7)
Duration of occlusion, mean $\pm$ SD, months	97 $\pm$ 110
Unknown	16 (22)
<1 year	9 (13)
1-5 years	22 (31)
5-10 years	5 (7)
>10 years	19 (27)

DVT, Deep vein thrombosis; IVC, inferior vena cava; IVCF, inferior vena cava filter; SD, standard deviation; VCSS, Venous Clinical Severity Score.

successful vs  $142 \pm 145$  months in patients in whom recanalization failed ( $P = .26$ ). There were no intraoperative complications, perioperative pulmonary emboli, or deaths. There were two postoperative access site hematomas. Both patients required transfusion. One hematoma was related to venous bleeding and subsequently resolved. The second patient had an arterial pseudoaneurysm and underwent thrombin injection with an uncomplicated recovery thereafter. Both patients were

**Table II.** Hypercoagulable type

Hypercoagulability disorder	Patients with disorder (N = 27), No. (%)
Protein C deficiency	3 (11)
Protein S deficiency	7 (26)
Antithrombin III deficiency	1 (4)
Lupus anticoagulant	6 (22)
Anti-cardiolipin antibody	3 (11)
Prothrombin gene deficiency	2 (7)
Factor V Leiden	4 (15)
Elevated factor XI activity	1 (4)
Homocysteinemia	9 (33)

**Table III.** Type of occluded inferior vena cava (IVC) filters (IVCF) in patients with chronically occluded IVCF and IVC-iliofemoral veins

IVCF type	Patients <sup>a</sup> (N = 38), No. (%)
Greenfield (Boston Scientific, Marlborough, Mass)	11 (29)
Vena Tech (B. Braun, Bethlehem, Pa)	2 (5)
Birds Nest (Cook Medical, Bloomington, Ind)	1 (3)
Trapese (Cordis, Miami Lakes, Fla)	5 (13)
Optease (Cordis)	4 (11)
Simon Nitinol (Bard PV, Tempe, Ariz)	2 (5)
Recovery G2 (Bard PV)	9 (24)
Günther Tulip (Cook Medical Inc)	1 (3)
Unknown	4 (11)


<sup>a</sup>Thirty-nine filters are accounted for because one patient had two occluded in his IVC, one Greenfield and one Simon Nitinol.

discharged on postoperative day 3. There was also one patient with acute renal failure secondary to diabetic and contrast nephropathy. She was discharged home on postoperative day 5 with recovered renal function. With the exception of the patients mentioned, all remaining patients were discharged on postoperative day 1.

Follow-up was available for 60 patients (85%). Mean follow-up was  $48 \pm 43$  months (range, 6-172 months). Primary, primary assisted, secondary, and cumulative patency rates were 52%, 85%, 93%, and 93%, respectively (Fig 9). Cumulative stent patency was similar in patients with and without occluded IVCFs ( $P = .073$ ; Fig 10). Five IVC stent occlusions occurred during follow-up. Three additional patients presented with isolated limb (iliac-femoral) occlusions but a patent IVC stent. Six of eight were successfully reopened with a variety of techniques, including pharmacomechanical thrombectomy, catheter-directed thrombolysis, balloon maceration, and stent extension. Reinterventions are described in Table IV. One patient was lost to follow-up before undergoing any attempts to reopen her stent, and the second patient not reopened is currently scheduled for recanalization. One patient reoccluded 6 months later for a third time and decided not to undergo a reintervention because her ulcer remained healed and her symptoms were minimal. She is being closely monitored. In addition, 21 of the 60 patients underwent reintervention for symptom recurrence. At the time of reintervention, patients were noted to have in-stent restenosis (ISR) with (5 [24%]) or without (16 [76%]) stent compression.

All patients (100%) successfully recanalized reported clinical improvement. Significant improvement in pain and swelling were seen in 91% and 83%. Complete cumulative relief of pain and swelling was 66% and 41%, respectively (Figs 11 and 12). The median VCSS before intervention was 6.0 (interquartile range, 4.5), which





**Fig 8.** All filter types encountered were amendable to balloon crushing and stenting. Filter examples depicted here include the **(a)** Günther Tulip (Cook Medical Inc, Bloomington, Ind), **(b)** Optease (Cordis, Miami Lakes, Fla), **(c)** Greenfield (Boston Scientific, Marlborough, Mass), **(d)** Bard G2 (Bard Peripheral Vascular, Tempe, Ariz), and **(e)** Simon Nitinol (Bard Peripheral Vascular).

improved to a median of 3.0 (interquartile range, 3.75) postoperatively ( $P < .0001$ ). In patients with ulcers that healed before reintervention, there were no recurrences. Active ulcers healed in 17 of 18 patients (94%). Three patients had ulcer recurrences. Relief from ulcers is demonstrated in Fig 13.

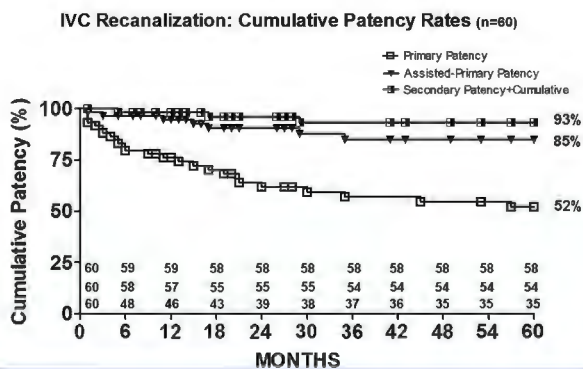
**DISCUSSION**

Endovascular intervention is now considered the first-line therapy for stenotic or occluded iliofemoral veins with low morbidity and high clinical success. Endovascular interventions in the IVC, however, have lagged behind iliofemoral interventions, likely because of a smaller patient cohort and the operative challenges that come with more complex occlusions. Unfortunately, many centers continue to consider this an inoperable disease, and patients are left to manage symptoms inadequately with compression and anticoagulation.

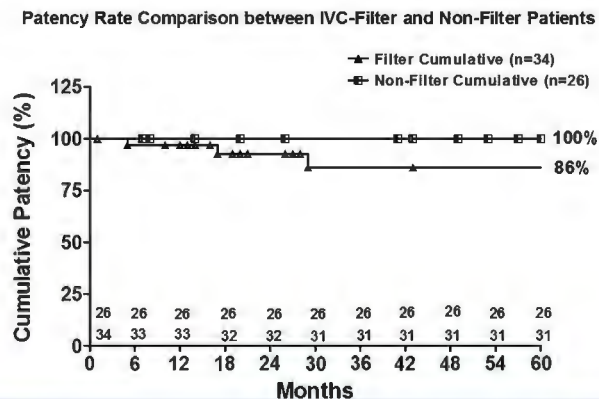
This study illustrates that the vast majority of even the most complicated IVC CTOs can be recanalized; many of these cases can be surprisingly manageable. This is true regardless of venographic appearance. Short-segment

solid components to the occlusion make the entire iliofemoral and IVC segments appear densely occluded. But more often, after crossing short segment occlusions, the remainder of the vein is trabeculated and can be navigated without difficulty. Importantly, the duration of occlusion had no bearing on the likelihood of successful recanalization. Recanalization via trabeculation likely improves with time. In addition, time allows for development and maturation of venous collaterals in the thigh, which may improve stent inflow and the likelihood of long-term stent patency.

Multiple attempts at recanalization may be required for success. Initial success may be hindered simply by entering an incorrect trabecular path, which can be difficult to redirect once sheath placement is established. On future attempts, trabeculae remodeling combined with altered pathway navigation may allow



**Fig 9.** Cumulative stent patency in 60 patients at 60 months follow-up. Separate cumulative curves are shown for primary, assisted primary and secondary patency.



**Fig 10.** Cumulative stent patency comparison of the 34 patients possessing inferior vena cava filters (IVCF) and the 26 patients lacking IVCF at the time of their recanalization. Statistical analysis, through the use of a log-rank (Mantel-Cox) test, revealed a  $P$  value of .073. Therefore, patients with and without filters exhibited similar cumulative patency when receiving a recanalization procedure.

**Table IV.** Patient stent outcomes and reinterventions

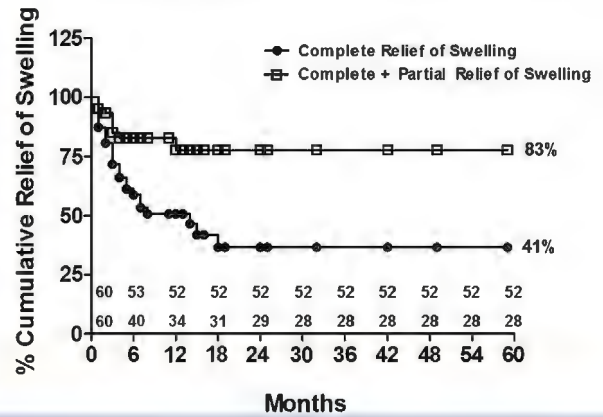
Outcomes and reinterventions	Patients (N = 60), No. (%)
Stent occlusion	8 (13)
Early (<30 days)	
Entire stent	1 (2)
Limb only	2 (3)
Late (>30 days)	
Entire stent	4 (7)
Limb only	1 (2)
Interventions for occlusion	6 (10)
PMT/CDT/dilation	3 (5)
CDT/dilation	1 (2)
Dilation/stent extension	1 (2)
CDT	1 (2)
No intervention	2 (3)
Overall reopened <sup>a</sup>	6 (10)
Stent compression/in-stent restenosis	21 (35)
Early (<30 days)	2 (3)
Late (>30 days)	19 (32)
Interventions for ISR/compression	21 (35)
Dilation/stent extension	18 (30)
Dilation and stent	3 (5)

*CDT, Catheter-directed thrombolysis; ISR, in-stent restenosis; PMT, pharmacomechanical thrombolysis.*  
<sup>a</sup>6 of 8 were opened for a rate of 75%.

passage with ease. For this reason, we offer patients a minimum of two attempts before giving up. In this series, five patients were successfully recanalized on a second attempt after an initial failure to cross the IVC CTO.

If additional attempts from the femoral access fail, we have tried popliteal access with success, and on rare occasions, have attempted internal jugular access. Although other authors have reported success with the

**Swelling Relief After IVC Recanalization (n=60)**

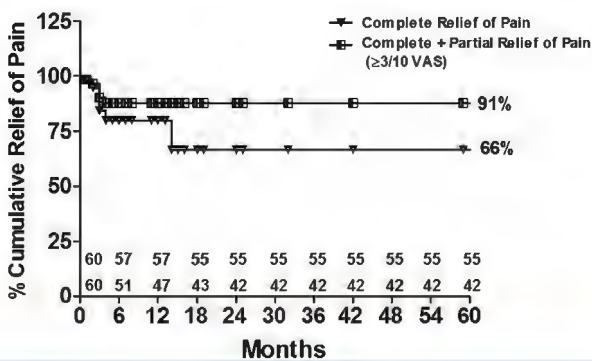


**Fig 12.** Cumulative rate of swelling relief after stent placement in 60 patients complaining of swelling before treatment. Curves representing limbs with complete relief (no residual swelling) and substantial improvement are given. IVC, Inferior vena cava.

internal jugular approach to chronic occlusions, we generally reserve this as a backup option because of the difficulty in system support with the additional travel distance required to get to the level of the occlusion.

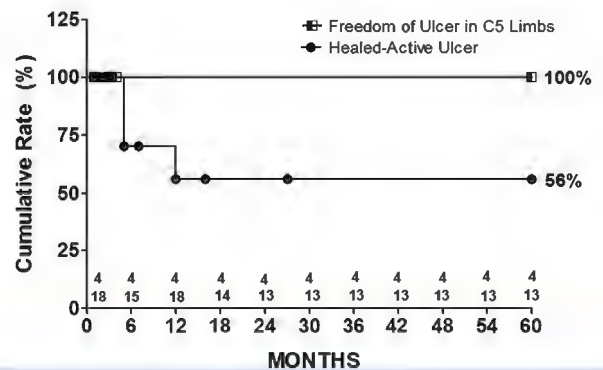
Importantly, it may be possible to recanalize one iliofemoral vein and the IVC but not the contralateral iliac vein. In these patients, a staged approach with unilateral stenting at the index procedure is acceptable. Some of these patients have improvement in symptoms even on the untreated side related to improved collateral flow. However, if contralateral symptoms persist, successful recanalization may be possible on a second or third attempt. At this point, a Y fenestration can re-establish flow. Early in the study, Y fenestrations were performed

**Pain Relief After IVC Recanalization (n=60)**



**Fig 11.** Cumulative rate of pain relief after stent placement in 60 patients complaining of pain before treatment. Curves representing limbs with complete relief (no residual pain) and limbs with substantial improvement are given. IVC, Inferior vena cava; VAS, visual analog scale.

**IVC Recanalization Ulcer Patients (n=22)**



**Fig 13.** Rates of ulcer-free C<sub>5</sub> limbs (ie, limbs with healed ulcers at the time of stenting, n = 4), and healed ulcers in C<sub>6</sub> limbs (limbs with active ulcer at the time of stenting, n = 18). A grace period of 4 months for initial healing of limbs with active leg ulcer was allowed, at which time limbs with unhealed ulcers were censored. This explains the drop of the curve at 4 months. IVC, Inferior vena cava.

with Wallstents. Over time, a high incidence of fenestral stenosis led to a change in technique, and now Z-stents are used to support fenestrations. In this series, there were six failures to open the contralateral limb that were successful on a second attempt on a different date.

A few other important points in technique require comment. Use of large high-pressure noncompliant balloons is necessary to disrupt intraluminal scarring as well as perivenous fibrosis. The use of 18- to 20-mm diameter balloons at inflation pressures up to 16 to 18 atmospheres is well tolerated in the iliofemoral system. We have experienced no venous ruptures with this technique to date. Conversely, the fibrotic and noncompliant nature of some chronic venous lesions can occasionally result in balloon rupture.

IVUS imaging must be used to establish adequate landing zones. Poor inflow and outflow created by underestimating the length of stent needed is the most common cause of stent malfunction.<sup>4,8</sup> There were no consequences of extending stents cranial to the renal veins, hepatic veins, or caudal to the inguinal ligament in this series or those prior.<sup>4,8</sup> However, over time, Wallstents may act akin to covered stents as they become lined with neointima, leading to occlusion of branches dependent on flow through the Wallstent. This situation may be particularly impactful at large venous confluences (ie, contralateral iliac vein and renal veins). For this reason, later in the series, we transitioned to using Gianturco Z-stents with much larger interstices across the junctions. Large stents that parallel the size of normal veins must be used to prevent permanent obstructive symptoms from iatrogenic stenosis caused by small-caliber stents, which is often exacerbated by ISR. Recommended stent sizes are 16 to 20 mm in the iliofemoral veins and 20 to 24 mm in the IVC.

Filter occlusions were the most frequent cause of caval occlusion before stenting. All filters encountered were amendable to crushing and stenting. Although we have used Wallstents and Z-stents to exclude the crushed IVCFs, we generally use the Wallstent because this stent has proven safety and efficacy over a longer period of time. IVCFs have weak radial tension, and residual stenosis or restenosis at the location of the filter is uncommon. We have not attempted to remove the filters from the occluded cava. Historically, the only filter that has been resistant to crushing is the Mobin-Uddin umbrella filter.<sup>1</sup> We do not have a safe endovascular option for patients who occlude this filter type.

Interestingly, more than one-half of the IVCF occlusions have been since 2012 (21 [55%]) and one-third since 2014 (12 [32%]), reflecting a yearly increase in referred filter occlusions. Whether this is reflective of increased referral patterns, the increased use of filters, or a consequence of the duration of indwelling filters is unclear. However, with the vast increase in filters placed in the recent past without a parallel increase in

retrievals, it is likely more of these patients will present in need of treatment.

IVC ligation or clipping was a less common cause of caval occlusion leading to intervention. Nonetheless, it is important to mention that we do not consider this a contraindication to attempted endovascular revascularization. Both patients with clips appeared to have the Adams-DeWeese type as identified by cross-sectional preoperative imaging.<sup>4</sup> These were constructed in such a way that they were held together by a single suture. The suture technique used for caval ligation in the remaining two patients was unknown because the operations were remote and operative reports were not available. However, traditional ligation, described by Ochsner,<sup>9</sup> was performed with umbilical tape because of the higher likelihood of spontaneous recanalization with simple suture. Because both ligations were remote, it is likely that this was the technique used. In general, in the case of surgically interrupted IVCs, if we were able to cross the ligated (1 of 2 [50%]) or clipped (2 of 2 [100%]) portion of the IVC, then we were able to successfully balloon dilate these segments with the aid of Atlas (Bard Peripheral Vascular, Inc, Tempe, Ariz) high-pressure noncompliant balloons (18 mm to pressures of 16 atm), essentially breaking the sutures/clips open. These have been surprisingly easy to break. Fortunately, we have not had any resultant caval disruptions. This may be secondary to the dense fibrotic reaction and scarring associated with caval occlusion, which is likely protective against rupture with hemorrhage. Albeit, our experience is limited, and we have only included four patients in this series.

The risk of intervention in patients with IVC CTO is extremely small, and the benefits of success are dramatic. In this series, postoperative morbidity was minimal and there were no deaths. Symptom relief for most patients was immediate and profound, with 91% reporting improvement in pain and 83% in swelling.

Cumulative patency in this series was excellent and even higher than that obtained in prior reports consisting of mostly limb recanalizations. In prior series, cumulative secondary patency after recanalization was only in the 65% to 80% range.<sup>4,8</sup> Patency in this series was also significantly better than in our prior report, which included 23 patients stented across IVCFs and 92 patients stented without filters, with resultant cumulative primary and secondary patency in these patients of 30% and 35% and 71% and 73%, respectively.<sup>4</sup> However, this study did echo the similarity of results between patients with and without IVCFs.<sup>4,7</sup> Overall, there was no difference in technical success or cumulative patency among these subgroups. Further, there have been no reinterventions or complications related to filter crushing in our experience or others like it,<sup>10</sup> despite a theoretical risk.

When reinterventions were required, investigation universally revealed diffuse ISR. ISR is a common

problem in venous stents and was the primary cause of symptom recurrence and reintervention in the one-third of patients in this series who required a second intervention. ISR has been extensively studied and dealt with in the coronary territory with the development of drug-eluting stents (DES), polymer-free DES, and now even scaffold-free DES. In the peripheral arterial realm, DES and drug-eluting balloons are now being used in vessels up to 7 mm in size (tibial and superficial femoral arteries) to prevent ISR. Unfortunately, this technology has not yet progressed into the venous realm. Further, we have yet to establish whether the pathology is truly the same as arterial ISR and whether there would be benefit from these technologies. Nonetheless, we are currently left with anticoagulation and stent dilation as our best tools for management. This is an area that requires further investigation.

Stent compression was observed less often than ISR. Nonetheless, compression is a universal phenomenon in double-barrel stenting, and thus, this technique has been abandoned in our practice. Compression in most of the remaining patients was mostly seen at anatomic choke points, namely at the inguinal ligament, iliac confluence, near the renal veins, and at the diaphragm crossing into the thoracic vena cava. Importantly, stent compression was not seen at the site of crushed IVCs in any patients. Fenestral stenosis was common in patients with Y configurations created with bilateral Wallstents. Thus after 2012, fenestrums were supported with Z-stents, which appears to reduce the severity but not completely eliminate this phenomenon. In addition, a stenosis often develops below the fenestrum on the side of the fenestrated stent. This is attributable to stretching of the Wallstent at the location of the fenestrum, which results in a compensatory collapse of the immediately distal wall stent. To avoid the difficulties with fenestrations, we now routinely attempt reconstruction with Z-stents at the confluence. This technique results in the least recurrent stenosis and most anatomically accurate bifurcation. Thus far we have had no untoward effects of using Z-stents. Reports using Z-stents for superior vena cava CTO demonstrated patency of 75% at 20 months.<sup>11</sup>

## CONCLUSIONS

IVC CTO can be extremely debilitating. Endovascular management can be performed with minimal morbidity

## DISCUSSION

**Dr Marc Passman** (*Birmingham, Ala*). While the role of endovenous reconstruction for iliofemoral venous occlusion has been expanding in recent years, evidence extending these techniques to inferior vena cava occlusion has been limited. As an update of their previously

and mortality. When successful, symptoms can be universally improved with excellent patency rates. Intervention should be considered when symptoms are not controlled with medical management.

## AUTHOR CONTRIBUTIONS

Conception and design: EM, SR  
Analysis and interpretation: EM  
Data collection: EM, BJ, EV  
Writing the article: EM  
Critical revision of the article: EM, SR  
Final approval of the article: EM, BJ, EV, SR  
Statistical analysis: EM, BJ  
Obtained funding: Not applicable  
Overall responsibility: EM

## REFERENCES

- Garg N, Glociczki P, Karimi K, Duncan A, Bjarnason H, Kalra M, et al. Factors affecting outcome of open and hybrid reconstructions for nonmalignant obstruction of iliofemoral veins and IVC. *J Vasc Surg* 2011;53:383-93.
- Raju S, Davis M. Anomalous features of iliac vein stenosis that affect diagnosis and treatment. *J Vasc Surg Venous Lymphat Disord* 2014;2:260-7.
- Neglen P, Oglesbee M, Olivier J, Raju S. Stenting of chronically obstructed IVC filters. *J Vasc Surg* 2011;54:153-61.
- Raju S, Neglen P. Percutaneous recanalization of total occlusions of the iliac vein. *J Vasc Surg* 2009;50:360-8.
- Raju S, McAllister S, Neglen P. Recanalization of totally occluded iliac and adjacent venous segments. *J Vasc Surg* 2002;36:903-11.
- Crowner J, Marston W, Almeida J, McLafferty R, Passman M. Classification of anatomic involvement of the ilio caval venous outflow tract and its relationship to outcomes after ilio caval stenting. *J Vasc Surg Venous Lymphat Disord* 2014;2: 241-5.
- Adams JT, DeWeede JA. Creation of the Adams-DeWeese inferior vena cava clip. *J Vasc Surg* 2011;53:1745-7.
- Neglen P, Tackett TP, Raju S. Venous stenting across the inguinal ligament. *J Vasc Surg* 2008;48:1255-61.
- Ochsner A. Indication for and results of inferior vena caval ligation for thromboembolic disease. *Postgrad Med* 1960;27: 193-6.
- Williams DM. Iliocaval reconstruction in chronic deep vein thrombosis. *Tech Vasc Interv Radiol* 2014;17:109-13.
- Gaines PA, Belli AM, Anderson PB, McBride K, Hemingway AP. Superior vena caval obstruction managed by the Gianturco Z stent. *Clin Radiol* 1994;49:202-6.

Submitted Mar 24, 2016; accepted Jul 13, 2016.



published experience from 2009, the authors retrospectively review their now 15-year experience in 71 patients requiring stent reconstruction of totally occluded inferior vena cava and in general report continued reasonable efficacy in this subpopulation. A few questions:



First, current evidence-based guidelines support use of iliofemoral stents in patients with active venous ulcers (CEAP C<sub>6</sub>), healed venous ulcers (CEAP C<sub>5</sub>), and advanced venous skin changes (CEAP C<sub>4b</sub>) disease. Yet, this only represented 42% of your population. Why were these complex endovenous reconstructions extended to patients with just leg swelling (CEAP C<sub>3</sub> or less) accounting for 58% of your study population? While upcoming trials like Chronic Venous Thrombosis: Relief with Adjunctive Catheter-Based Therapy (C-TRACT) may help better define threshold for endovenous treatment of post-thrombotic syndrome, what threshold for treatment are you currently using in patients with just leg swelling?

Second, because of the extended time frame for this study, described techniques have evolved. While unilateral stent configurations extending into the iliac system were primarily used, occasional contralateral kissing stents, fenestrated techniques, and later Y configurations using Gianturco Z-stents were sometimes needed. With newer venous stent systems being designed, based on your home-grown experiences, what are your thoughts on venous stent designs systems that could potentially maintain the iliac bifurcation?

Third, with all of the recent attention on inferior vena cava (IVC) filter complications by the Food and Drug Administration in the news and on late night legal TV ads, with 54% of these cases involving an occluded IVC filter, that's a lot of thrombotic endotrash that is being shoved around in the IVC with potential for further penetration of IVC filter components through the IVC wall. How did you adjust your stenting techniques to minimize potential exacerbation of IVC filter issues? What do you tell patients?

Lastly, your regular follow-up included clinical evaluation and venous duplex ultrasound, but you only reserved venography if the patient had clinically recurrent symptoms. Understanding that visualization of the IVC and iliac veins by transabdominal ultrasound can be difficult, what specific ultrasound criteria do you use for surveillance? Given the low yield of positive venous ultrasound findings that drive further reintervention, is surveillance with venous ultrasound really needed?

Again, I would like to thank the society for the privilege of discussing this paper and congratulate the authors for their work.

**Dr Erin H. Murphy.** Thank you for taking the time to review our manuscript and for your thoughtful comments. Currently, the treatment of CEAP 4, CEAP 5, and CEAP 6 patients is encouraged in the literature. In regards to the treatment of CEAP 3 patients, I would clarify that we treat CEAP 3 patients with debilitating

swelling and painful lifestyle-limiting edema not controlled with medical management including routine compression therapy. Restricting treatment of this subset of CEAP 3 patients with pain and lifestyle limitations, would equate in my mind, to withholding intervention for patients with severe lifestyle-limiting arterial claudication. We do not offer or encourage complex endovenous treatment for otherwise asymptomatic patients with mild edema. We also do not generally extend complicated endovenous stenting to CEAP 2 patients. There was one exception in this study, which was a patient with multiple episodes of life-threatening hemorrhage from recurrent extensive scrotal varices.

The evolution of stent technique has taken place in attempt to more thoughtfully manage the iliac bifurcation. Unfortunately, current technology does not provide a precise means of managing the confluence. The double-barrel technique is suboptimal, most often resulting in bilateral stent compression. Y fenestrations, particularly those supported by a Z-stent, appear to have more durable results, but patients almost universally get some degree of fenestral stenosis as well as contralateral limb stenosis below the fenestrum. Reconstruction of the bifurcation with Z-stents appears to be the most viable reconstruction at this time. With new stent technology, I think the ability of these stents to manage the bifurcation with reduced metal load and improved precision will be a key component to device market appeal and overall success.

When considering IVC filter crushing, we generally crush the filters towards the posterior right side of the cava away from the aorta and duodenum. We know that most of the filter tine penetrations are asymptomatic, and there is minimal risk for important structure perforation in this plane. Thus far, we have had no complications related to crushing indwelling filters. Nonetheless, I do counsel patients preoperatively that future complications are possible and that addressing these complications could require open surgery since the filters will be jailed in place by the stent.

During follow-up we routinely utilize duplex ultrasound in addition to the clinical history and examination. Fortunately, our laboratory is dedicated to venous ultrasound, and we probably have a higher yield than most centers. While it is true that we only intervene for a change in clinical symptoms, even asymptomatic duplex findings of significant in-stent restenosis or stent collapse provide us with an opportunity to change anticoagulation management or alter the frequency of follow-up. This provides a theoretical benefit as it may lead to a decrease in future stent occlusions by identifying and optimizing patients prior to an event.